

Spontaneous endometriosis in an umbilical skin lesion

P. Chatzikokkinou, J. Thorfinn, I. K. Angelidis, G. Papa, and G. Trevisan

S U M M A R Y

Cutaneous endometriosis of the umbilicus is an unusual condition with unclear pathogenetic mechanisms that might be mistaken for a malignant condition. A 46-year-old woman presented with a cutaneous black mass in the umbilicus. The lesion was removed surgically and histological analyses revealed that it consisted of endometrial tissue. There was no recurrence at 18-month follow-up. Endometriosis of the umbilicus is a rare condition and the pathogenesis is not completely elucidated. According to one theory, intraperitoneal endometrial tissue is translocated during endoscopic surgery or other surgical procedures that involve the umbilicus. However, in this case there was no history of abdominal wall surgery. We conclude that endometriosis is important to consider in cases of unclear skin lesions of the umbilicus, even in cases with no previous abdominal surgery. Moreover, umbilical endometriosis of the skin can have different appearances that resemble malignant tumors, and radical surgery with histology is therefore indicated.

K E Y W O R D S

umbilical endometriosis, macroscopic appearance, pathogenesis, surgical excision, umbilical tumor, Villar's nodule

Introduction

Endometriosis, which is defined as the presence of endometrial tissue (glands and stroma) outside the uterine cavity, affects 5 to 10% of fertile women (1). The most pronounced symptoms are dyspareunia, pelvic pain, and infertility (1, 2). However, an umbilical endometrioma is a rare condition, with an estimated incidence of 0.5 to 1% of all patients with endometrial ectopia (3). The development of umbilical endometriomas can

occur following laparoscopic surgical procedures involving the umbilicus (4, 5). We report on a patient with umbilical endometriosis that occurred spontaneously without any previous abdominal or uterine surgery.

Case report

A nulliparous, 46-year-old woman with normal menses and no history of abdominal surgery presented with an umbilical skin lesion. At initial examination, a black nodule measuring 15 mm

occupied the deeper aspects of the umbilicus. Macroscopically the nodule resembled a pigmented tumor and there was a history of bleeding from the lesion (Fig. 1). Because the patient reported that the

lesion increased in size at regular intervals during menstruation, surgery was temporarily postponed until the end of the menstrual cycle, when the nodule was small. This made a minor excision possible,

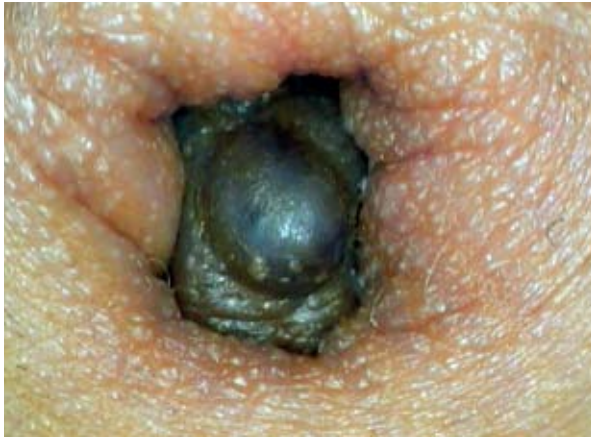

Fig. 1. Umbilical endometriosis that presented as a black nodule and occupied the deep part of the umbilical circumference.

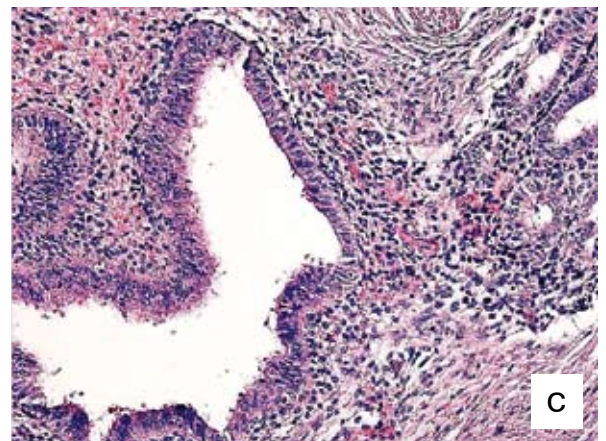
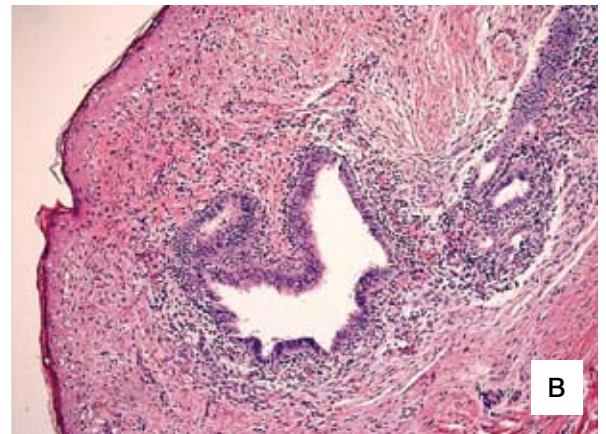
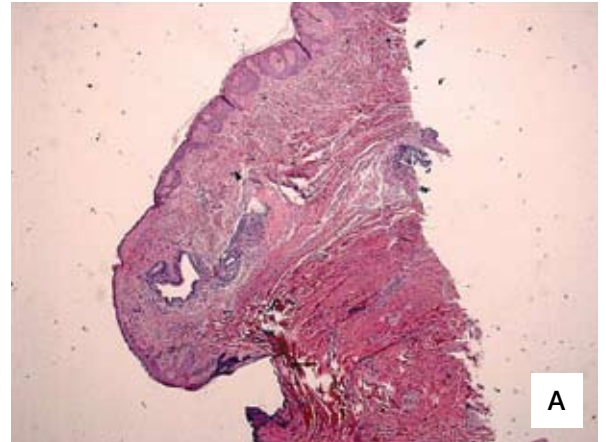


Fig. 2. Histological appearance of the resected tissue. a) several endometrial glandular elements below the epidermis (2.5× magnification, top), b) serous glands located at the dermal papillary reticular junction surrounded by a cytogenetic stroma (10× magnification, middle), and c) glandular cells of endometrial origin of which some are in a mitotic phase (20× magnification, bottom).

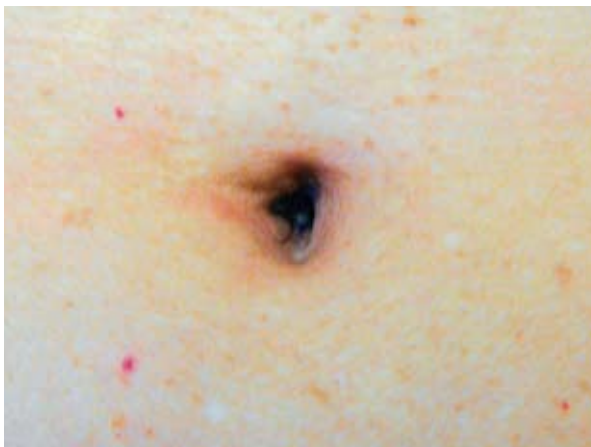


Fig. 3. Postoperative result at 18-month follow-up. The scar is minimal.

which in turn made reconstruction of the umbilicus easier. A narrow, diamond-shaped excision was made with advancement of the skin margins to re-shape the umbilicus, and the wound was closed with a direct suture. The routine histological examination revealed that the lesion consisted of ectopic endometrial glands with surrounding cellular stroma that was occasionally associated with extravasation of erythrocytes in the stroma, as well as some acute inflammatory infiltrates around the glands (Fig. 2). To ensure that no other extrauterine endometrial tissue was present, the patient later had a transvaginal ultrasound exam. The wound healed with an acceptable postoperative result, and there was no recurrence at 18-month follow up (Fig. 3).

Discussion

Extrapelvic endometriosis can involve almost every organ in the human body with a mean age of presentation of 34 years (6). The first description of an umbilical endometrioma is credited to Villar in 1886 (7), and hence the condition is sometimes referred to as Villar's nodule.

The pathogenesis of endometriosis is not entirely clear. The most widely accepted assumption for the pathogenesis is the "hypothesis of migration." This retrograde menstruation into the abdominal cavity was described by Sampson in 1927, and several clinical observations support this theory (8, 9).

Another plausible alternative implicated in the pathogenesis of peritoneal endometriosis is the transformation from mesothelium to endometrium-like tissue under the influence of regurgitated endometrium (the induction theory). This theory of "coelomic metaplasia" is based on the observation that coelomic epithelium is able to differentiate into both endometrial and peritoneal cells (10).

Alternatively, the differentiation of Mullerian remnants into endometrial tissue has also been suggested to cause endometriosis. The circumstances in which this would occur are not clear (11). Lastly, an impaired immunity response, such as a decrease in natural killer cell activity, is suggested to diminish the clearance of endometrial cells from the peritoneal cavity (12).

For cutaneous endometriosis, the implantation of intra-abdominal endometrial cells most likely occurs through lymphatic or vascular spread, or by dislocating endometrial tissue during surgery, such as laparoscopic procedures (4, 13). These routes explain the occurrence of endometriosis at distant locations (14). In the development of spontaneous umbilical endometriosis, as in the case presented, it

is possible that the umbilicus acts as a physiological scar with a predilection for endometrial tissue (15).

The clinical diagnosis of umbilical endometriosis is sometimes difficult. The nodule in our case was nearly black in color, with clear resemblance to a pigmented tumor. However, its macroscopic appearance seemed to vary. Umbilical endometriosis has been described as flesh colored (16), brownish (17), dark-bluish (18), or simply a subcutaneous mass (7). Size can vary up to several centimeters (7).

Because of the macroscopic variable appearance, these lesions can initially be confused with a malignant tumor such as a melanoma. However, any condition that presents with a subcutaneous mass or discoloration of the umbilical skin, such as a benign nevus, a lipoma, an abscess, a cyst, or a hernia, as well as a metastatic deposit from a systemic malignancy, should be considered (19, 20).

To aid in the diagnosis, the use of epiluminescence microscopy (dermoscopy) can be helpful. De Giorgi et al. concluded that with dermoscopy cutaneous endometriosis exhibited a homogeneous reddish pigmentation that is regularly distributed. In addition, small red globular structures were present within this typical pigmentation. These globular structures were more defined and of a deeper hue (21). Biopsy or magnetic resonance tomography (MRI) are other possible tools for diagnosing cutaneous and subcutaneous endometriosis (3, 16), and Catalina-Fernández et al. presented a case series in which cytological smears showed a high cellularity, containing hemosiderin-laden macrophages and sheets of stromal as well as epithelial cells on a hemorrhagic background (22). Another recent report by Wu et al. has emphasized the usefulness of high-frequency power Doppler for diagnosing pelvic masses such as extrauterine, subcutaneous endometriomas (23).

However, it is generally recommended that umbilical endometriosis be removed surgically (3, 4, 17, 18). Histology will confirm the diagnosis. In our case, the histological examination revealed typical ectopic endometrial tissue similar to that of other cases reported in the literature (24, 25). If the umbilicus must be completely removed to ensure radical excision, there are methods for reconstructing it, usually with satisfactory results (26, 27).

To summarize, umbilical endometriosis is a rare condition, but something to bear in mind in fertile women that present with a lesion of the umbilicus. Complete history, dermoscopy, and occasionally MRI can aid in the diagnosis. However, because of the resemblance to malignant tumors, complete excision and histology is highly recommended to rule out malignancy.

REFERENCES

1. Bulun SE. Endometriosis. *N Engl J Med*. 2009;360:268–79.
2. Giudice LC, Kao LC. Endometriosis. *Lancet*. 2004;364:1789–99.
3. Dessy LA, Buccheri EM, Chiummariello S, Gagliardi DN, Onesti MG. Umbilical endometriosis, our experience. *In Vivo*. 2008;22:811–5.
4. Goldberg JM, Bedaiwy MA. Recurrent umbilical endometriosis after laparoscopic treatment of minimal pelvic endometriosis: a case report. *J Reprod Med*. 2007;52:551–2.
5. Michowitz M, Baratz M, Stavorovsky M. Endometriosis of the umbilicus. *Dermatologica*. 1983;167:326–30.
6. Douglas C, Rotimi O. Extragenital endometriosis – a clinicopathological review of a Glasgow hospital experience with case illustrations. *J Obstet Gynaecol*. 2004;24:804–8.
7. Skidmore RA, Woosley JT, Katz VL. Decidualized umbilical endometriosis. *Int J Gynaecol Obstet*. 1996;52:269–73.
8. Kruitwagen RF, Poels LG, Willemsen WN, de Ronde IJ, Jap PH, Rolland R. Endometrial epithelial cells in peritoneal fluid during the early follicular phase. *Fertil Steril*. 1991;55:297–303.
9. Liu DT, Hitchcock A. Endometriosis: its association with retrograde menstruation, dysmenorrhoea and tubal pathology. *Br J Obstet Gynaecol*. 1986;93:859–62.
10. Matsuura K, Ohtake H, Katabuchi H, Okamura H. Coelomic metaplasia theory of endometriosis: evidence from in vivo studies and an in vitro experimental model. *Gynecol Obstet Invest*. 1999;47(suppl 1):18–22.
11. Steck WD, Helwig EB. Cutaneous endometriosis. *Clin Obstet Gynecol*. 1966;9:373–83.
12. Mathur S, Peress MR, Williamson HO, Youmans CD, Maney SA, Garvin AJ, et al. Autoimmunity to endometrium and ovary in endometriosis. *Clin Exp Immunol*. 1982;50:259–66.
13. Koninckx PR, Donders G, Vandercruys H. Umbilical endometriosis after unprotected removal of uterine pieces through the umbilicus. *J Am Assoc Gynecol Laparosc*. 2000;7:227–32.
14. Ueki M. Histologic study of endometriosis and examination of lymphatic drainage in and from the uterus. *Am J Obstet Gynecol*. 1991;165:201–9.
15. Yu CY, Perez-Reyes M, Brown JJ, Borrello JA. MR appearance of umbilical endometriosis. *J Comput Assist Tomogr*. 1994;18:269–71.
16. Elm MK, Twede JV, Turiansky GW. Primary cutaneous endometriosis of the umbilicus: a case report. *Cutis*. 2008;81:124–6.
17. Calò PG, Piludu M, Catani G, Piga G, Mallocci A, Nicolosi A. Endometriosi ombelicale. Descrizione di un caso clinico [Umbilical endometriosis. A case report]. *Chir Ital*. 2005;57:535–7. Italian.
18. Frischknecht F, Raio L, Fleischmann A, Dreher E, Luscher KP, Mueller MD. Umbilical endometriosis. *Surg Endosc*. 2004;18:347.
19. Adamo V, Di Natale W, Meola C, Gilio M, Cavalli S, Ferrari L, et al. Endometriosis in an episiotomy scar: a case report. *Chir Ital*. 2004;56:735–8.
20. Purvis RS, Tyring SK. Cutaneous and subcutaneous endometriosis. Surgical and hormonal therapy. *J Dermatol Surg Oncol*. 1994;20:693–5.
21. De Giorgi V, Massi D, Mannone F, Stante M, Carli P. Cutaneous endometriosis: non-invasive analysis by epiluminescence microscopy. *Clin Exp Dermatol*. 2003;28:315–7.
22. Catalina-Fernández I, López-Presa D, Sáenz-Santamaria J. Fine needle aspiration cytology in cutaneous and subcutaneous endometriosis. *Acta Cytol*. 2007;51:380–4.
23. Wu YC, Tsui KH, Hung JH, Yuan CC, Ng HT. High-frequency power Doppler angiographic appearance and microvascular flow velocity in recurrent scar endometriosis. *Ultrasound Obstet Gynecol*. 2003;21:96–7.

24. Hussain M, Noorani K. Primary umbilical endometriosis – a rare variant of cutaneous endometriosis. *J Coll Physicians Surg Pak.* 2003;13:164–5.
25. Khoo JJ. Scar endometriosis presenting as an acute abdomen: a case report. *Aust N Z J Obstet Gynaecol.* 2003;43:164–5.
26. Malic CC, Spyrou GE, Hough M, Fourie L. Patient satisfaction with two different methods of umbilicoplasty. *Plast Reconstr Surg.* 2007;119:357–61.
27. Pfulg M, Van de Sijpe K, Blondeel P. A simple new technique for neo-umbilicoplasty. *Br J Plast Surg.* 2005;58:688–91.

**A U T H O R S’
A D D R E S S E S**

Paraskevi Chatzikokkinou, MD, Department of Dermatology and Venereology, University of Trieste, Ospedale Maggiore, Via Stuparich 1, I-34100 Trieste, Italy, E-mail: vi80vi@hotmail.com

Johan Thorfinn, MD, PhD, Department of Plastic Surgery, Hand Surgery, and Burns, University Hospital, SE-581 85 Linköping, Sweden, corresponding author, Tel.: +46 13 223735, Fax: +46 13 223706, E-mail: johan@thorfinn.se

Ioannis K Angelidis, MD, Division of Plastic & Reconstructive Surgery, Stanford University Medical Center, 770 Welch Road (Suite 400), Palo Alto, CA 94305, USA, E-mail: ianangelidis@hotmail.com

Giovanni Papa, MD, University Department of Plastic and Reconstructive Surgery, University of Trieste, Cattinara Hospital Trieste, Strada di Fiume 447, I-34100 Trieste, Italy, E-mail: giovanni.papa@aots.sanita.fvg.it

Giusto Trevisan, MD, Department of Dermatology and Venereology, University of Trieste, Ospedale Maggiore, Via Stuparich 1, I-34100 Trieste, Italy, E-mail: trevisan@units.it