

Treatment of fungal keratitis by penetrating keratoplasty

Lixin Xie, Xiaoguang Dong, Weiyun Shi

Abstract

Aim—To study the use of penetrating keratoplasty (PKP) for the treatment of severe fungal keratitis that could not be cured by antifungal medication.

Methods—A retrospective analysis of 108 cases of severe fungal keratitis in which PKP was performed served as the basis for this study. Fungal keratitis was diagnosed by KOH staining of corneal scrapings or by confocal microscopic imaging of the cornea. All patients received a combination of topical and oral antifungal medicines without steroids as the first course of therapy. Patients whose corneal infection was not cured or in whom the infection progressed during antifungal treatment were given a PKP. After surgery, the patients continued to receive antifungal therapy with gradual tapering of the dose over a 1–2 month period. Cyclosporine was used to prevent graft rejection beginning 2 weeks after PKP. Topical steroid only was administered to the patient whose donor graft was over 8.5 mm and with a heavy iris inflammation 2 weeks after PKP. The surgical specimens were used for microbiological evaluation and examined histopathologically. The patients were followed for 6–24 months after PKP. Graft rejection, clarity of the graft, visual acuity, and surgical complications were recorded.

Results—Corneal grafts in 86 eyes (79.6%) remained clear during follow up. There was no recurrence of fungal infection and the visual acuity ranged from 40/200 to 20/20. Complications in some patients included recurrent fungal infection in eight eyes (7.4%), corneal graft rejection in 32 eyes (29.6%), secondary glaucoma in two eyes (1.9%), and five eyes (4.6%) developed cataracts. 98 of 108 of the recipient corneas had PAS positive fungal hyphae in tissue sections; 97 of 108 were culture positive for various fungi, including *Fusarium* (63), *Aspergillus* (14), *Candida* (9), *Penicillium* (4), and seven cases in which septate hyphae were seen but identification of the organism was not conclusive.

Conclusions—PKP is an effective treatment for fungal keratitis that does not respond to antifungal medication. Early surgical intervention before the disease becomes advanced is recommended. It is critical that the surgical procedure remove the infected tissue in its entirety in order to effect a cure.

(Br J Ophthalmol 2001;85:1070–1074)

Fungal keratitis is a major blinding eye disease in China.¹ Within the past decade there has been an increase in the frequency of microbial keratitis caused by fungi.¹ A contributing factor for the development of fungal infection is ocular trauma and contamination of corneal lesions by soil and plant material. Another factor which may contribute to the increased incidence of fungal keratitis is the widespread use of broad spectrum antibiotics and steroids. It is also apparent that improved diagnostic methods and instruments have facilitated the process of identifying corneal fungal infections.^{2–3}

Not surprisingly, the majority of cases occur in farmers; the incidence of corneal fungal infection is especially high in rural areas where the climate is warm and humid. Epidemiological studies suggest that many of the patients who develop fungal keratitis live a considerable distance from an ophthalmological clinic. Furthermore, because of the difficulty of accurately diagnosing fungal keratitis, many patients from rural areas had a long duration of disease and severe corneal infection including corneal perforation by the time that they were referred to our hospital. Very little information has been published regarding the treatment of advanced fungal infection of the cornea in such patients and some ophthalmologists only perform penetrating keratoplasty (PKP) as a last resort.^{4,5} In an effort to prevent loss of vision in severe cases of corneal infection which did not respond to fungal chemotherapy we performed 108 corneal transplants between January 1996 and December 1999. The outcome of these cases is presented with an average follow up of 18.3 months.

Patients and methods

Between January 1996 and December 1999, 358 patients with a preliminary diagnosis of fungal keratitis were referred to our hospital. One hundred and eight of these patients (30.2%) required a corneal transplant to save their eyes and cure the disease. Shandong Eye Institute and Hospital is a referral centre for a large rural area and population. All 358 patients were subjected to diagnostic testing including potassium hydroxide (KOH) analysis and culture for fungi. We relied more heavily on the results of the microscopic analysis of KOH treated scrapings because we obtained significantly fewer positive results from the culture. Confocal microscopy was used to support the KOH results. Initial treatment involved antifungal chemotherapy as detailed below. When this treatment failed the patients were recommended for PKP.

Shandong Eye
Institute and Hospital,
Qingdao 266071, PR
China
L Xie
X Dong
W Shi

Correspondence to:
Lixin Xie, MD, Shandong
Eye Institute and Hospital, 5
Yanerdao Road, Qingdao
266071, PR China
lixinxie@public.qd.sd.cn

Accepted for publication
5 March 2001

The decision regarding the appropriate therapy for each patient was based on the following classification system: (1) when the fungal ulcer was eccentric, less than 6 mm in diameter, but had invaded the limbus, we first treated with intensive systemic and topical antifungal agents, and a conjunctival flap or partial lamellar keratoplasty; (2) when the fungal ulcer was less than 6 mm in diameter but had not invaded the limbus, we treated with intensive systemic and topical antifungal drugs. If the infection was not cured and the fungal ulcer increased in size we performed a PKP; (3) when the fungal ulcer was 6–8 mm in diameter and the infection continued to progress during 72 hours of intensive systemic and topical antifungal therapy we performed a PKP; (4) when the corneal ulcer was larger than 8 mm or corneal perforation was imminent or had occurred we performed a PKP. We feel that it is necessary to use a combination of antifungal agents for 3–5 days before PKP, and that fewer surgical complications occur when grafts > 8.5 mm diameter are performed.

DIAGNOSTIC METHODS

In addition to a clinical history, an ocular surface examination with a slit lamp microscope and confocal microscopy or examination of a corneal scraping was used to confirm the diagnosis. Biopsy material obtained by scraping the corneal lesion was placed on microscope slides and incubated with KOH and examined as a wet mount. The presence of fungal filaments in the KOH preparations or the presence of fungal hyphae in the confocal microscope images was considered confirmatory for fungal keratitis.

MEDICAL AND SURGICAL TREATMENT

All 108 patients were hospitalised and received 1% fluconazole (prepared by Shandong Eye Institute and Hospital) combined with 0.25% amphotericin B or 5% natamycin drops every hour, alternating on the half hour. All patients were also treated with oral fluconazole. All patients, except those with corneal perforation, had their cornea scraped and curetted to eliminate the majority of the superficial necrotic tissue. An antifungal ointment was applied to the scraped lesions during sleep. Some patients with hypopyon were given 100 mg fluconazole intravenously twice a day. The duration of topical antifungal treatment ranged from 5 days to 1 month (mean 11 days). When corneal infection was still present or in some cases continued to progress during antifungal therapy PKP was performed. In four patients with corneal perforation an emergency PKP was performed. The patients whose infection resolved with antifungal therapy were not included in this study.

SURGICAL PROCEDURE

In our experience for routine PKP donor tissue should have a diameter of 0.25 mm larger than the diameter of the recipient graft site. In general, if the recipient site is greater than 8 mm, the donor graft should be 0.50 mm larger. In this study 44 of the donor corneas (40.7%) had

a diameter of 7.25–8.00 mm, 28 of the donor corneas (25.9%) had a diameter of 8.50–9.00 mm, and 36 donor corneas (33.3%) had a diameter greater than 9.00 mm, including four cases that required anterior segment reconstructive surgery.

For removal of the diseased cornea, the trephine should be 0.25 mm larger in diameter than the area of infection. After removal of the diseased cornea, the anterior chamber angle and iris surface were carefully irrigated with 0.2% fluconazole and the hypopyon and fibrous membrane was carefully removed. If bleeding occurred, Healon was used to coat the injury and cautery can be used to close ruptured blood vessels if necessary. We did not perform peripheral iridectomies in these patients because in our past experience we have encountered bleeding into the anterior chamber caused by irises with vascularisation and, on occasion, the development of an infiltrative membrane to cover the iridectomy's hole, leading to glaucoma. When necessary, 250 ml of 20% mannitol containing 10 mg of dexamethasone was given intravenously once or twice after PKP to lower intraocular pressure and suppress the development of intraocular inflammation. Thirty patients were treated with this corticosteroid regimen postoperatively in this study.

Corneal grafts were secured in place with 16 interrupted 10–0 nylon sutures. Immediately after surgery 2×10^4 units of gentamicin and 1 mg of fluconazole were injected subconjunctivally. Fluconazole was given orally beginning the day before surgery and for 21 days thereafter. Liver function was monitored by serum liver enzyme analysis. Fluconazole was given subconjunctivally once daily for 3 days after surgery. In addition, fluconazole or amphotericin B ointment was applied to the grafts immediately before sleep. Five days after corneal grafting 1% fluconazole eye drops were used four times daily. All antifungal agents were tapered so that treatment was discontinued between 20 and 30 days after surgery. Atropine ointment was used in all cases with hypopyon. Corticosteroid was not used in the immediate postoperative period unless there was significant inflammation before surgery. Systemic and topical steroids and topical 1% cyclosporine A were given beginning 2 weeks after PKP if the fungal infection did not recur.

The diseased corneal specimens were cut into two equal parts and one part was used for histological analysis following periodic acid Schiff (PAS) staining. The other portion of the cornea was cultured for microbiological evaluation.

Results

PATIENT POPULATION AND RISK FACTORS

Seventy of the 108 patients were male and 38 were female with an age distribution as follows: four patients (3.7%) were less than 20 years old, 52 patients (48.2%) were between 21 and 40 years old, 43 patients (39.8%) were between 41 and 60 years old, and nine patients (8.3%) were older than 60 years. Ninety two patients were farm workers and 16 had other

Table 1 Visual acuity in graft recipients*

	LP-FC	FC-0.04	0.05-0.2	0.3-0.4	>0.5
	No (%)	No (%)	No (%)	No (%)	No (%)
Before PKP	91 (84.3)	17 (15.7)	0 (0)	0 (0)	0 (0)
After PKP	8 (7.4)	24 (22.2)	47 (43.5)	16 (14.8)	12 (12)

*Visual acuity was tested before and after PKP as a measure of visual rehabilitation.

Table 2 Results of surgical treatment of fungal keratitis*

Total number of grafts	Surviving grafts	Graft reactions	Rejected grafts	Recurrent infection	Enucleation	Cataract	Glaucoma
108	86	32	15	8	4	5	2

*The numbers represent the number of patients in whom PKP was performed and a summary of the clinical outcome of these patients.

occupations. The patients arrived at our hospital between 5 and 40 days (average of 21.3 days) after the onset of the infection.

Fifty three of the patients (49.1%) reported a recent history of injury to the cornea and contact with plant material or soil. Nineteen of the patients (17.6%) had been treated with topical steroids before infection and 36 of the patients (33.3%) were unable to provide a cause for their infection.

Fifteen of the eyes (13.9%) had a corneal ulcer less than 6.0 mm in diameter. Thirty nine eyes (36.1%) had ulcers between 6.1 and 8.0 mm in diameter. Fifty four eyes (50%) had ulcers greater than 8.0 mm in diameter. Four of the corneas (3.7%) perforated.

LABORATORY DIAGNOSIS

Seventy eight of the corneal ulcers (72.2%) were found to be positive for fungal hyphae on KOH staining of the corneal scrapings. One hundred and one corneas (93%) had hyphae which could be seen with the confocal microscope. Fungal hyphae were found in 98 (90.7%) of the diseased corneal specimens stained with the PAS stain; 97 of the specimens (89.8%) were culture positive for fungi. Sixty three of the fungi were identified as *Fusarium* sp, 14 were *Aspergillus* sp, nine were *Candida* sp, four were *Penicillium* sp, and in seven specimens septate hyphae which were not identified were seen.

VISUAL REHABILITATION

As an example, Figure 1 is a photograph of the cornea of a 28 year old farm worker who was referred for treatment. The patient recounted that 9 days earlier he felt a foreign body in his eye and that there was a painful, scratchy sensation after removal of the foreign body. Ocular scrapping revealed fungal hyphae which were subsequently identified as *Aspergillus*. The patient was hospitalised and treated with systemic and topical antifungal drugs for 6 days. The treatment failed and the patient underwent PKP. The 14 mm graft, which included donor limbal tissue, performed well for 8 months, at which time an immune graft reaction occurred. This was treated with topical, subconjunctival, and systemic steroids and the graft reaction subsided. The condition of this graft at 9 months after PKP is shown in Figure 2.

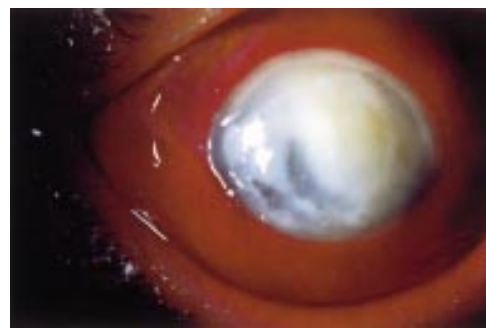

Figure 1 A large corneal ulcer 9 days after injury. The cornea is ulcerated and necrotic. Vision was reduced to light perception.

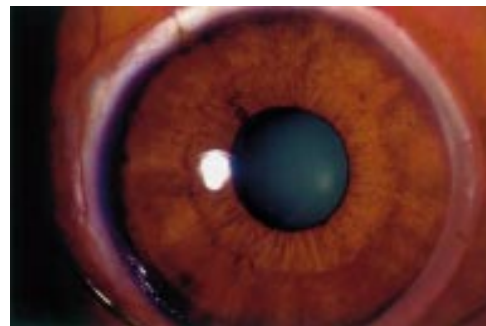


Figure 2 Rehabilitation of vision by PKP. Nine months after PKP the graft which extended into the limbus is clear and the corrected visual acuity is 20/40.

Eighty six of the eyes that received corneal grafts (79.6%) had clear corneas during the 6-24 month follow up period. The visual acuity results are shown in Table 1.

COMPLICATIONS

Recurrent fungal infection occurred in eight (7.4%) eyes after PKP. The recurrent infection typically appeared within 2 weeks of surgery. Three of these recurrent infections were controlled by repeat PKP, two of the grafts remained clear, and one was rejected. Recurrent infection in one patient was controlled by intensive antifungal therapy. Ultimately, four of the eyes were enucleated because of the development of endophthalmitis.

Thirty two of the corneal allografts (29.6%) developed corneal allograft rejection reactions 1-8 months after PKP. Fifteen of these grafts failed. Five (4.6%) of the eyes in which PKP was performed developed cataracts possibly due to the severity of the infection and/or the use of steroids following surgery. Secondary glaucoma was noted in two of the operated eyes (1.9%) and glaucoma surgery was performed 3 days after PKP in one of the eyes. The intraocular pressure was controlled in this eye, although immune graft failure occurred later. In the other patient glaucoma surgery was performed 5 months after PKP and was successful. The results of PKP for fungal keratitis are summarised in Table 2.

Discussion

EPIDEMIOLOGY

Between January 1996 and December 1999, 308 patients diagnosed with infectious keratitis underwent PKP at our hospital. One hundred

and eight of these cases of infectious keratitis (35.1%) were determined to be due to fungal infection. Thus, fungal keratitis is second to herpetic keratitis as an indicator for PKP in our hospital. However, this percentage is higher than other reports from China in the past two decades.⁶⁻⁸ Heightened awareness among ophthalmologists of the threat that fungal keratitis represents to vision together with advances in diagnostic techniques, such as the confocal microscope, may have contributed to the larger number of cases reported by several investigators.^{2 9 10}

Fusarium and *Aspergillus* were the most frequently isolated pathogens in this series of patients. The results of previous studies led other investigators to conclude that a majority of corneal fungal infections result from ocular trauma and contamination of lesions by organic material.^{2 11 12}

Fungal keratitis is relatively rare in most parts of the world and fungal infection of the cornea usually receives medical attention very early in the infectious process. Early treatment is usually adequate to control the infection. Liesegang and Forster¹³ reported results obtained with antifungal medication for fungal keratitis although surgical management of fungal keratitis was not mentioned in this report. Forster and Rebell¹⁴ reported 61 cases of fungal keratitis of which 11 were treated by PKP. Tanure *et al*² performed PKP in six eyes during acute infection when the patients were receiving a combination of natamycin and amphotericin B. The large number of cases of fungal keratitis treated by PKP in our hospital emphasises the problem of this infection in China. Previous studies report rates of 26–35% of cases requiring grafting in acute stage.¹⁴⁻¹⁶ Here we report 108 cases of fungal keratitis treated by PKP and our figure of 35.1% requiring surgery is at the higher end of this range. The results of other studies support the conclusion that patients with fungal keratitis require therapeutic PKP more frequently than those with bacterial ulcers.^{17 18} Problems of drug penetration are thought to contribute to the limited efficacy of medical therapy of fungal keratitis.^{19 20}

The majority of the patients in this study were farm workers. The average time from the onset of the symptoms to referral to our hospital was 21.3 days. Ninety three of the eyes had a corneal ulcer larger than 6.1 mm in diameter. These observations emphasise that it is critical that rural populations be adequately served by eye care physicians and that farm workers be cautioned about the need for protective eyewear and eye care following injury.

Furthermore, the correct treatment and referral by local ophthalmologists to a major eye hospital such as ours is critical. The prescription of topical steroids by the primary care physician or ophthalmologist should be discouraged for the treatment of infections of unknown aetiology.

JUSTIFICATION FOR PERFORMING PKP

The literature does not contain a detailed analysis of the use and justification for

performing PKP in patients who have fungal keratitis. Sanders¹⁶ reported three cases in which surgery was performed early after diagnosis. It was concluded that performing surgery early was preferable to delaying until after antifungal therapy failed. In 10 cases postoperative vision was poor. Two patients also had previous unsuccessful conjunctival flaps.¹⁶ Six eyes had progressed to total corneal involvement before surgery was undertaken; thus a good visual result could not be expected and surgical complications are more likely to occur. It is very important for an ophthalmologist to determine if PKP is the correct approach to insure good visual acuity without resulting in difficult to manage surgical complications.

MODIFICATION OF PKP SURGERY

We feel that it is important to create a graft site which is 0.25–0.5 mm larger than the infected area of the cornea. It is also critical to thoroughly irrigate the anterior chamber with antifungal medication and in this study we found that 0.2% fluconazole was effective and safe. In cases in which corneal perforation and severe hypopyon were seen the hypopyon and any membranes that formed had to be carefully removed and the anterior chamber gently irrigated with fluconazole. Bleeding was controlled by the use of Healon and cautery of vessels. Most importantly, we feel that it is necessary to eliminate the infected corneal tissue in order to control the infection. We found only two cases of recurrent infection in this study which were too large to be eliminated by a corneal graft. Both of these infections were controlled by enucleation because endophthalmitis had developed. For ulcers larger than 8 mm diameter or if the ulcer is near the limbus, it is very important to open the conjunctiva and retract it. This allowed us to determine if the infection had invaded the sclera necessitating additional surgical intervention.

POSTOPERATIVE MANAGEMENT

Recurrent fungal infection can be particularly difficult to treat. Following PKP both systemic and topical antifungal agents must be used. Corticosteroids were not used unless significant inflammation was present.²¹ If by 2 weeks after PKP recurrent fungal infection was not seen systemic antifungal agents were tapered in the following 2 weeks.

CHARACTERISTICS OF THE GRAFTS

In this study 64 of the eyes received a graft larger than 8.5 mm. For 2 weeks after PKP steroids were not used and then if the infection did not recur immunosuppressive therapy was instituted. It is remarkable that 86 grafts were clear during follow up although most of patients with a > 8.5 mm had allograft immune reactions which were successfully treated. Fifteen of these grafts failed in spite of careful surgical procedures and the use of 1% cyclosporine eye drops.^{22 23} Based on these results, PKP is advocated in cases that fail to respond to medical therapy. Early intervention

is recommended particularly since the need for a larger diameter graft may be avoided.²⁴⁻²⁶ Another complication is recurrent infection which was seen in eight of the eyes; three of these were cured by a second PKP. One of the recurrent infections was controlled by antifungal therapy and four eyes were enucleated.

Overall, we feel that early diagnosis and antifungal therapy are critical for controlling fungal keratitis. However, if the infection does not respond to chemotherapy PKP should be considered as an alternative. The results of this study suggest that PKP is an effective method not only to cure fungal keratitis, but also to rehabilitate useful vision if the surgery is performed soon enough to preserve the eye.

- 1 Dong X, Xie L, Shi W, *et al*. Penetrating keratoplasty management of fungal keratitis. *Chin J Ophthalmol* 1999; 35:386-7.
- 2 Tanure MAG, Cohen EJ, Sudesh S, *et al*. Spectrum of fungal keratitis at Wills Eye Hospital, Philadelphia, Pennsylvania. *Cornea* 1999;19:307-12.
- 3 Xie L, Li S, Shi W, *et al*. Clinical diagnosis of fungal keratitis by confocal microscopy. *Chin J Ophthalmol* 1999;35:7-9.
- 4 Foster CS. Fungal keratitis. *Infect Dis N Am* 1992;6:851-7.
- 5 Liesegang TJ. Fungal keratitis. In: Kaufman HE, Barron BA, McDonald MB, eds. *The cornea*. 2nd ed. Boston: Butterworth-Heinemann, 1998:219-46.
- 6 Sun B, Zhu Z, Wang Y, *et al*. Corneal transplantation for infectious corneal ulcer. *Chin J Ophthalmol* 1986;22:85-7.
- 7 Deng X, Lu X, Pang G. Analysis of the cause and pathogenic of the pyogenic corneal ulcer in 312 cases. *Chin Ophthalm Res* 1995;13:110-3.
- 8 Fan D, Cai S. Clinical analysis of 318 cases of fungal keratitis. *Chin J Ophthalmol* 1981;17:321-5.
- 9 Kislá TA, Cu-unjieng A, Sibling L, *et al*. Medical management of Beauveria bassiana keratitis. *Cornea* 2000;19:405-6.
- 10 Wagoner MD, Badr IA, Hidayat AA. Chrysosporium parvum keratomycosis. *Cornea* 1999;18:616-20.
- 11 Smolin G, Thoft RA. *The cornea*. 3rd ed. Boston: Little, Brown, 1994:239-53.
- 12 Xie L, Shi W, Dong X, *et al*. Clinical and histopathologic study on fungal keratitis (108 cases). *Chin Ophthalm Res* 1999;17:283-5.
- 13 Liesegang TJ, Forster RK. Spectrum of microbial keratitis in south Florida. *Am J Ophthalmol* 1980;38:90-3.
- 14 Forster RK, Rebell G. The diagnosis and management of keratomycosis. II. Medical and surgical management. *Arch Ophthalmol* 1975;93:1134-6.
- 15 Kaufman HE, Wood RM. Mycotic keratitis. *Am J Ophthalmol* 1965;59:993-1000.
- 16 Sanders N. Penetrating keratoplasty in treatment of fungus keratitis. *Am J Ophthalmol* 1970;64:24-30.
- 17 Polack FM, Kaufman HE, Newmark E. Keratomycosis medical and surgical treatment. *Arch Ophthalmol* 1971;85:410-6.
- 18 Miediak AI, Miller MR, Rapuano CJ, *et al*. Risk factors for microbial keratitis leading to penetrating keratoplasty. *Ophthalmology* 1999;106:1166-71.
- 19 Jones DB, Forster RK, Rebell G. Fusarium solani keratitis treated with natamycin (pimaricin). *Arch Ophthalmol* 1972; 88:147-54.
- 20 Alfonso FC, Rosa RH. Fungal keratitis. In: Krachmer JH, Mannis HJ, Holland EJ, eds. *Cornea and external diseases: clinical diagnosis and management*. St Louis: CV Mosby, 1997:1253-66.
- 21 Shi W, Xie L, Dong X. Administration of corticosteroid after penetrating keratoplasty in fungal corneal ulcer. *Chin Ophthalm Res* 1998;16:130-2.
- 22 Xie L, Yuan N, Li Q. Penetrating keratoplasty for herpes simplex keratitis. *Chin J Ophthalmol* 1987;2:65-7.
- 23 Xie L, Cao J, Dong X, *et al*. Observation on the effects of combined topical administration of CsA and dexamethasone during immune rejection after penetrating keratoplasty. *Chin Ophthalm Res* 1995;13:24-37.
- 24 Anderson B, Roberts SSJ, Gonzales C, *et al*. Mycotic ulcerative keratitis. *Arch Ophthalmol* 1959;62:169-79.
- 25 Low CDT, Badenoch PR, Coster DJ. Beauveria bassiana keratitis cured by deep lamellar dissection. *Cornea* 1997;16:698-9.
- 26 Jones DB. Decision-making in the management of microbial keratitis. *Ophthalmology* 1981;88:814-20.