

Aspergillus Galactomannan Antigen in the Cerebrospinal Fluid of Bone Marrow Transplant Recipients with Probable Cerebral Aspergillosis

Claudio Viscoli,^{1,2*} Marco Machetti,¹ Paola Gazzola,^{1,3} Andrea De Maria,⁴ Dimitri Paola,⁵ Maria Teresa Van Lint,⁶ Francesca Gualandi,⁶ Mauro Truini,⁷ and Andrea Bacigalupo⁶

Istituto Nazionale per la Ricerca sul Cancro,¹ Dipartimento di Oncologia, Biologia e Genetica,² Dipartimento di Scienze Neurologiche e della Visione,³ Dipartimento di Medicina Interna,⁴ Dipartimento di Medicina Sperimentale,⁵ and Dipartimento Diagnostico di Laboratorio, di Anatomia Patologica e Medico Legale,⁷ Università di Genova, and Ospedale San Martino,⁶ Genoa, Italy

Received 10 May 2001/Returned for modification 26 September 2001/Accepted 23 November 2001

The *Aspergillus* galactomannan test was performed on cerebrospinal fluid and serum samples from 5 patients with probable cerebral aspergillosis and from 16 control patients. Cerebrospinal fluid galactomannan levels were significantly higher in aspergillosis patients, and most galactomannan was produced intrathecally. Comparison of serum galactomannan values in pulmonary and cerebral aspergillosis patients showed significant overlapping. Detection of *Aspergillus* galactomannan in cerebrospinal fluid may be diagnostic of cerebral aspergillosis.

Bone marrow transplant recipients are at high risk of developing *Aspergillus* infection, due to the combined effects of profound and prolonged neutropenia and the use of high-dose steroid therapy for management of graft-versus-host disease.

Although pulmonary infection is the most frequent manifestation of aspergillosis, cerebral disease is not uncommon, being detected in 10 to 20% of all cases of invasive aspergillosis. Most patients die within a few days after diagnosis, with a mortality rate as high as 95% (10). Cerebral involvement can occur even without any pulmonary disease (2). In recent years, a sandwich enzyme-linked immunosorbent assay (ELISA), “Platelia *Aspergillus*” (Bio-Rad Laboratories, Marnes La Coquette, France), for diagnosis of *Aspergillus* infection by the detection of galactomannan (GM) antigens, has aroused interest (7, 9, 12, 13). The sensitivity and specificity of this test are good, and it sometimes gives positive results before the onset of symptoms or radiological abnormalities (9, 11, 13, 17). There is some evidence that the test is reliable even when used on bronchoalveolar lavage or cerebrospinal fluids (CSF) (8, 16, 18). In this study we have investigated the value of the Platelia *Aspergillus* ELISA with CSF specimens for the diagnosis of cerebral aspergillosis. All serum and CSF samples were processed according to the manufacturer’s instructions, and ELISA results were tabulated as the ratio of the optical density of the sample tested to the optical density of the threshold positive control (GM index). All comparisons were performed using the Mann-Whitney U test for unpaired data sets. Data were expressed as box plots indicating median values with interquartile ranges to graphically represent the GM index in patient and control groups (StatView 4.2 program; Abacus Concepts, Berkeley, Calif.).

From 1995 to 2000, at the Bone Marrow Transplant Unit of

the Hematology Department of San Martino General Hospital in Genoa, Italy, five patients with probable aspergillosis, as defined by the EORTC-MSG (European Organization for Research and Treatment of Cancer-Mycoses Study Group) consensus group (1), were observed. For all patients, albumin, immunoglobulin G (IgG), and glucose concentrations were calculated in parallel, in CSF and serum samples. In addition, the IgG index [calculated as (CSF IgG level/serum IgG level)/(CSF albumin level/serum albumin level)] was also determined as an estimate of intrathecal IgG production (15). The main clinical characteristics are shown in Table 1. In computed tomographic scans all patients had hypodense lesions, with ring enhancement. In no case was a cerebral biopsy performed, because of the patients’ underlying conditions and severe thrombocytopenia. All patients died after a median of 40 days after diagnosis. Autopsies were performed for three of five patients and showed diffuse cerebral infiltration with hyaline septate, acute branching hyphae, diagnostic of cerebral mold infection. For these patients, premortem CSF cultures were negative and postmortem cultures were not performed. The two patients who did not undergo autopsy had at least one nasal swab positive for *Aspergillus* spp. within the 30 days preceding the onset of neurological symptoms. The median CSF GM index for the five patients with probable cerebral aspergillosis (eight samples) was 10.52 (mean, 81.931; standard deviation [SD], 200.958; range, 0.549 to 578.5). By contrast, the median CSF GM index from the 16 control patients (33 samples) was 0.287 (mean, 0.281; SD, 0.13; range, 0.09 to 0.749). As shown in Fig. 1, there was no overlap between the two groups of patients.

To rule out the possibility that the presence of GM in CSF was merely due to passive transfer, the percentage of intrathecally produced GM was calculated for each patient. The chemophysical characteristics of the GM molecule have not been completely characterized yet. According to the information available (6), the fraction of GM reacting with the EB-A2 monoclonal antibody used in this test is part of a more complex

* Corresponding author. Mailing address: Istituto Nazionale per la Ricerca sul Cancro, Largo Rosanna Benzi 10, 16132 Genoa, Italy. Phone: 39-010-5600846 or -5600848. Fax: 39-010-5600264. E-mail: viscolic@unige.it.

TABLE 1. Clinical characteristics of five bone marrow transplantation patients with probable cerebral aspergillosis

Patient no.	Underlying disease ^a	Time (days) from BMT ^b to:		Clinical presentation	Histology at autopsy	<i>Aspergillus</i> colonization
		Neurological symptoms	1st CSF sample			
1	NHL	72	74	Fever, hemiparesis, and coma	Diffuse cerebral infiltration with hyaline septate, acute branching hyphae	No
2	ALL	5	44	Fever; neurological deficit at the right arm and at the left leg; rapid neurological deterioration; seizures; coma	Diffuse meningeal and parenchymal infiltration with hyaline septate, acute branching hyphae	No
3	SAA	113	118	Fever, seizures, sensory loss	Not performed	Yes
4	ALL	54	61	Fever, sinusitis, seizures, sensory loss, hemiparesis, and coma	Not performed	Yes
5	AML	185	190	Anisocoria, hemiparesis	Diffuse cerebral infiltration with hyaline septate, acute branching hyphae	No

^a NHL, non-Hodgkin lymphoma; ALL, acute lymphoblastic leukemia; SAA, severe acute aplasia; AML, acute myeloid leukemia.

^b BMT, bone marrow transplantation.

molecule whose molecular weight is intermediate between those of albumin and IgG. Therefore, we postulated that the CSF albumin/serum albumin quotient (QAlb), which indicates the amount of albumin crossing the blood-brain barrier, could represent a maximal estimate of the amount of GM crossing the barrier. As shown by the increased QAlb values (Table 2), all patients had some degree of blood-brain barrier damage. Based on the QAlb, we calculated the expected CSF GM index, i.e., the index we should have found if the presence of GM in CSF were due only to passive transfer. Finally, the actual CSF GM index was estimated and, for each patient, the difference between the measured and expected CSF GM indexes (which indicates intrathecally produced GM) was calculated and divided by the measured GM index. The final quotient represented the percentage of intrathecally produced GM. Overall, the median expected CSF GM index was 0.053 (SD, 0.196), while the median measured CSF GM index was 26.144 (SD, 252.900). The difference was highly statistically significant ($P < 0.001$). The percentage of the total CSF galactomannan that was intrathecally produced ranged from 95.6 to 99.9%.

To determine whether patients with cerebral or pulmonary aspergillosis might be distinguished just on the basis of the serum GM index (which might render the CSF test unnecessary), the test was also performed on a second control group of five patients with documented pulmonary aspergillosis and without cerebral aspergillosis (45 samples), and these results were compared with those obtained for our original group of patients with cerebral aspergillosis (five patients, 56 samples). As shown in Fig. 2, the median serum GM index was higher in patients with cerebral aspergillosis (median, 3.05; mean, 6.007; SD, 5.91; range, 1 to 25.709) than in patients with pulmonary aspergillosis (median, 2.118; mean, 37.154; SD, 212.082; range, 0 to 1,424.14) ($P < 0.01$). However, a box plot analysis showed considerable overlap between the two groups (95% confidence interval, 4.46 to 7.55 for cerebral aspergillosis versus -18.39 to 92.7 for pulmonary aspergillosis). In fact, 78% of the GM index values in patients with cerebral aspergillosis were contained within the 25th and 75th percentiles of those obtained from patients with pulmonary aspergillosis.

We recognize that none of our patients with cerebral disease might be defined as having documented aspergillosis, since in no case was confirmation obtained by culture from infected tissues. Three of these patients had autopsy-documented mold infections, and two had compatible clinical disease with evidence of nasal colonization. However, all of them had several positive results by serum GM antigen detection, a test which has been shown to be sensitive and specific for the diagnosis of aspergillosis. According to some authorities, positive *Aspergillus* GM antigenemia combined with appropriate clinical signs in patients at high risk for aspergillosis constitutes evidence which is almost equivalent to histological documentation of hyphae, even in the absence of confirmation by culture (3). In addition, *Aspergillus* accounts for most of the cases of brain abscess in bone marrow transplant recipients (2), and cross-reactivity for the EB-A2 monoclonal antibody has been demonstrated only with filamentous fungi, which usually are not involved in invasive infections (5, 9, 14). A possible exception is *Fusarium*, which, however, rarely causes isolated cerebral lesions. Moreover, a recent and specific report seems to exclude any cross-reaction (14). For all these reasons, we considered another etiology extremely unlikely. Other studies

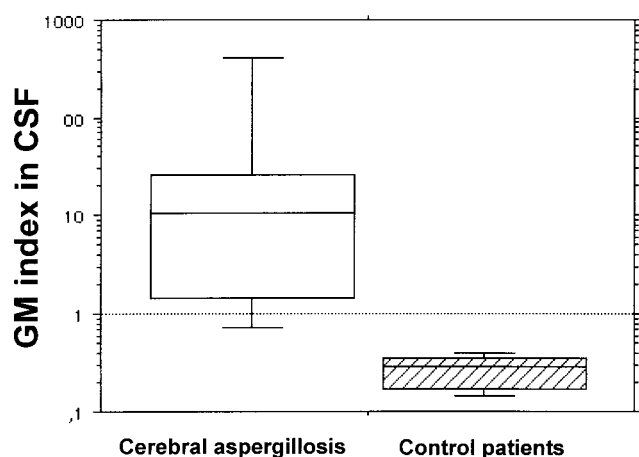


FIG. 1. Box plot analysis of CSF GM index for patients with or without cerebral aspergillosis, demonstrating the specificity of the test when performed in CSF.

TABLE 2. CSF and serum parameters, expected and measured CSF GM index, and percentage of total GM content that was intrathecally produced

Patient no.	QAlb (mg/dl) ^a	IgG index ^b	Serum GM index	CSF GM index		Intrathecal produced GM ^c
				Measured	Expected	
1	23.886	0.671	3.099	1.715	0.074	95.684
2	18.605	0.674	25.709	578.499	0.478	99.917
3 ^d	8.125	0.699	2.626	26.378	0.021	99.919
4 ^e	17.778	0.647	3.520	26.144	0.063	99.761
5	11.950	0.988	1.307	0.549	0.016	97.155

^a Normal values, 1.92 to 7.3 mg/dl.^b Normal values, 0.236 to 0.669.^c Expressed as a percentage of total GM.^d In one additional CSF sample, the GM index was 18.417.^e In two additional CSF samples, the GM index values were 2.586 and 1.161.

have already suggested the potential value of the GM antigen detection test for diagnosis of cerebral aspergillosis. Verweij et al. (16) studied 26 CSF samples from a single patient with documented *Aspergillus* meningitis and found that the test result became positive 45 days before the positive CSF culture. Comparison with control CSF specimens from patients without aspergillosis showed good specificity. These authors also suggested that the cutoff for CSF positivity might be lower than the cutoff for serum positivity. Kami et al. (4) studied 5 patients with documented cerebral aspergillosis and 11 controls. They found that the test was 100% sensitive and specific for the diagnosis of cerebral aspergillosis.

In conclusion, in the present study we showed a statistically significant difference in the CSF GM indexes between patients with cerebral aspergillosis and a control group of patients with other neurological diseases. The great majority of the GM in CSF (95.68 to 99.92%) was apparently produced intrathecally, as shown by the difference between expected and measured CSF GM indexes in cerebral aspergillosis patients. Finally, serum GM indexes seem to be unable to discriminate between patients with pulmonary and cerebral disease, as shown by the remarkable overlapping of values between the two groups. Our study suggests that the *Aspergillus* CSF GM index might be diagnostic for cerebral aspergillosis in patients at high risk for

aspergillosis and with a compatible neurological disease. Further studies on larger patient populations might be necessary in order to fully evaluate the role of this test in the diagnosis of this dreadful disease.

This work was supported by the Ministero della Sanità, Istituti di Ricerca a Carattere Scientifico (Progetto 120.5/RF98.88), and the Università di Genova, Genoa, Italy.

REFERENCES

1. Ascoglu, S., J. H. Rex, B. De Pauw, J. E. Bennett, J. Bille, F. Crokaert, D. W. Denning, J. P. Donnelly, J. E. Edwards, Z. Erjavec, D. Fiere, O. Lortholary, J. Maertens, J. F. Meis, T. F. Patterson, J. Ritter, D. Selleslag, P. M. Shah, D. A. Stevens, and T. J. Walsh on behalf of the Invasive Fungal Infections Co-operative Group of the European Organization for Research and Treatment of Cancer and the Mycoses Study Group of the National Institute of Allergy and Infectious Diseases. 2002. Defining opportunistic invasive fungal infections in immunocompromised patients with cancer and hematopoietic stem cell transplants: an international consensus. *Clin. Infect. Dis.* **34**:7–14.
2. Denning, D. W. 1998. Invasive aspergillosis. *Clin. Infect. Dis.* **26**:781–805.
3. Denning, D. W. 2000. Early diagnosis of invasive aspergillosis. *Lancet* **355**:423–424.
4. Kami, M., S. Ogawa, Y. Kanda, Y. Tanaka, U. Machida, T. Matsumura, H. Sakamaki, and H. Hirai. 1999. Early diagnosis of central nervous system aspergillosis using polymerase chain reaction, latex agglutination test, and enzyme-linked immunosorbent assay. *Br. J. Haematol.* **106**:536–537.
5. Kappe, R., and A. Schulze-Berge. 1993. New cause for false-positive results with the Pastorex *Aspergillus* antigen latex agglutination test. *J. Clin. Microbiol.* **31**:2489–2490.
6. Latgé, J. P., H. Kobayashi, J. P. Debeaupuis, M. Diaquin, J. Sarfati, J. M. Wieruszski, E. Parra, J. P. Bouchara, and B. Fournet. 1994. Chemical and immunological characterization of the extracellular galactomannan of *Aspergillus fumigatus*. *Infect. Immun.* **62**:5424–5433.
7. Machetti, M., M. Feasi, N. Mordini, M. T. Van Lint, A. Bacigalupo, J. P. Latgé, J. Sarfati, and C. Viscoli. 1998. Comparison of an enzyme immunoassay and a latex agglutination system for the diagnosis of invasive aspergillosis in bone marrow transplant recipients. *Bone Marrow Transplant.* **21**:917–921.
8. Machetti, M., M. Zotti, L. Veroni, N. Mordini, M. T. Van Lint, A. Bacigalupo, D. Paola, and C. Viscoli. 2000. Antigen detection in the diagnosis and management of a patient with probable cerebral aspergillosis treated with voriconazole. *Transplant. Infect. Dis.* **2**:140–144.
9. Maertens, J., J. Verhaegen, H. Demuyne, P. Brock, G. Verhoef, P. Vandenberghe, J. Van Eldere, L. Verbist, and M. Boogaerts. 1999. Autopsy-controlled prospective evaluation of serial screening for circulating galactomannan by a sandwich enzyme-linked immunosorbent assay for hematological patients at risk for invasive aspergillosis. *J. Clin. Microbiol.* **37**:3223–3228.
10. Pagano, L., P. Ricci, M. Montillo, A. Cenacchi, A. Nosari, A. Tonso, L. Cudillo, A. Chierichini, C. Savignano, M. Buelli, L. Melillo, E. O. La Barbera, S. Sica, S. Hohaus, A. Bonini, G. Bucaneve, and A. Del Favero. 1996. Localization of aspergillosis to the central nervous system among patients with acute leukemia: report of 14 cases. Gruppo Italiano Malattie Ematologiche dell'Adulto Infection Program. *Clin. Infect. Dis.* **23**:628–630.
11. Rohrlach, P., J. Sarfati, P. Mariani, M. Duval, A. Carol, C. Saint Martin, E. Bingen, J. P. Latgé, and E. Vilmer. 1996. Prospective sandwich enzyme-linked immunosorbent assay for serum galactomannan: early predictive value and clinical use in invasive aspergillosis. *Pediatr. Infect. Dis. J.* **15**:232–237.

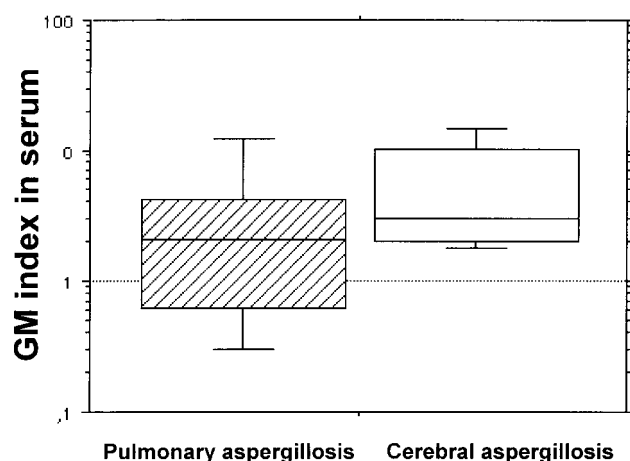


FIG. 2. Box plot analysis of serum GM index for patients with pulmonary or cerebral aspergillosis, demonstrating the poor discriminatory ability of the test when performed in serum.

12. Styne, D., A. Goris, J. Sarfati, and J. P. Latgé. 1995. A new sensitive sandwich enzyme-linked immunosorbent assay to detect galactofuran in patients with invasive aspergillosis. *J. Clin. Microbiol.* **33**:497–500.
13. Sulahian, A., M. Tabouret, P. Ribaud, J. Sarfati, E. Gluckman, J. P. Latgé, and F. Derouin. 1996. Comparison of an enzyme immunoassay and latex agglutination test for detection of galactomannan in the diagnosis of invasive aspergillosis. *Eur. J. Clin. Microbiol. Infect. Dis.* **15**:139–145.
14. Swanink, C. M., J. F. Meis, A. J. Rijs, J. P. Donnelly, and P. E. Verweij. 1997. Specificity of a sandwich enzyme-linked immunosorbent assay for detecting *Aspergillus* galactomannan. *J. Clin. Microbiol.* **35**:257–260.
15. Tibbling, G., H. Link, and S. Öhman. 1977. Principles of albumin and IgG analyses in neurological disorders. I. Establishment of reference value. *Scand. J. Clin. Lab. Invest.* **37**:385–390.
16. Verweij, P. E., K. Brinkman, H. P. H. Kremer, B. J. Kullberg, and J. F. Meis. 1999. *Aspergillus* meningitis: diagnosis by non-culture-based microbiological methods and management. *J. Clin. Microbiol.* **37**:1186–1189.
17. Verweij, P. E., E. C. Dompeling, J. P. Donnelly, A. V. Schattenberg, and J. F. Meis. 1997. Serial monitoring of *Aspergillus* antigen in the early diagnosis of invasive aspergillosis. Preliminary investigations with two examples. *Infection* **25**:86–89.
18. Verweij, P. E., J. P. Latgé, A. J. M. M. Rijs, W. J. C. Melchers, B. E. De Pauw, J. A. A. Hoogkamp-Korstanje, and J. F. G. M. Meis. 1995. Comparison of antigen detection and PCR assay using bronchoalveolar lavage fluid for diagnosing invasive pulmonary aspergillosis in patients receiving treatment for hematological malignancies. *J. Clin. Microbiol.* **33**:3150–3153.