

A STAIN FOR FUNGI IN TISSUE SECTIONS AND SMEARS

USING GOMORI'S METHENAMINE-SILVER NITRATE TECHNIC

ROBERT G. GROCOTT, B.S., M.T. (ASCP)

Department of Pathology, Board of Health Laboratory, Gorgas Hospital, Ancon, Canal Zone

Although the histopathologic study of the various mycoses has been greatly facilitated by the introduction of a number of new staining methods for fungi such as the Hotchkiss-McManus⁵ and Gridley⁴ technics, the results, while colorful, do not always lend themselves to the more easily performed photomicrographic procedures. With the Hotchkiss-McManus technic using periodic acid oxidation there is some troublesome staining of the tissue background. This has been overcome to a great extent by the Gridley technic. This latter method using chromic acid oxidation is quite acceptable for screening purposes; however, the different shades of red and purple on a yellow background are extremely difficult to photograph without the use of expensive color filters. Even with the use of properly selected Wratten filters and precise conditions of illumination, attempts to obtain truly pictorial photomicrographs of fungi in tissues stained by these technics frequently meet with failure. This is particularly true of smaller organisms such as *Histoplasma capsulatum*. Moreover, sudden deterioration of Schiff's reagent⁸ and aldehyde-fuchsin together with variations in results due to the use of different lots of basic fuchsin detract somewhat from the usefulness of these staining technics.

In an attempt to circumvent these difficulties it was found that highly photogenic black-and-white preparations of fungi in tissues could be produced using Gomori's methenamine-silver nitrate technic.² In such preparations fungal elements appear as sharply delineated black-staining structures on a background which remains largely unstained unless counterstaining is employed. As far as can be determined from a review of the literature at hand, this technic has not been used for this purpose. It is believed that its simplicity and dependability justify this preliminary report.

METHOD

Solutions

1. Five per cent aqueous chromic acid (chromium trioxide, CrO_3).
2. Stock methenamine-silver nitrate solution. Add 5 ml. of 5 per cent AgNO_3 to 100 ml. of 3 per cent methenamine, U.S.P. grade $[(\text{CH}_2)_6\text{N}_4]$. A white precipitate forms but immediately dissolves on shaking. The clear solution remains usable for months at refrigerator temperature.
3. One per cent aqueous sodium bisulfite (NaHSO_3).
4. Five per cent aqueous borax, U.S.P. grade ($\text{Na}_2\text{B}_4\text{O}_7 \cdot 10\text{H}_2\text{O}$).
5. One-tenth per cent aqueous gold chloride ($\text{AuCl}_3 \cdot \text{HCl} \cdot 3\text{H}_2\text{O}$). This may be used repeatedly.
6. Two per cent aqueous sodium thiosulfate ($\text{Na}_2\text{S}_2\text{O}_3 \cdot 5\text{H}_2\text{O}$).

Received for publication January 28, 1955; accepted, March 30, 1955.
Mr. Grocott is Chief Histopathology Technician.

Procedure

1. Deparaffinize sections in xylol and run through alcohols to water. Smears are prepared on albumin-treated slides and fixed in 95 per cent alcohol. Slides previously stained with hematoxylin and eosin may be used by removing cover glasses in xylol and running through alcohols to water. Subsequent chromic acid treatment will remove any remaining stain.
2. Hydrated sections and smears are oxidized in 5 per cent chromic acid for 1 hour, washed in running tap water 10 minutes, and then treated in sodium bisulfite for 1 minute to remove any residual chromic acid. They are then washed in tap water for 5 minutes and finally in 3 changes of distilled water.
3. Silver at 45-50 C. in a working solution prepared by adding 25 ml. of stock methenamine-silver nitrate to an equal portion of distilled water containing 1 to 2 ml. of 5 per cent borax. Fungi and mucin will begin to stain yellowish brown in 25 to 30 minutes and will be adequately stained at the end of 1 hour. Slides are then rinsed in distilled water 2 or 3 times.
4. Tone in 0.1 per cent gold chloride for 5 minutes. This will also bleach the background. Rinse in distilled water.
5. Remove unreduced silver by treating with 2 per cent sodium thiosulfate for 1 or 2 minutes and after washing thoroughly, counterstain if desired. Aqueous safranin may be used if a red nuclear stain is desired, or a light hematoxylin-eosin combination may be used if tissue detail is important.
6. Dehydrate, clear and mount as usual.

Results

Fungi are sharply delineated in black with the inner parts of mycelia and hyphae staining an old rose as a result of toning in gold. Mucin also assumes a rose-red color as a result of toning.

DISCUSSION

The methenamine-silver nitrate procedure as reported by Gomori in 1946 was designed as a histochemical test for glycogen and mucin. The essential chemical phenomena involved are the liberation of aldehyde groups as the result of pretreatment with chromic acid and their subsequent detection by the reduction of an alkaline methenamine-silver nitrate complex. Since the well-known Hotchkiss-McManus and Gridley stains for fungi likewise depend upon the liberation of aldehyde groups, it was thought that the methenamine-silver nitrate method might also be applicable to the staining of fungi. The successful staining of *Histoplasma capsulatum* in a section of lung granuloma convinced the writer that this technic has definite utility in detecting these small organisms, particularly when they are present in sparse numbers in areas of necrosis. Further trials using

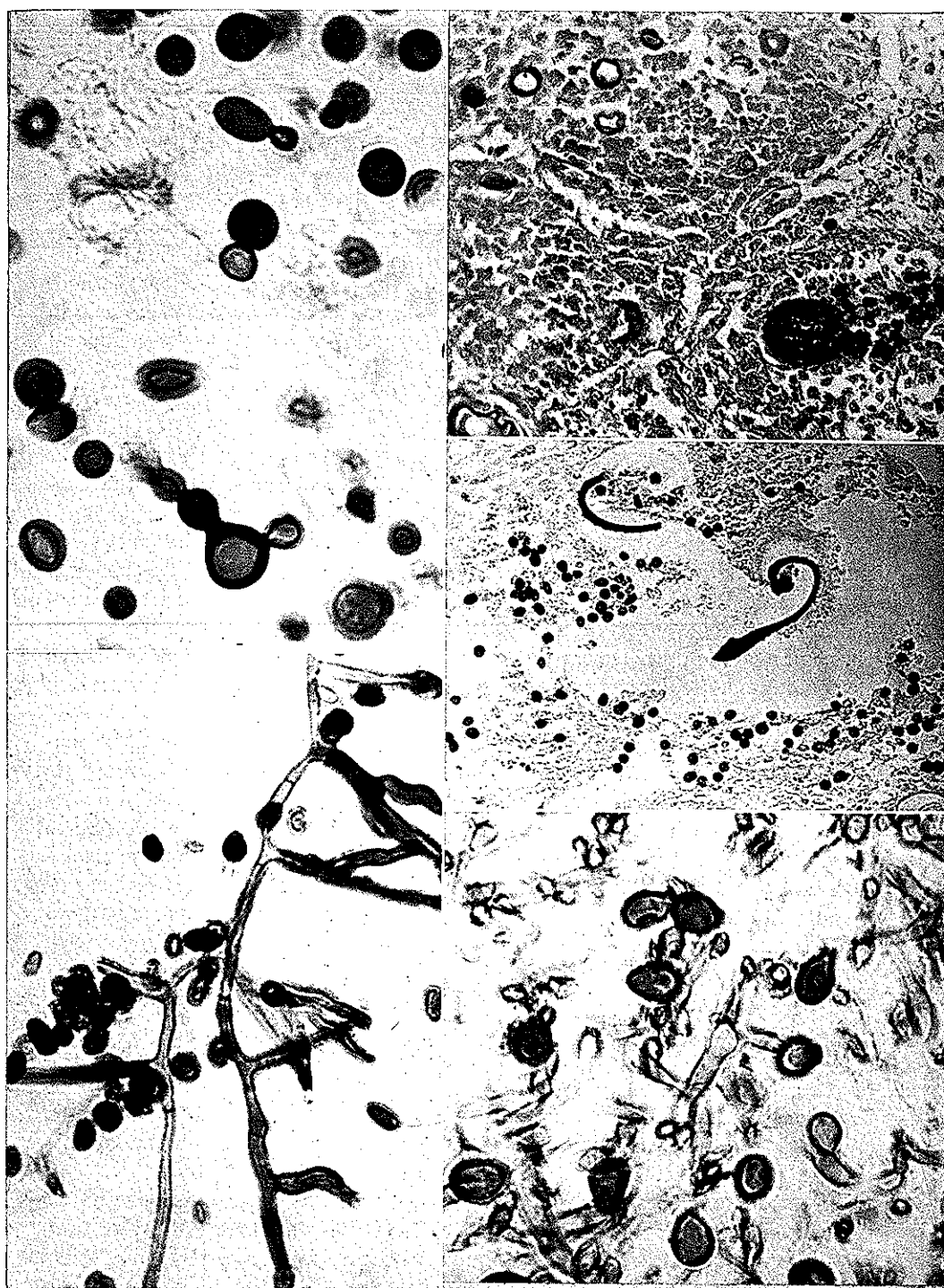
Fig. 1 (left upper). Budding forms of *Cryptococcus neoformans* in section of lymph node. Methenamine-silver nitrate technic. High dry. $\times 1100$.

Fig. 2 (left lower). Smear of saprophytic fungus in culture. Methenamine-silver nitrate with eosin counterstain. High dry. $\times 1100$.

Fig. 3 (right upper). Section of lung from fatal case of coccidioidomycosis. A ruptured spherule of *Coccidioides immitis* and extruded endospores are seen. Methenamine-silver nitrate with light hematoxylin and eosin counterstain. High dry. $\times 250$.

Fig. 4 (right middle). A ruptured sporangium of *Rhinosporidium seeberi* in a section of nasal polyp. The everted wall and liberated endospores are seen. The other smaller sporangia do not stain. Methenamine-silver nitrate technic. High dry. $\times 250$.

Fig. 5 (right lower). Section of necrotic material from nose showing saprophytic fungi. Spores and filaments clearly seen. Methenamine-silver nitrate technic. High dry. $\times 1100$.



FIGS. 1-5

sections containing *Cryptococcus neoformans*, *Coccidioides immitis*, *Rhinosporidium seeberi* and *Monilia* sp. and other organisms reveal that the silver technic may be relied upon to give excellent results with most types of fungal pathogens. Duplicate sections of the same material stained by the Gridley method show identical components staining various hues of red and purple but often with less definition and clarity.

Smears of several different fungi in culture were also satisfactorily stained by the silver technic. Sections containing the ray fungus, *Actinomyces bovis*, were poorly stained and showed little or no darkening of the "clubs." Equally disappointing results were also obtained for this fungus using the Gridley method. Conant and co-workers¹ state that the periodic acid-Schiff stain is of no help in demonstrating the filaments of *Actinomyces* and *Nocardia*. They recommend Gram's staining procedure for these fungi.

It may be of interest to state that sections of nasal polyp infected with *Rhinosporidium seeberi* revealed only isolated staining of sporangia by both the methenamine-silver nitrate and Gridley methods. Apparently only the larger and more mature sporangia and their contained endospores possess the saccharides that give a positive staining reaction.

It must be emphasized here that the Gomori method is not another capricious silver-impregnation technic such as those used in neurohistology, but is believed to be a specific histochemical test for aldehydes. It may be likened to the argentaffin reaction² for certain intrinsic reducing substances present in the enterochromaffin system. In contrast, the conventional silver procedures for nerve elements and reticulum are pure reduction technics dependent upon variously used extrinsic reducers such as formalin and hydroquinone.

As to the specificity of the methenamine-silver nitrate technic, it must be conceded that it is not wholly specific for the cellulose-chitin aggregates characteristic of fungi since other substances such as glycogen, mucin and vascular elastin may act as reducing agents. Ordinary tissue glycogen is usually not stained owing to its ready solubility in aqueous mediums. Mucin is easily identified by its association with glandular elements. Calcium deposits are known to reduce silver solutions and Gomori suggested the use of a citrate buffer of pH 3 to remove them before staining. It has been found, however, that the 1-hour pretreatment with chromic acid will suffice to remove the usual granular types of insoluble calcium salts. Amyloid deposits as well as melanin pigment failed to stain by this technic.

The ease with which almost any desired counterstain may be employed is regarded as a distinct advantage. Even the hematoxylin-eosin combination may be used without obscuring the structural details of the fungi. This may be of considerable importance when relationships between the causative organism and class of tissue response (giant-cell formation, plasma cell infiltration, epithelioid reaction) are under consideration.

It is not proposed that the methenamine-silver nitrate technic be used to supplant either the Hotchkiss-McManus or the Gridley methods but rather that it will serve as a supplementary staining procedure for fungi. However, aside from the striking and dependable results obtained, this technic has the further

advantages of employing stable solutions and comparatively inexpensive reagents that are readily available in most hospital pharmacies or laboratories.

SUMMARY

The use of Gomori's methenamine-silver nitrate method as a staining procedure for fungi in tissue sections and smears is discussed. This method using readily available reagents and stable solutions produces highly photogenic preparations without the use of costly color filters.

Acknowledgment. The author wishes to express his appreciation to Mr. Harry A. Dunn for his kindness in taking the photomicrographs.

REFERENCES

1. CONANT, N. F., SMITH, D. T., BAKER, R. D., CALLAWAY, J. L., AND MARTIN, D. S.: Manual of Clinical Mycology. Ed. 2. Philadelphia: W. B. Saunders Co., 1954, p. 420.
2. GOMORI, G.: A new histochemical test for glycogen and mucin. *Am. J. Clin. Path.*, **10**: 177-179, 1946.
3. GOMORI, G.: Microscopic Histochemistry: Principles and Practice. Chicago: The University of Chicago Press, 1952, p. 58.
4. GRIDLEY, M. F.: A stain for fungi in tissue sections. *Am. J. Clin. Path.*, **23**: 303-307, 1953.
5. KLIGMAN, A. M., MESCON, H., AND DELAMATER, E. D.: The Hotchkiss-McManus stain for the histopathologic diagnosis of fungus diseases. *Am. J. Clin. Path.*, **21**: 86-91, 1951.
6. LHOTKA, J. F., AND DAVENPORT, H. A.: Deterioration of Schiff's reagent. *Stain Technol.*, **24**: 237-239, 1949.