



CASE REPORT

Aspergillus thyroiditis in a living donor liver transplant recipient[☆]

Yuichi Matsui^a, Yasuhiko Sugawara^{a,*}, Kuniyoshi Tsukada^b,
Yoji Kishi^a, Junji Shibahara^c, Masatoshi Makuuchi^a

^a Department of Surgery, Artificial Organ and Transplantation Division,
Graduate School of Medicine, University of Tokyo, Tokyo 7-3-1 Hongo, Bunkyo-ku,
Tokyo 113-8655, Japan

^b Department of Infectious Disease, Graduate School of Medicine, University of Tokyo,
Tokyo 7-3-1 Hongo, Bunkyo-ku, Tokyo 113-8655, Japan

^c Department of Pathology, Graduate School of Medicine, University of Tokyo,
Tokyo 7-3-1 Hongo, Bunkyo-ku, Tokyo 113-8655, Japan

Accepted 10 February 2006

Available online 29 March 2006

KEYWORDS

Aspergillosis;
Liver transplantation;
Fulminant hepatitis;
Living donor

Summary Aspergillosis is increasingly recognized as an important nosocomial pathogen in immunocompromised patients. Infection is difficult to diagnose and typically has a fatal outcome. We describe a liver transplant patient with fulminant hepatic failure, who had persistent fever of undetected origin postoperatively and an increased (1–3)-beta-D glucan level. Gallium-67 citrate scanning showed abnormal uptake in the thyroid bilaterally. Fine needle biopsy of the thyroid revealed thyroidal invasion of Aspergillosis. Total thyroidectomy was performed and the C reactive protein level decreased to 1.01 mg/dl. The patient died of liver sepsis due to *Pseudomonas aeruginosa*. (1–3)-beta-D Glucan monitoring and systematic radionuclide images are useful modalities for early diagnosis of Aspergillosis.

© 2006 The British Infection Society. Published by Elsevier Ltd. All rights reserved.

Abbreviations: BDG, (1–3)-beta-D glucan; POD, postoperative day.

[☆] Grant support: Supported by a Grant-in-aid for Scientific Research from the Ministry of Education, Culture, Sports, Science and Technology of Japan and Grants-in-aid for Research on HIV/AIDS, a multicenter pilot clinical study to compare the safety and efficacy of a steroid free immunosuppression protocol with monoclonal anti-IL2R antibody in HCV positive living donor liver transplantation and Research on Measures for Intractable Diseases from the Ministry of Health, Labor and Welfare of Japan.

* Corresponding author. Tel.: +81 3 3815 5411; fax: +81 3 5684 3989.

E-mail address: yasusuga-tky@umin.ac.jp (Y. Sugawara).

Introduction

Invasive aspergillosis, defined as the growth of *Aspergillus* species from tissue obtained by biopsy, surgical resection, or autopsy,¹ is a rare but devastating complication with high mortality rates in immunocompromised patients. Patient survival depends on early diagnosis and prompt initiation of therapeutic measures, which is complicated by the fact that there is no effective antifungal prophylaxis against aspergillosis.

We describe a patient who developed *Aspergillus* thyroiditis following living donor liver transplantation. A detailed description of his clinical course provides important information on the clinical features of thyroid involvement by invasive Aspergillosis.

Case report

A 62-year-old male patient with no past history of liver disease was referred to our hospital for fulminant hepatic failure. Living donor liver transplantation using the left liver graft was performed. The postoperative course was uneventful postoperative day (POD) 60, except for positive cytomegalovirus antigenemia, which was treated by ganciclovir administration. On POD 63, his (1–3)-beta-D glucan (BDG) level had increased to 51 pg/ml (normal range <11 pg/ml). Sputum culture revealed *Candida albicans*. Chest computed tomography revealed a ground glass appearance in the right lower lung, which was suspected to be *Pneumocystis jiroveci* infection. Polymerase chain reaction results of the sputum for *P. jiroveci*,

however, were negative. Serum alactomannan *Aspergillus* antigen, which had been checked once a week, was negative (<0.5 ODI). We started fluconazole and trimethoprim on POD 63 because Candidiasis and *P. jiroveci* pneumonia were suspected. Fluconazole therapy was changed to micafungin 2 weeks after beginning the administration. Voriconazole and caspofungin were not approved for this use at the time in Japan. In spite of the antifungal therapy, the BDG level increased to 112 pg/ml on POD 84.

Gallium-67 scintigraphy was taken on POD 108 for systemic screening of the causative site of infection, which showed abnormal uptake bilaterally in the thyroid (Fig. 1A). Fine needle biopsy of the thyroid gland revealed *Aspergillus* invasion. Total thyroidectomy was performed on POD 118, and was followed by administration of Amphotericin B (15 mg/day). A resected specimen of the thyroid showed an extensive abscess with diffuse *Aspergillus* hyphae infiltration (Fig. 1B). Two weeks after thyroidectomy, BDG and C reactive protein levels decreased to 7.2 pg/ml and 1.01 mg/dl, respectively. On the POD125, the patient suddenly suffered from high grade fever of 39.9 °C with an elevated C reactive protein level (29.2 mg/dl). The patient died of sepsis due to abscess formation of *Pseudomonas aeruginosa* in the hepatic graft on POD 159.

Discussion

The lungs are the most common primary site of infection with sinus disease having nearly the same frequency.² The thyroid is a relatively frequent

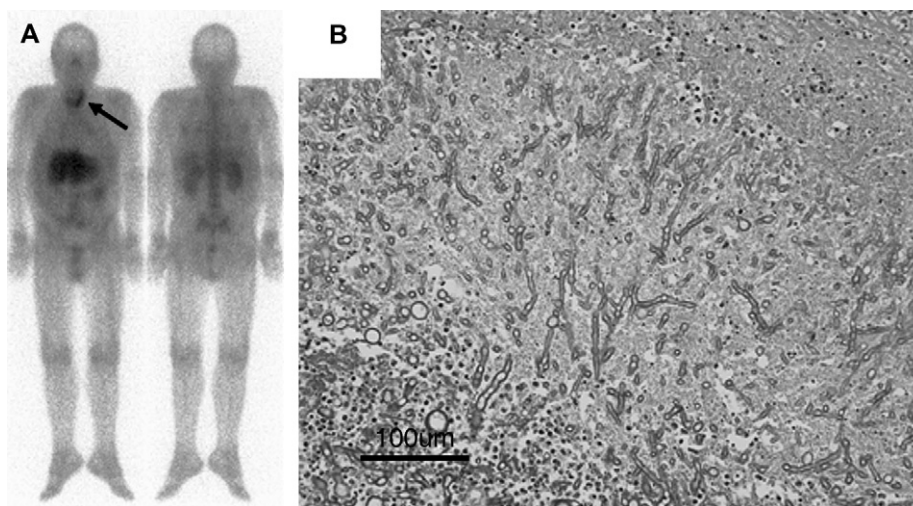


Figure 1 (A) Gallium scintigraphy on postoperative day 109. Note abnormal uptake in thyroid (arrow). (B) Hematoxylin and eosin stain of the specimen. Note extensive abscess with diffuse *Aspergillus* hyphae infiltration.

site of infection of invasive aspergillosis. Previous autopsy studies revealed that 9–15% of invasive aspergillosis involves the thyroid.³ Most patients with thyroidal invasion remain asymptomatic⁴ and it is usually difficult to diagnose in the ante-mortem period. Gallium scintigraphy is useful for the detection of occult thyroid lesions.⁵

To our knowledge, this is the first report of thyroidal involvement of invasive aspergillosis with a detailed description of the clinical course after liver transplantation, although there are reports of invasive aspergillosis after cardiac⁶ and renal⁷ transplantations. Thyroidectomy, followed by anti-fungal drug administration, was performed in both patients. One patient died of pulmonary aspergillosis⁶ and the other died of myocardial involvement with aspergillosis.⁷

We describe a liver transplant patient with fulminant hepatic failure, who had persistent fever of undetected origin postoperatively with an elevated BDG level. Invasive aspergillosis of the thyroid was detected by gallium scintigraphy. Monitoring BDG is key for early diagnosis of fungal

infection and gallium scintigraphy might be a useful modality to determine the causative site of fungal infection.

References

1. Stevens DA, Lee JY. Analysis of compassionate use itraconazole therapy for invasive aspergillosis by the NIAID Mycoses Study Group criteria. *Arch Intern Med* 1997;**157**:1857–62.
2. Stevens DA, Kan VL, Judson MA, Morrison VA, Dummer S, Denning DW, et al. Practice guidelines for diseases caused by *Aspergillus*. Infectious Diseases Society of America. *Clin Infect Dis* 2000;**30**:696–709.
3. Denning DW. Therapeutic outcome in invasive aspergillosis. *Clin Infect Dis* 1996;**23**:608–15.
4. Berger SA, Zonszein J, Villamena P, Mittman N. Infectious diseases of the thyroid gland. *Rev Infect Dis* 1983;**5**:108–22.
5. Bach MC, Blattner S. Occult *Candida* thyroid abscess diagnosed by gallium-67 scanning. *Clin Nucl Med* 1990;**15**:395–6.
6. Hornef MW, Schopohl J, Zietz C, Hallfeldt KK, Roggenkamp A, Gartner R, et al. Thyrotoxicosis induced by thyroid involvement of disseminated *Aspergillus fumigatus* infection. *J Clin Microbiol* 2000;**38**:886–7.
7. Elzi L, Laifer G, Bremerich J, Vosbeck J, Mayr M. Invasive aspergillosis with myocardial involvement after kidney transplantation. *Nephrol Dial Transplant* 2005;**20**:631–4.