

# Canine Nasal Aspergillosis

Noémi Benitah, DVM, DACVIM

Chronic nasal discharge is a common clinical sign of disease in dogs. Canine sinonasal aspergillosis is a relatively common disease in dogs. The three hallmarks of canine nasal aspergillosis are a profuse mucoid to hemorrhagic chronic nasal discharge that may alternate with periods of epistaxis, ulceration of the external nares with crusting, and pain or discomfort in the facial region. Diagnostic imaging (preferably computed tomography, CT) of the nasal cavity and paranasal sinuses is an important component of the evaluation of dogs with signs of nasal disease. Rhinoscopy is an important part of both the diagnosis and the therapy for nasal aspergillosis. Therapeutic recommendations for sinonasal aspergillosis have included surgery and the use of several systemic and topical antifungal drugs.

Clin Tech Small Anim Pract 21:82-88 © 2006 Elsevier Inc. All rights reserved.

**KEYWORDS** aspergillosis, canine, nasal cavity

Chronic nasal discharge is a common clinical sign of disease in dogs. Sneezing and nasal discharge are the primary signs of sinus, nasal, and/or nasopharyngeal disorders in the dog. The type of discharge (serous, mucoid, purulent, hemorrhagic), the onset and duration of the nasal problem, and response to therapy should be evaluated. If one of these problems persists, sneezing may decrease over time, but nasal discharge usually persists, increasing in severity and sometimes changing in character. It is helpful to determine whether the process began as unilateral or bilateral and if it is static or progressive. The most common causes of chronic nasal discharge include nasal neoplasia, fungal sinorhinitis (most commonly caused by *Aspergillus fumigatus*), nasal foreign body, rhinitis secondary to dental disease, and idiopathic lymphoplasmacytic rhinitis.<sup>1</sup> Sinonasal aspergillosis may occur as an opportunistic primary infection or secondary to the presence of a foreign body, previous nasal trauma, or neoplasia. Specific treatment is most effective when the etiopathogenesis is known.

## Physical Examination

Before beginning the examination, the respiratory pattern of the dog at rest should be determined. Upper airway or nasal obstruction can lead to incessant panting or persistent open-mouth breathing. For all dogs with nasal discharge, a simple assessment and comparison of airflow through the nasal passages can be made, either with a cotton wisp held up to each


nostril or with the use of a chilled microscope slide. The ability of the dog to breathe with the mouth closed should also be determined. Careful palpation of the head, nasal planum, and palate will detect regions of pain, bony deformation, or masses. Asymmetric retropulsion of the eyes can be an important clue to the presence of a mass lesion in one side of the nasal cavity that restricts movement of the globe. Regional lymph nodes should be palpated carefully. Fungal rhinitis resulting from aspergillosis has been associated with depigmentation of the epithelium of the alar fold (Fig. 1). A careful examination of the oral cavity is mandatory in dogs presenting for nasal disease (Fig. 2). Attention should be given to the hard palate, soft palate, tonsils, and teeth (fractures, defect in enamel).

## Diagnostic Approach to Nasal Discharge

Because most procedures needed to further evaluate the nasal cavity require general anesthesia, prior submission of a complete blood cell count, serum biochemistry profile, and urinalysis are indicated to evaluate for the presence of concurrent or contributing disorders. Coagulation profile and blood pressure measurement should be done if there is any history of epistaxis. Serologic testing using agar gel immunodiffusion (AGID), counter immunoelectrophoresis (CIE), and ELISA techniques to detect fungi-specific serum antibodies has been used as an aid in diagnosing fungal rhinitis due to *Aspergillus* and *Penicillium*. The AGID test has been performed for many years but can have a 6% false-positive rate.<sup>2</sup> Fifteen percent false-positive results were found using CIE.<sup>2</sup> Varying sensitivity and specificity of immunodiffusion have been reported. The AGID was reported to have 100% sensitivity and speci-

Diplomate of the American College of Veterinary Internal Medicine, Veterinary Medical Teaching Hospital, School of Veterinary Medicine, University of California, Davis, CA.

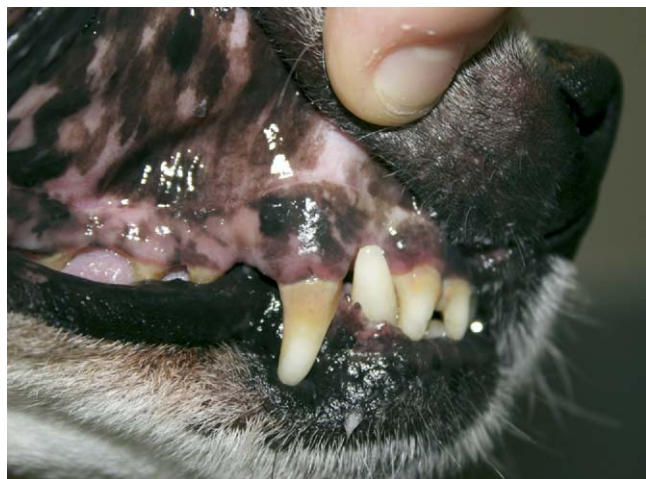Address reprint requests to: Red Bank Veterinary Hospital, 197 Hance Ave, Tinton Falls, NJ 07724. E-mail: nbenitah@vmth.ucdavis.edu.



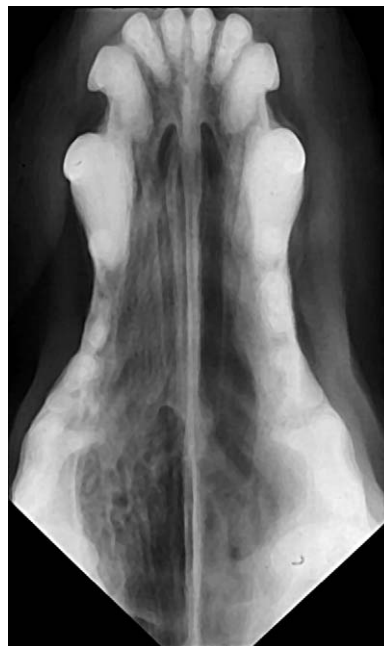
**Figure 1** Depigmentation of the nares of a dog with chronic sinonasal aspergillosis. (Color version of figure is available online.)

ficity for nasal aspergillosis.<sup>3</sup> A second report stated that 15% of dogs with nasal tumors were falsely positive serologically for aspergillosis or penicilliosis, although the total number of cases was not given.<sup>4</sup> A positive serology is supportive of a fungal rhinitis but should be interpreted in light of other diagnostic tests and not as being absolutely diagnostic. A negative result does not necessarily rule out a fungal etiology. Determination of the sensitivity and specificity of *Aspergillus* serology using AGID is currently under clinical investigation. Results of nasal bacterial and fungal cultures must be interpreted cautiously because they may only reflect airway colonization and not actually be the cause of a given invasive disease process. Bacteria are rarely the primary cause of nasal disease; secondary bacterial rhinitis is more common. Cytologic examination may reveal *Aspergillus* as contaminants. *Aspergillus* has been cultured from the nose of both healthy and diseased dogs from other causes.

Diagnostic imaging of the nasal cavity and paranasal sinuses is an important component evaluating dogs with signs of nasal disease. Imaging study permits evaluation of the extent and character of involvement of the calvarial bones

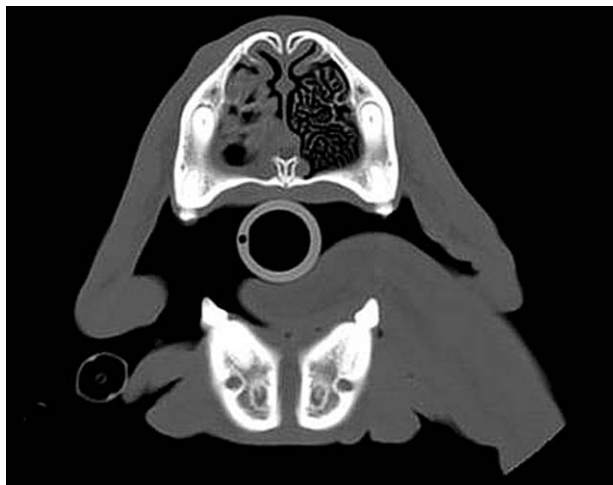

**Figure 2** A careful examination of the oral cavity is mandatory in patients presenting for nasal disease. (Color version of figure is available online.)



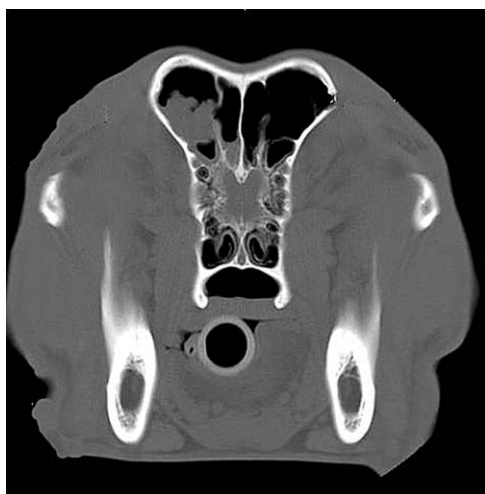**Figure 3** Intraoral dorsoventral radiograph of the nasal cavity of a dog with nasal aspergillosis with typical turbinate destruction and increase in radiolucency in the left nasal chamber.

and teeth, nasal turbinates and air passages, and paranasal sinus cavities, as well as to determine if the lesion has extended into the brain cavity or retrobulbar space. Survey radiography and computed tomography (CT) can be used to image the nasal cavity and paranasal sinuses and must be performed before rhinoscopic evaluation to avoid artifacts resulting from lavage, tissue manipulation, and hemorrhage during the latter. General anesthesia is necessary for optimal patient positioning and detailed visualization of anatomic structures. The intraoral dorsoventral radiographic position allows for the evaluation of the nasal cavity and turbinates and for the localization of disease to an affected side. Loss of structural symmetry, changes in nasal cavity density (increased or decreased), and bony abnormalities (loss of turbinates, nasal septum erosion, tooth root lysis, periosteal reaction) are some of the more typical radiographic findings encountered with nasal disease. The main radiologic features of nasal aspergillosis include a loss of fine nasal turbinate detail and an increase in radiolucency in the nasal chamber (Fig. 3). Nasal neoplasia is an important differential diagnosis for chronic nasal discharge and can mimic sinonasal aspergillosis. Radiographic features of nasal neoplasia overlap when compared with nasal aspergillosis and include increased soft-tissue density with associated turbinate, vomer bone, hard palate, and facial bone destruction. Nasal neoplasia is usually unilateral, although it can be bilateral. Frontal sinus involvement is common. Fungal granuloma may cause increased soft-tissue density in the frontal sinus, which may create a mass-like lesion. In a recent report comparing the radiographic and computed tomographic findings and evaluating the sensitivity of radiography and CT for diagnosis of nasal aspergillosis in dogs, the radiographic and CT studies of 48 dogs with chronic nasal disease were reviewed. Based on definite aspergillosis as a diagnosis, CT had a sensitivity of 88% and radiography of 72%.<sup>5</sup> In another recent study, the

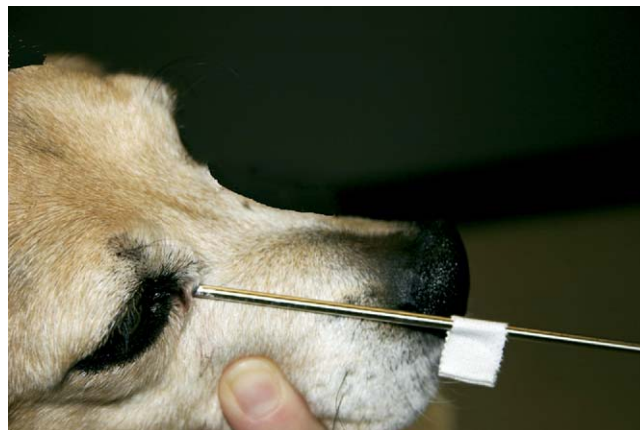

**Figure 4** Computed tomography of a dog with nasal aspergillosis. The reader should note the moderate degree of turbinde destruction, creating a cavitated appearance throughout the left nasal cavity.

features of radiography, magnetic resonance imaging, CT, and rhinoscopy with respect to nasal aspergillosis were compared. CT and MRI were more sensitive than radiography in revealing lesions suggestive of nasal aspergillosis.<sup>6</sup> CT offers several advantages relative to survey radiography, the most important being its ability to produce cross-sectional tomographic slices that avoid the problem of superimposing of structures inherent in flat film radiography. CT is superior to radiography for evaluation of the nasal cavities, frontal sinuses, and differentiation between a cavitated or mass-like process.<sup>5</sup> Fungal rhinitis can cause moderate to severe turbinde destruction and formation of fungal granulomas (Figs. 4 and 5). Dogs with nasal aspergillosis frequently have copious, thick nasal discharge which can obscure the presence of granulomas. CT is superior to radiography for identification of unilateral versus bilateral nasal cavity disease and to define the extension of lesions into adjacent structures. The most commonly encountered CT findings in a recent study were moderate to severe cavitory destruction of the turbinates with



**Figure 5** Computed tomography of a dog with nasal aspergillosis. The reader should note the amorphous soft tissue present in the left frontal sinus. There is no evidence of cribriform plate destruction.

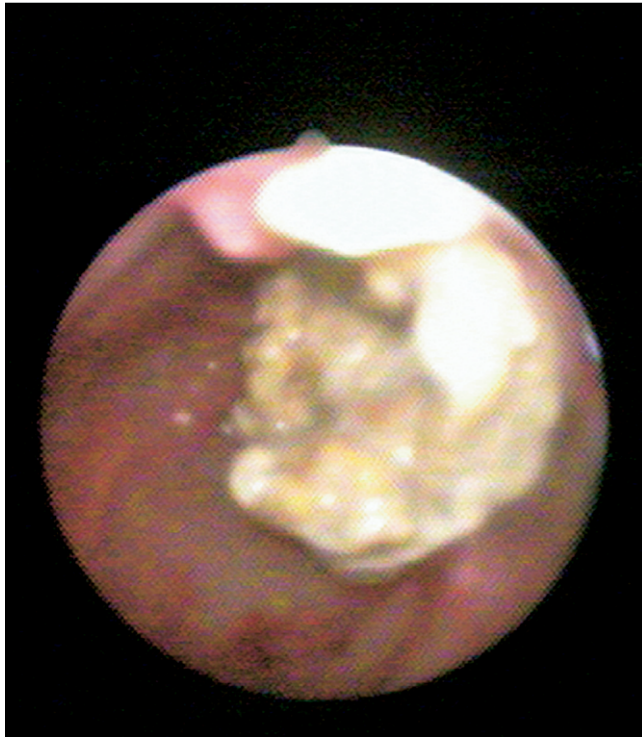

**Figure 6** Before rhinoscopic evaluation, the distance from the rostral nares to the ipsilateral medial canthus should be measured. (Color version of figure is available online.)

the presence of a variable amount of abnormal soft tissue in the nasal passages, nonspecific thickening of the nasal mucosa adjacent to the inner surface of bones of the frontal sinus, maxillary recess and nasal cavity, thickened reactive bone (hyperostosis), and in some instances, gross bony destruction.<sup>7</sup> It also allows assessment of the integrity of the cribriform plate, which is important to determine before topical treatment of nasal aspergillosis.

After obtaining skull radiographs or CT, a visual assessment of the nasal cavity and nasopharynx should be done.<sup>8</sup> Rhinoscopy is an important part of both diagnosis and therapy for nasal aspergillosis. Rhinoscopy allows visualization of a mass lesion or destruction of the nasal turbinates, and placement of a biopsy instrument at the area of interest. It also allows the clinician to visualize and remove foreign bodies (eg, foxtail), which also may be present and contributory in cases of canine aspergillosis. Before rhinoscopic evaluation, the external surface of the nasal cavity is visually and digitally examined for evidence of swelling, asymmetry, and ulceration. The rhinoscope should be measured from the nasal planum to the ipsilateral medial canthus and marked with a piece of tape before inserting the instrument in the nasal cavity (Fig. 6). This distance should not be exceeded or penetration of the cribriform plate may result. The clinician should also measure the distance from the nares to the area of interest noted on the nasal radiographs or CT. Anterior or rostral rhinoscopy while the animal is in sternal recumbency can be attempted with a simple otoscope, although only a very limited examination is possible. A rigid arthroscope [1.9 to 2.7 mm outside diameter and 5 to 25° angle of view (Richard Wolf Medical Instruments Corporation, Rosemont, IL); 2.7 mm × 18.75 cm outside diameter and 0 to 30° with an operating sheath and 2.0-mm channel (Endoscopy Support Services Incorporated, Brewster, NY)] or small diameter flexible bronchoscope [3.8 to 5.0 mm outside diameter (Olympus Corporation, Lake Success, NY)] may be used for a more comprehensive evaluation of the nasal passages. The least affected side should be evaluated first. For posterior rhinoscopy, an angled dental mirror may provide some visualization of the nasopharynx, although the best assessment is made by retroflexing a small flexible fiber-optic endoscope over the soft palate. Placement of large laparotomy sponges in





**Figure 7** Fungal granuloma in the frontal sinus of a dog with nasal aspergillosis. (Color version of figure is available online.)

the pharynx for further protection of the airways is then done. Visualization of fungal plaques on the nasal mucosa with biopsy of these lesions confirms the diagnosis of aspergillosis by detection of fungal hyphae on histopathology. Fungal plaques appear as a white, yellow, or light-green mold lying on the mucosa (Fig. 7). Saline may be forcefully injected through the nasal cavity to wash out obscuring material for better evaluation of the nasal cavities. It is important to biopsy the plaque itself, since surrounding nasal tissue may be characterized by lymphoplasmacytic or neutrophilic rhinitis. The definitive diagnosis of nasal aspergillosis requires microscopic demonstration of hyphal invasion within nasal biopsies. A working channel to the rhinoscope or bronchoscope greatly facilitates the biopsy of plaques. Endoscopic cup forceps may be used during rhinoscopy to obtain biopsy under direct visualization (Fig. 8). Biopsy instruments should never be inserted beyond the level of the ipsilateral medial canthus. Other causes of nasal disease such as an oronasal fistula, foreign bodies, and chronic lymphoplasmacytic rhinitis do not usually produce the degree of turbinate destruction seen in nasal aspergillosis or nasal neoplasia. Following imaging and rhinoscopy, a complete oral examination including periodontal probing is important.

## Canine Sinonasal Aspergillosis

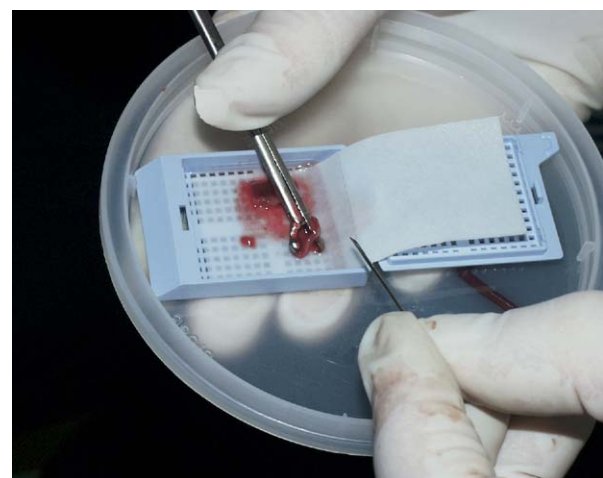
Canine sinonasal aspergillosis results from colonization and invasion of the nasal passages and frontal sinuses by the saprophytic fungus, *A. fumigatus*. Host immunocompetence is an important determinant in the development of this opportunistic fungal infection. Colonization and invasion of the nasal mucosa by *A. fumigatus* causes a destructive rhinitis often accompanied by frontal sinus osteomyelitis presumably

due to an endotoxin responsible for the turbinate necrosis.<sup>9</sup> It is a relatively common disease in dogs. *A. fumigatus* is the most common species encountered in nasal infection. This saprophytic fungus that is ubiquitous in the environment is spread via aerolization of small spores found in vegetative decaying soil and water. Aspergillus is a common contaminant of mucosal surfaces and the respiratory tract, so that culture without histologic or cytologic evidence of inflammation associated with invasion is not diagnostic. This opportunistic pathogen usually remains confined to the nasal cavity and paranasal sinus, causing marked destruction of turbinate mucosa and bone, although it may invade the periorbital soft-tissue structures and/or the cranial vault. Nasal aspergillosis is usually seen in dolichocephalic and mesocephalic dogs and is very rare in brachycephalic breeds. German Shepherds and Rottweilers are the commonly affected breeds. Dogs of any age may be affected, but approximately 40% are 3 years or younger and 80% are 7 years or younger.<sup>10</sup>

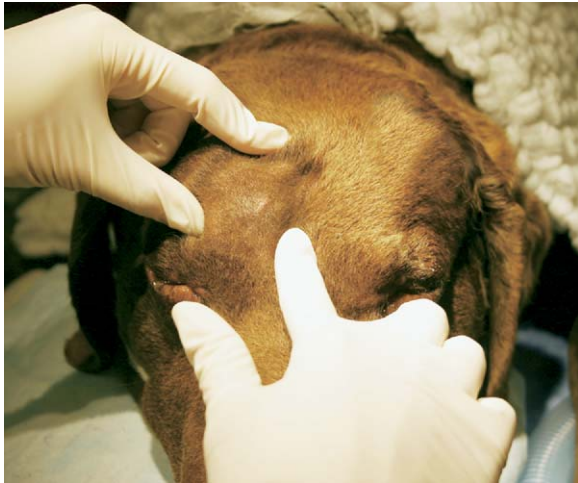The three hallmarks of canine nasal aspergillosis are a profuse mucoid to hemorrhagic chronic nasal discharge that may alternate with periods of epistaxis, ulceration of the external nares with crusting, and pain or discomfort in the facial region. Some dogs with infections restricted to the frontal sinus do not show nasal discharge or nasal ulceration.

## Therapeutic Approach to Canine Sinonasal Aspergillosis

In cases where only the sinuses are involved, trephination is recommended to confirm the presence of fungal infection and to facilitate debridement and topical treatment. Landmarks for sinus trephination include the orbital rim ventrally, the zygomatic process of the frontal bone laterally, and the midline of the skull medially. The frontal sinus is entered in the center of the triangle bordered by these landmarks (Fig. 9). Trephination is most easily done with a large (5/32 inch) nongrooved Steinmann pin and a bone chuck. The Steinmann pin should protrude only 1 to 2 cm from the bone chuck to avoid excessive penetration of the skull during trephination (Fig. 10). Plaques within the frontal sinus can be



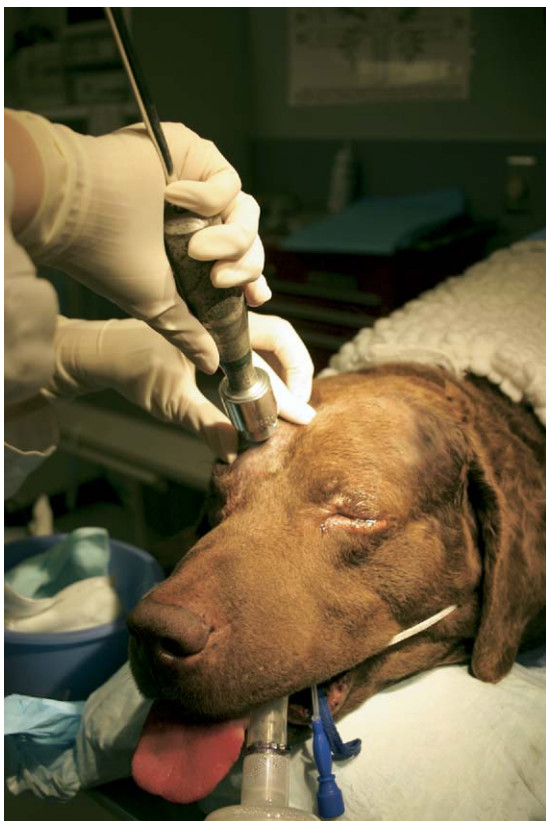**Figure 8** Nasal biopsies obtained during rhinoscopy under direct visualization. (Color version of figure is available online.)



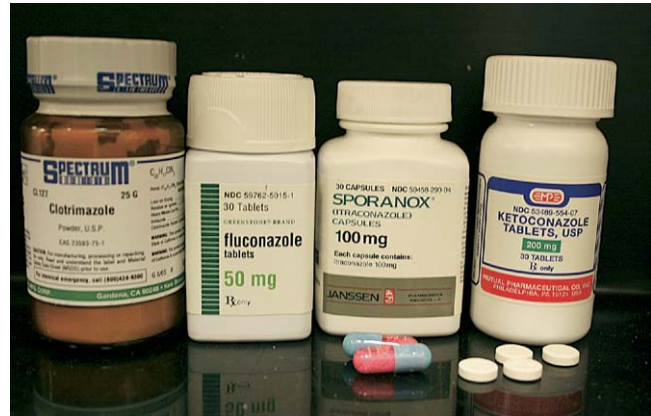**Figure 9** Landmarks for sinus trephination include the orbital rim ventrally, the zygomatic process of the frontal bone laterally, and the midline of the skull medially. The frontal sinus is entered in the center of the triangle bordered by these landmarks. (Color version of figure is available online.)

identified by introducing an endoscope through the trephine hole in the frontal bone.

Therapeutic recommendations for sinonasal aspergillosis have included surgery and several systemic and topical antifungal drugs (Fig. 11). If local therapy for *Aspergillus* is possible following assessment of an intact cribriform plate, top-



**Figure 10** Trephination is most easily done with a large (5/32 inch) nongrooved Steinmann pin and a bone chuck. The Steinmann pin should protrude only 1 to 2 cm from the bone chuck to avoid excessive penetration of the skull during trephination. (Color version of figure is available online.)



**Figure 11** A few antifungal drugs that have been used in the treatment of nasal aspergillosis. (Color version of figure is available online.)

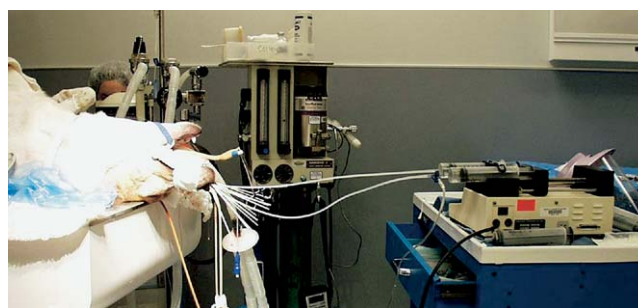
ical administration of antifungal solution infused through catheters should be considered. Topical administration of enilconazole or clotrimazole is more effective than orally administered antifungal medications.<sup>11-15</sup> For several years, the standard treatment for nasal aspergillosis was an enilconazole emulsion delivered via tubes surgically implanted into the nasal chambers and frontal sinuses.<sup>13</sup> This approach reportedly resulted in the elimination of the fungal rhinitis in more than 90% of affected dogs, but it had several disadvantages. The twice daily irrigation of enilconazole at a dosage of 10 mg/kg for 7 to 10 days was labor intensive, not always well tolerated by the dog, and was complicated if the dog removed one or both tubes. Using this technique, nasal discharge resolved in 19 of 24 (80%) dogs treated solely with topical administration of enilconazole.<sup>13</sup> Enilconazole is ideal as a topical agent because it is also active in the vapor phase, which enhances its distribution throughout the nasal chamber.<sup>13</sup> Enilconazole has also been used through nonsurgically placed catheters. Enilconazole was administered after endoscopic placement of lavage tubes in the caudal portion of the nasal cavity and frontal sinuses.<sup>16</sup> Enilconazole was prepared by diluting the commercial grade product with sterile water to achieve a final concentration of 5%. Volume of enilconazole administered under general anesthesia varied between 50 and 200 mL and was determined on the basis of endoscopic evaluation during application. The dogs received two or three treatments with each one lasting 45 to 60 minutes. All the dogs showed favorable clinical response soon after treatment. Immediate post-treatment adverse effects, including serosanguineous nasal discharge, salivation, vomiting, and mild oral ulceration, resolved within 24 hours. Three of the six dogs were followed for a mean of 16.5 months and had marked clinical improvement.

The distribution of topical agents after noninvasive infusion via the external nares has been evaluated in both normal dog skulls and dogs with fungal rhinitis.<sup>17,18</sup> The volume of the nasal cavity and frontal sinuses depends on the size of the dog, extent of turbinate destruction, and volume of accumulated exudate. On the basis of a study on cadavers, the average volume of frontal sinuses in breeds predisposed to fungal rhinitis was 25 mL per side.<sup>17</sup> The nasal cavity and frontal sinuses can be flooded with a larger volume of infusate (50 or



60 mL per side), which results in distribution of infusate to all affected areas. At present, the recommendation is to use 50 to 60 mL per side in middle- to large-breed dogs, regardless of head size. A recent study determined effectiveness of infusion of 1 and 2% enilconazole for treatment of nasal and sinusal canine aspergillosis, respectively. Nineteen dogs were treated with 1% enilconazole by use of a modified noninvasive infusion procedure. Seven dogs were treated with 2% enilconazole via catheters that were placed via endoscopic guidance into the frontal sinuses. After extensive rhinoscopic debridement, 1 and 2% enilconazole infused into the nasal cavities and the frontal sinuses, respectively, were effective for treatment of aspergillosis in dogs, although intrasinus administration via endoscopically placed catheters appeared to require fewer infusions for success.<sup>19</sup> In another report, enilconazole has been used as a 1-hour infusion, but has produced disappointing results.<sup>20</sup> No dogs were cured by this treatment and three even appeared to be worse.

More recently, a noninvasive technique using nonsurgically placed catheters has been developed based on studies of the distribution of topical agents in the frontal sinuses and nasal passages to infuse a 1% solution of clotrimazole under general anesthesia.<sup>14-19,21</sup> Clotrimazole is a synthetic imidazole derivative. Clotrimazole is fungicidal topically, reaching higher concentrations than during systemic use. Electron microscopic observations indicate that, at high concentrations, clotrimazole causes alteration in the fungal cell membrane with consequent changes in permeability and leakage of cellular constituents. This drug is available in human topical preparations for cutaneous, oral, or vaginal applications. A 24-Fr Foley catheter is inserted into the caudal nasopharynx with the dog in lateral recumbency so that the catheter lays dorsal to the soft palate. The balloon of the Foley catheter is then inflated to occlude the nasopharynx. The balloon should be palpated through the soft palate to confirm its position just caudal to the hard palate. Moistened laparotomy sponges are placed in the pharynx so that the catheter cannot migrate caudally and will absorb any infusate that might escape around the balloon. A 10-Fr polypropylene catheter is inserted into each rostral nasal cavity for drug delivery and advanced into the dorsal nasal meatus to the level of the medial canthus of the ipsilateral palpebral fissure. A 12-Fr Foley catheter is inserted into each nostril and balloons are inflated and positioned just caudal to and occluding the nostrils. An additional sponge is placed just caudal to the upper incisors (between the endotracheal tube and the incisive papilla) to absorb leakage of clotrimazole through the incisive ducts. Approximately 50 mL of solution is inserted into each nasal cavity with continuous infusion pumps over 1 hour with the animal in dorsal recumbency. Initially, the nasal passages and frontal sinuses must be filled with solution. When clotrimazole is noted within the lumen of a Foley catheter, it should be clamped shut. The dog's head is then rotated 90° every 15 minutes to insure coating of the nasal cavity (dorsal, left lateral, right lateral, dorsal recumbency). Cotton-tipped applicators can be used to prevent extrusion of the antifungal solution during application (Fig. 12). Positioning the dog so that its nose protrudes beyond the edge of the treatment table allows clotrimazole escaping around the nasal catheters to drip into a receptacle. Catheters are flushed with saline before removal. The medication is then drained



**Figure 12** Noninvasive technique using nonsurgically placed catheters in the nasal passages under general anesthesia. (Color version of figure is available online.)

from the nasal cavity with the dog in sternal recumbency and its head tilted ventrally after removing rostral catheters and sponges. The pharynx and proximal esophagus are suctioned before recovery from anesthesia, and the 24-Fr Foley catheter is removed. This treatment is usually well tolerated. Adverse reactions to this treatment have been described and include severe pharyngeal inflammation and edema, probably a result of the vehicles present in the clotrimazole formulation (polyethylene or propylene glycol and isopropyl alcohol). Prolonged recovery from anesthesia, possibly resulting from systemic absorption of clotrimazole and subsequent hepatic microsomal enzyme inhibition, was theorized in one report.<sup>22</sup> Another potential risk includes extension of drug to the brain across a damaged cribriform plate, detrimental due to vehicle-induced meningitis. Topical infusion of clotrimazole solution is not advised if the cribriform plate is not intact, because serious meningitis and encephalitis may result.

In a study designed to evaluate the clinical response to topical administration of clotrimazole solution infused through catheters placed by use of surgical versus nonsurgical techniques in dogs with nasal aspergillosis, it was found that topical administration of clotrimazole using either technique is an effective treatment for nasal aspergillosis.<sup>15</sup> Topical administration of clotrimazole resulted in this retrospective study in resolution of clinical disease in 65% of dogs after one treatment and 87% of dogs after one or more treatments. In a comparison study between surgical and intranasal administration of clotrimazole to 11 dogs, the noninvasive method (intranasal) was more effective, purportedly because of better coverage of all affected mucosal surfaces.<sup>23</sup> Topical therapy with itraconazole oral suspension in refractory cases is currently under clinical investigation.

If local therapy for *Aspergillus* is not possible because the cribriform plate has lost integrity, or has failed to resolve the infection, various systemic antifungal drugs may be administered. Oral ketoconazole was reportedly efficacious in 47%, oral itraconazole in 60 to 70%, and oral fluconazole in 60% of infected dogs.<sup>11,12,16,24</sup> The systemic administration of antifungal agents requires prolonged medication due to their poor efficacy and is expensive. Voriconazole (Vfend®, Pfizer, New York, NY), a new generation triazole (fluconazole derivative), has recently gained FDA approval and is available to veterinarians. Voriconazole holds promise for refractory cases of nasal aspergillosis. Unfortunately, its high cost makes it unlikely to be used extensively in veterinary patients. Itra-

conazole may be administered at 5 mg/kg orally twice daily (given with food) for 2 to 6 months. Ketoconazole and itraconazole undergo hepatic metabolism and can be associated with hepatotoxicity. Liver enzymes should be monitored with these drugs. Other side effects include gastrointestinal intolerance and cutaneous reactions. A local ulcerative dermatitis due to a cutaneous vasculitis usually resolves shortly after itraconazole is discontinued. Itraconazole has recently become available as an oral solution in a  $\beta$ -cyclodextrin carrier that improves absorption and bioavailability, allowing higher concentrations in affected tissues. Experience suggests that turbinectomy is of no benefit in controlling the nasal discharges and is often invasive and detrimental.<sup>13</sup>

For dogs that are confirmed to be free of fungus at the end of antifungal drug therapy, the long-term prognosis seems to be good after treatment. Rhinoscopic evaluation of the sinonasal passages and follow-up CT are the best methods to evaluate efficacy of therapy. Positive titers may persist for more than 2 years (ELISA) or 5 years (AGID) in dogs that remain free of disease.<sup>10</sup> Treatment failure may result from resistance to antifungal drug, poor penetration into affected tissues of a systemic drug, presence of a foreign body, fungal granuloma or sequestrum, immunosuppression, failure to coat the entire nasal cavity with a topical drug, or an incorrect diagnosis.

## References

1. Tasker S, Knottenbelt CM, Munro EA, et al: Aetiology and diagnosis of persistent nasal disease in the dog: a retrospective study of 42 cases. *J Small Anim Pract* 40:473-478, 1999
2. Sharp NJH: Canine nasal aspergillosis-penicilliosis, in Greene CE (ed): *Infectious Diseases of the Dog and Cat* (ed 2). Philadelphia, PA, Saunders, 1998, pp 404-413
3. Lane JG, Warnock DW: The diagnosis of *Aspergillus fumigatus* infection of the nasal chambers of the dog with particular reference to the value of the double diffusion test. *J Small Anim Pract* 18:169-177, 1977
4. Harvey CE, O'Brien JA: Nasal aspergillosis-penicilliosis, in Kirk RW (ed): *Current Veterinary Therapy VIII*. Philadelphia, PA, Saunders, 1983, pp 236-240
5. Saunders JH, van Bree H: Comparison of radiography and computed tomography for the diagnosis of canine nasal aspergillosis. *Vet Radiol Ultrasound* 44:414-419, 2003
6. Saunders JH, Clercx C, Snaps FR, et al: Radiographic, magnetic resonance imaging, computed tomographic, and rhinoscopic features of nasal aspergillosis in dogs. *J Am Vet Med Assoc* 11:1217-1221, 2004
7. Saunders JH, Zonderland JL, Clercx C, et al: Computed tomographic findings in 35 dogs with nasal aspergillosis. *Vet Radiol Ultrasound* 43:5-9, 2002
8. Willard MD, Radlinsky MA: Endoscopic examination of the choanae in dogs and cats: 118 cases (1988-1998). *J Am Vet Med Assoc* 215:1301-1305, 1999
9. Tilden EB, Hatton EH, Freeman S, et al: Preparation and properties of the endotoxins of *Aspergillus fumigatus* and *Aspergillus flavus*. *Mycopathol Mycol Appl* 14:325-346, 1961
10. Sharp NJH, Harvey CE, Sullivan M: Canine nasal aspergillosis/penicilliosis. *Compend Cont Educ Pract Vet* 13:41-49, 1991
11. Sharp NJH, Sullivan M: Use of ketoconazole in the treatment of canine nasal aspergillosis. *J Am Vet Med Assoc* 194:782-786, 1989
12. Sharp NJH, Harvey CE, O'Brien JA: Treatment of canine nasal aspergillosis/penicilliosis with fluconazole. *J Small Anim Pract* 32:513-516, 1991
13. Sharp NJH, Sullivan M, Harvey CE, et al: Treatment of nasal aspergillosis with enilconazole. *J Vet Intern Med* 7:40-43, 1993
14. Davidson AP, Pappagianis D: Treatment of nasal aspergillosis with topical clotrimazole, in Bonagura JD (ed): *Kirk's Current Veterinary Therapy XII Small Animal Practice*. Philadelphia, PA, Saunders, 1995, pp 899-901
15. Mathews KG, Davidson AP, Koblik PD, et al: Comparison of topical administration of clotrimazole through surgically placed versus non-surgically placed catheters for treatment of nasal aspergillosis in dogs: 60 cases (1990-1996). *J Am Vet Med Assoc* 213:501-506, 1998
16. Mc Cullough SH, McKiernan BC, Brodsky BS: Endoscopically placed tubes for administration of enilconazole for treatment of nasal aspergillosis in dogs. *J Am Vet Med Assoc* 212:67, 1998
17. Mathews KG, Koblik PD, Richardson EF, et al: Computed tomographic assessment of noninvasive intranasal infusions in dogs with fungal rhinitis. *Vet Surg* 25:309-319, 1996
18. Richardson EF, Mathews KG: Distribution of topical agents in the frontal sinuses and nasal cavity of dogs: comparison between current protocols for treatment of nasal aspergillosis and a new noninvasive technique. *Vet Surg* 24:476-483, 1995
19. Zonderland JL, Störk CK, Saunders JH, et al: Intranasal infusion of enilconazole for treatment of sinonasal aspergillosis in dogs. *J Am Vet Med Assoc* 221:1421-1425, 2002
20. Bray JP, White RAS, Lascelles BD: Treatment of canine nasal aspergillosis with a new non-invasive technique. Failure with enilconazole. *J Small Anim Pract* 39:223-226, 1998
21. Davidson AP, Mathews KG: Nasal aspergillosis: Treatment with clotrimazole. *J Am Anim Hosp Assoc* 33:475, 1997
22. Caulkett N, Lew L, Fries C: Upper-airway obstruction and prolonged recovery from anesthesia following intranasal clotrimazole administration. *J Am Anim Hosp Assoc* 33:264-267, 1997
23. Burbidge HM, Clark WT, Read R, et al: Canine nasal aspergillosis. Results of treatment using clotrimazole as a topical agent. *Aust Vet Pract* 27:79, 1997
24. Sharp NJH, Burrell MH, Sullivan M, et al: Canine nasal aspergillosis: serology and treatment with ketoconazole. *J Small Anim Pract* 25:149-158, 1984