

Fluorescein-conjugated Lectin Visualization of Fungi and Acanthamoebae in Infectious Keratitis

JEFFREY B. ROBIN, MD,^{1,2} ROGER CHAN, BS,¹ NARSING A. RAO, MD,³
SAVITRI SHARMA, MD,⁴ M. SRINIVASAN, MD⁴

Abstract: The authors investigated the efficacy of two fluorescein-conjugated lectins (FCLs), concanavalin A (F-ConA) and wheat germ agglutinin (F-WGA), to visualize microorganisms from clinical specimens with documented mycotic and acanthamoebic keratitis. Corneal scrapings from 18 patients with culture-proven keratomycosis and deparaffinized histopathologic specimens from five culture-proven cases of acanthamoebic keratitis were evaluated. The F-ConA provided consistently bright staining of the mycotic structures in each of the corneal scrapings. Both F-ConA and F-WGA stained acanthamoebic trophozoites and cysts in the histopathologic specimens. In both the corneal scrapings and the histopathologic specimens, the microorganisms were easily differentiated from background corneal cells and tissue. These staining patterns correlate well with the results from experimental studies, and with the known cell wall carbohydrate compositions for fungi and acanthamoebae. This study provides further evidence that FCLs (particularly F-ConA) may eventually become effective first-line stains for the visualization of microorganisms in specimens from ocular infections. *Ophthalmology* 96:1198-1202, 1989

Originally received: December 27, 1988.
Revision accepted: February 23, 1989.

¹ UIC Eye Center, University of Illinois College of Medicine at Chicago, Chicago.

² West Side Veterans Administration Medical Center, Chicago.

³ Doheny Eye Institute, University of Southern California School of Medicine, Los Angeles.

⁴ Aravind Eye Hospital, Madurai, India.

Presented as a poster at the American Academy of Ophthalmology Annual Meeting, Las Vegas, October 1988.

Supported in part by a grant from the Veterans Administration Research Service, Washington, DC (Dr. Robin); a grant from the Illinois Society for the Prevention of Blindness, Chicago (Dr. Robin) and training grant EY 7038 and core grant 1792 from the National Eye Institute, Bethesda, Maryland (UIC Eye Center).

The authors and their principal relatives do not have any financial or proprietary interests in any of the products or companies mentioned in this article.

Reprint requests to Jeffrey B. Robin, MD, UIC Eye Center, 1855 West Taylor St, Chicago, IL 60612.

The incidence of uncommon corneal infections, such as those caused by fungi and acanthamoebae, has been increasing in recent years. Factors that may contribute to this phenomenon include the use of topical corticosteroids, soft contact lens wear, and heightened clinical suspicion.¹⁻⁴ Successful treatment of these potentially serious ophthalmic infections is predicated upon early diagnosis and rapid institution of appropriate therapy. Frequently, the indolent nature and lack of pathognomonic clinical signs associated with these infections may delay the diagnosis. Successful growth of fungi or parasites in culture may require several days or weeks thereby necessitating the use of staining techniques in order to establish the identity of the infecting organism. The techniques that have been used to visualize fungi or acanthamoebae include potassium hydroxide wet mount, Giemsa, periodic acid-Schiff (PAS), Mallory trichrome, and Gomori methenamine silver (GMS).^{5,6} They may require special expertise and take several hours to perform. Additionally, published series using these techniques have documented variable efficacy.⁷⁻¹¹

Table 1. Fungal Keratitis Cases

Patient No.	Clinical History	Fungal Species
1	22-yr-old man; 10-day history; no trauma	<i>Fusarium solani</i>
2	50-yr-old man; 8-day history; no trauma	Unidentified
3	65-yr-old man; 12-day history; no trauma	Unidentified
4	60-yr-old man; 45-day history; no trauma	<i>Aspergillus fumigatus</i>
5	50-yr-old woman; eye injury with vegetable matter	<i>A. fumigatus</i>
6	18-yr-old man; 7-day history; no trauma	<i>F. solani</i>
7	59-yr-old man; immunosuppressed	<i>Aspergillus</i> sp
8	55-yr-old woman; unknown course	<i>Dreschlera</i> sp
9	45-yr-old man; unknown course	<i>Fusarium</i> <i>soseum</i>
10	11-yr-old man; unknown course	<i>F. solani</i>
11	28-yr-old man; unknown course	<i>F. solani</i>
12	47-yr-old woman; unknown course	<i>F. solani</i>
13	18-yr-old man; unknown course	<i>F. soseum</i>
14	NA	<i>Aspergillus flavus</i>
15	NA	<i>Fusarium</i> sp
16	NA	<i>Fusarium</i> sp
17	NA	<i>Fusarium</i> sp
18	NA	Unidentified

NA = not available.

We recently demonstrated, using experimental models of mycotic¹² and acanthamoebic¹³ ocular infections, that the use of fluorescein-conjugated lectins (FCLs) is effective in providing rapid visualization of these organisms. Additionally, we successfully used this technique to visualize several species of bacteria¹⁴ and atypical mycobacteria.¹⁵ To further evaluate the efficacy of FCLs in enabling rapid visualization of infectious microorganisms, we report our experience using FCLs to stain corneal specimens from documented clinical cases of mycotic or acanthamoebic keratitis.

MATERIALS AND METHODS

CLINICAL SPECIMENS

Corneal scrapings from 18 patients with mycotic keratitis were obtained from the Aravind Eye Hospital, Madurai, India, and from the UIC Eye Center, Chicago, during the period between June 1987 and August 1988. Relevant clinical histories, when available, were provided along with the culture results (Table 1). Each specimen slide was air dried and subsequently fixed in 95% cold ethanol for 5 minutes.

Slides of paraffin-embedded histopathologic sections from five culture-proven cases of acanthamoebic keratitis were obtained from the UIC Eye Center, the Doheny Eye Institute, and the University of Chicago. The specimens were first deparaffinized by immersion in xylene for 10

minutes. This was followed by rapid dehydration in a series of graded alcohols. The deparaffinized slides were rinsed in distilled water for several minutes followed by immersion in TRIS buffer. They were subsequently air dried and fixed for 5 minutes in 95% ethanol.

FLUORESCCEIN-CONJUGATED LECTIN-BINDING TECHNIQUE

For FCL binding, a previously described technique¹³ was slightly modified. Fluorescein-conjugated concanavalin A (F-ConA) and fluorescein-conjugated wheat germ agglutinin (F-WGA) (Vector Laboratories, Burlingame, CA) were used in this study. The F-ConA was used in the fungal keratitis cases, and both F-ConA and F-WGA were used in the acanthamoebic keratitis cases.

Essentially, 5 μ l of the FCL (stock concentration, 2 mg/ml) was diluted to a concentration of 0.02 mg/ml by mixing with 495 μ l of TRIS buffer. Each fixed specimen slide was incubated with a solution of TRIS and bovine serum albumin for 5 minutes. The slides were drained of excess buffer and then rinsed with TRIS alone. The specimens were subsequently placed in a dark humidified chamber for 20 minutes at room temperature. At the end of the incubation period, the slides were rinsed with TRIS, and glass coverslips were mounted using an aqueous, nonfluorescing mounting medium (Immu-Mount, Shandon, Sewickley, PA). The slides were examined using an epifluorescence microscope (Leitz, Wetzlar, West Germany), and photographs were taken with an attached camera (Olympus, Lake Success, NY) OM-2 camera using 800/1600 ASA film, exposure index 1600.

FLUORESCCEIN-CONJUGATED LECTIN-BINDING CONTROL STUDIES

When additional specimens were available, both positive and negative control studies were done. Positive controls consisted of incubating slides with a mixture of the FCL and its known corresponding blocking sugar (0.5 M methyl- α -mannopyranoside for F-ConA¹⁶ and 0.5 M N-acetyl-D-glucosamine for F-WGA¹⁷). Negative controls consisted of incubating specimens with a solution of the FCL and a nonspecific blocking sugar (0.5 M α -L-fucose). Each stock sugar was from Sigma (St. Louis, MO).

For the acanthamoebic keratitis cases, additional specimens were incubated with calcofluor white (CFW) (Polysciences, Warrington, PA), according to a previously described protocol¹⁸ to confirm the presence of acanthamoebic cysts. Also, fixed histopathologic slides of normal human corneal specimens (provided by MOM Tso, MD, Chicago, IL) were similarly deparaffinized, processed, and stained with both FCLs to evaluate the degree of non-specific background staining.

RESULTS

FUNGAL KERATITIS

The F-ConA incubation with the corneal scraping specimens from the 18 cases of mycotic keratitis provided

rapid, definitive, and consistent visualization of mycotic structures. The organisms were easily differentiated from background cells and tissue. Hyphae, yeasts and sporulating forms were readily demonstrated (Figs 1, 2). The brightest degree of staining was confined to the mycotic cell walls. Positive-control studies showed diminution of the degree of fungal staining by the addition of methyl- α -D-mannopyranoside to the specimen before incubation with F-ConA. Negative-control slides from the infected corneas had no decrease in staining intensity.

ACANTHAMOEBC KERATITIS

Both F-ConA and F-WGA produced distinct and bright staining of acanthamoebic cysts and trophozoites. Incubation of specimens with F-ConA intensely stained both cysts and trophozoites (Figs 3, 4), and incubation with F-WGA produced bright staining of cysts and moderate staining of trophozoites. In all of the experimental slides, the organisms were easily differentiated from background cells and tissue. For both F-ConA and F-WGA, positive-control studies showed marked diminution in staining intensity, but negative-control studies revealed no reduced staining intensity. The CFW staining of the corneal specimens from infected cases confirmed the presence of acanthamoebic cysts (Fig 5).

CONTROL STUDIES

Both positive and negative controls for F-ConA and F-WGA confirmed that the observed microorganism staining in the experimental specimens was the result of binding of the FCL to the appropriate carbohydrate in the microbial cell wall. Incubation of either FCL with specimens of normal cornea produced minimal staining of corneal cells and tissues.

DISCUSSION

Recent experience emphasizes that rapid identification of the offending organism is a prerequisite for the effective medical therapy of corneal infections. This is particularly true for infections caused by fungi or acanthamoebae. In addition to the need for special media, these organisms may require several days to grow in culture. "Routine" microbiologic staining techniques (e.g., Gram and Giemsa stains) are not specific enough to differentiate stained organisms from background corneal and inflammatory cells easily. Fixed-tissue stains (e.g., hematoxylin-eosin, PAS, and GMS) may cause similar difficulties. Additionally, they may require special expertise and time to perform. Therefore a search for rapid diagnostic techniques that can effectively enable visualization of several classes of microorganisms has begun.

Recently, two staining techniques have been introduced, specifically for the rapid diagnosis of acanthamoebic keratitis. Calcofluor white is a laundry brightener that binds to polymers of beta-linked polysaccharides, particularly cellulose and chitin.^{18,19} Cellulose is a major com-

ponent of the cell wall of the acanthamoebic cyst²⁰; several studies have confirmed the ability of CFW to stain this stage of the organism.^{18,21} However, CFW's inability to stain the trophozoite stage may be a realistic limitation to its efficacy.

The use of indirect immunofluorescent antibodies to acanthamoebae is another recently described, rapid staining technique.²² These agents, although more specific than CFW, are not readily available. Similar efforts have been made to rapidly diagnose the presence of fungi in ophthalmic specimens. The CFW, because of the chitin present in hyphal cell walls, has also been used successfully to visualize mycotic hyphae.^{18,19,23}

Lectins are ubiquitous glycoproteins with the unique property to bind to specific carbohydrate moieties.¹⁵ When conjugated to either visible dyes or electron-dense substances, lectin-bound carbohydrate groups can be visualized using light, fluorescence, or electron microscopy. In ophthalmology, lectins have been used for many purposes, ranging from the identification of sugar residues in corneal dystrophies to the biochemical characterization of retinal photoreceptor cells.^{24,25} Additionally, using known microbial cell wall/membrane sugar compositions, dye-conjugated lectins have been used to identify microorganisms both in culture and in histopathologic specimens.²⁶

In previous studies,¹²⁻¹⁴ using known carbohydrate compositions of fungi and acanthamoebae, we were able to determine lectin binding patterns for several species of these microorganisms in microbial cultures. These FCL staining patterns were confirmed in experimental models of infectious keratitis caused by these organisms. These studies determined the FCLs selected for this study. For fungi, a panel of FCLs selected to cover a broad spectrum of carbohydrate specificities enabled the rapid visualization, and in some cases differentiation, of 19 species. These studies also determined that the use of F-ConA consistently provided intensely bright staining of all mycotic species tested. This was consistent with the nearly ubiquitous presence of either α -D-mannose or α -D-glucose—the specific carbohydrates for ConA—in mycotic cell walls.²⁷ It was for this reason that we selected F-ConA for the visualization of fungi in this study. Similarly, in a recent study¹³ of FCL staining of four species of acanthamoebae, we determined that both F-ConA and F-WGA produced the brightest degree of staining. Again, this staining pattern appeared to be consistent with known cell wall carbohydrate concentrations of both the cyst and trophozoite forms of *Acanthamoeba*.²⁸⁻³⁰ It was for this reason that we selected these two FCLs for the acanthamoebic keratitis specimens.

In this retrospective study, corneal specimens from 18 cases of culture-proven mycotic keratitis and five cases of culture-proven acanthamoebic keratitis were incubated with F-ConA and/or F-WGA. The FCL binding technique is rapid, regardless of whether the specimen was from a corneal scraping or a previously paraffinized histopathologic section. The effectiveness of F-ConA in visualizing both fungi and acanthamoebae was clearly demonstrated. For the fungal keratitis specimens, hyphae, pseudohyphae,

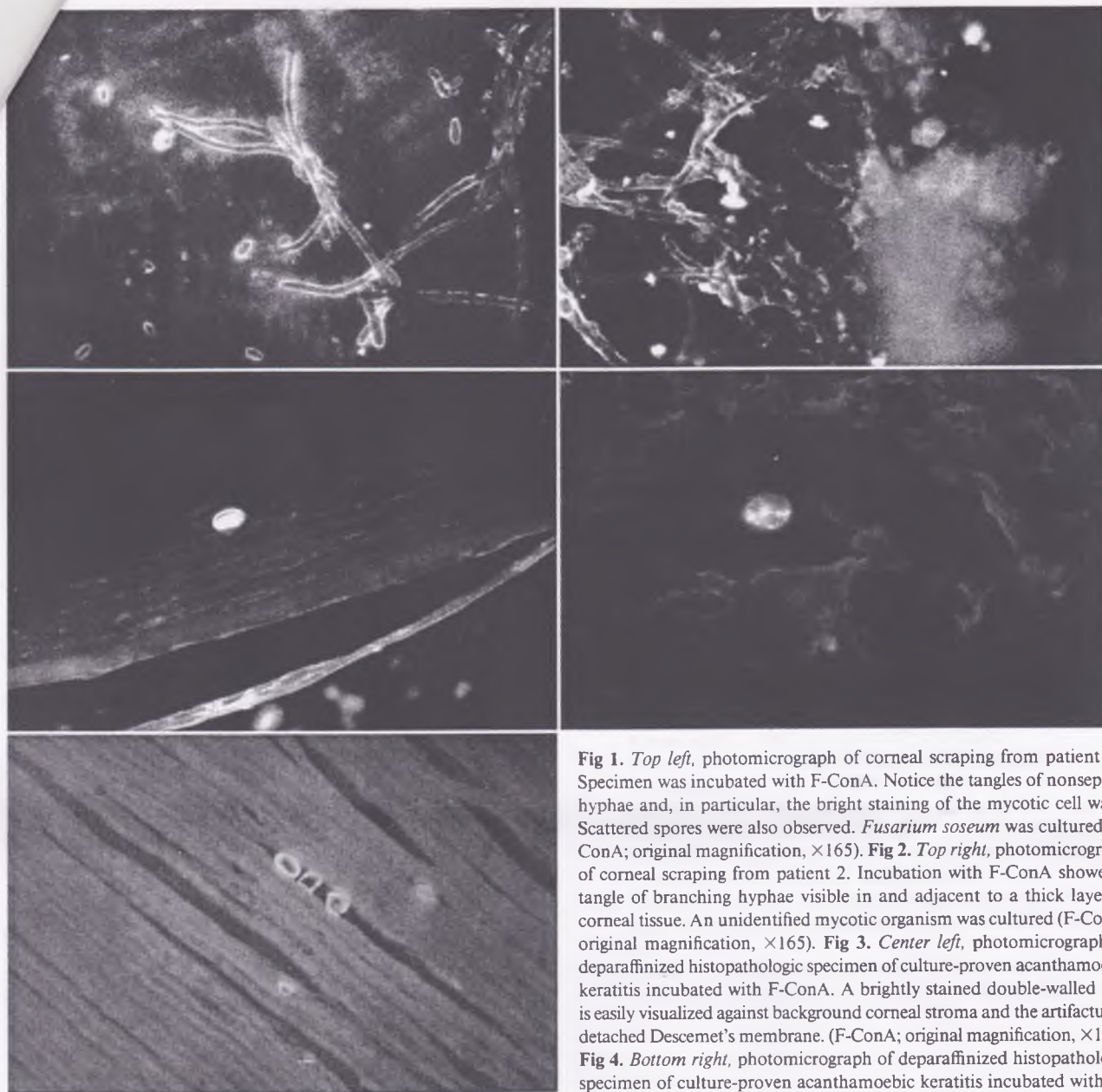


Fig 1. *Top left*, photomicrograph of corneal scraping from patient 13. Specimen was incubated with F-ConA. Notice the tangles of nonseptate hyphae and, in particular, the bright staining of the mycotic cell walls. Scattered spores were also observed. *Fusarium roseum* was cultured (F-ConA; original magnification, $\times 165$). **Fig 2.** *Top right*, photomicrograph of corneal scraping from patient 2. Incubation with F-ConA showed a tangle of branching hyphae visible in and adjacent to a thick layer of corneal tissue. An unidentified mycotic organism was cultured (F-ConA; original magnification, $\times 165$). **Fig 3.** *Center left*, photomicrograph of deparaffinized histopathologic specimen of culture-proven acanthamoebic keratitis incubated with F-ConA. A brightly stained double-walled cyst is easily visualized against background corneal stroma and the artifactually detached Descemet's membrane. (F-ConA; original magnification, $\times 160$). **Fig 4.** *Bottom right*, photomicrograph of deparaffinized histopathologic specimen of culture-proven acanthamoebic keratitis incubated with (F-WGA). A brightly stained trophozoite is visible against the background

corneal stroma. (F-WGA; original magnification, $\times 330$). **Fig 5.** *Bottom left*, photomicrograph of deparaffinized histopathologic specimen of culture-proven acanthamoebic keratitis stained with calcofluor white (CFW). Several cyst-shaped structures are visible in the corneal stroma (CFW; original magnification, $\times 160$).

yeasts, and spores were very bright and were readily visualized. Similarly, for the acanthamoebic keratitis specimens, F-ConA provided very bright staining of cysts and trophozoites. The F-WGA provided bright staining of cysts but only minimal staining of trophozoites. Background staining was, in all cases, minimal and did not interfere with differentiation of mycotic or acanthamoebic structures.

The results from this clinical study are consistent with our previous experimental observations.¹²⁻¹⁴ They support further the hypothesis that the use of FCLs enables rapid visualization of microorganisms in samples of infected

ocular tissue. Additionally, we have now demonstrated that one FCL, F-ConA, is capable of binding to several species of aerobic and anaerobic bacteria, fungi, atypical mycobacteria, and acanthamoebae. This FCL, we believe, may eventually become an effective first-line stain for the visualization of microorganisms in ocular infections.

REFERENCES

1. Forster RK. Fungal diseases. In: Smolin G, Thoft RA, eds. *The Cornea: Scientific Foundation and Clinical Practice*. Boston: Little, Brown, 1983; 168-77.

2. Polack FM, Kaufman HE, Newmark E. Keratomycosis: medical and surgical treatment. *Arch Ophthalmol* 1971; 85:410-6.
3. Moore MB, McCulley JP, Newton C, et al. *Acanthamoeba* keratitis. A growing problem in soft and hard contact lens wearers. *Ophthalmology* 1987; 94:1654-61.
4. Auran JD, Starr MB, Jakobiec FA. *Acanthamoeba* keratitis. A review of the literature. *Cornea* 1987; 6:2-26.
5. Clayton YM. Further diagnostic procedures in fungal infections of the eye. *Trans Ophthalmol Soc UK* 1969; 89:815-8.
6. Forster RK, Wirta MG, Solis M, Rebell G. Methenamine-silver-stained corneal scrapings in keratomycosis. *Am J Ophthalmol* 1976; 82: 261-5.
7. Jones DB, Liesegang TJ, Robinson NM. Laboratory Diagnosis of Ocular Infections. Washington, DC: American Society for Microbiology, 1981; 15. (Cumitech; 13).
8. McClellan KA, Kappagoda NK, Filipic M, et al. Microbiological and histopathological confirmation of acanthamebic keratitis. *Pathology* 1988; 20:70-3.
9. Forster RK, Rebell G. The diagnosis and management of keratomycosis. I. Causes and diagnosis. *Arch Ophthalmol* 1975; 93: 975-8.
10. Arora R, Venkateswarlu K, Mahajan VM. Keratomycosis—a retrospective histopathologic and microbiologic analysis. *Ann Ophthalmol* 1988; 20:306-15.
11. Cohen EJ, Parlato CJ, Arentsen J, et al. Medical and surgical treatment of *Acanthamoeba* keratitis. *Am J Ophthalmol* 1987; 103:615-25.
12. Robin JB, Arffa RC, Avni I, Rao NA. Rapid visualization of three common fungi using fluorescein-conjugated lectins. *Invest Ophthalmol Vis Sci* 1986; 27:500-6.
13. Robin JB, Chan R, Andersen BR. Rapid visualization of *Acanthamoeba* using fluorescein-conjugated lectins. *Arch Ophthalmol* 1988; 106: 1273-6.
14. Robin JB, Schmidt L, Haimov T, et al. Fluorescein-conjugated lectin visualization of infectious organisms. In: Cavanagh HD, ed. *The Cornea: Transactions of the World Congress on the Cornea III*. New York: Raven Press, 1988; 485-9.
15. Jackson M, Chan R, Matoba A, Robin JB. The use of fluorescein-conjugated lectins for the visualization of atypical mycobacteria. *Arch Ophthalmol* (in press).
16. Brown JC, Hunt RC. Lectins. *Int Rev Cytol* 1978; 52:277-349.
17. Sharon N, Lis H. Lectins: cell-agglutinating and sugar-specific proteins. *Science* 1972; 177:949-59.
18. Marines HM, Osato MS, Font RL. The value of calcofluor white in the diagnosis of mycotic and *Acanthamoeba* infections of the eye and ocular adnexa. *Ophthalmology* 1987; 94:23-6.
19. Monheit JE, Cowan DF, Moore DG. Rapid detection of fungi in tissues using calcofluor white and fluorescence microscopy. *Arch Pathol Lab Med* 1984; 108:616-8.
20. Neff RJ, Benton WF, Neff RH. The composition of the mature cyst wall of the soil amoeba *Acanthamoeba* sp. *J Cell Biol* 1964; 23 (4th Ann Meeting Absts.):66A.
21. Wilhelmus KR, Osato MS, Font RL, et al. Rapid diagnosis of *Acanthamoeba* keratitis using calcofluor white. *Arch Ophthalmol* 1986; 104: 1309-12.
22. Epstein RJ, Wilson LA, Visvesvara GS, Plourde EG Jr. Rapid diagnosis of *Acanthamoeba* keratitis from corneal scrapings using indirect fluorescent antibody staining. *Arch Ophthalmol* 1986; 104:1318-21.
23. Sutphin JE, Robinson NM, Wilhelmus KR, Osato MS. Improved detection of oculomycoses using induced fluorescence with Cellufluor. *Ophthalmology* 1986; 93:416-7.
24. Panjwani N, Alroy J, Rodrigues MM, et al. Alteration in stromal glycoconjugates in macular corneal dystrophy. *ARVO Abstracts. Invest Ophthalmol Vis Sci* 1984; 25(Suppl):4.
25. Blanks JC, Johnson LV. Specific binding of a peanut lectin to a class of retinal photoreceptor cells: a species comparison. *Invest Ophthalmol Vis Sci* 1984; 25:546-57.
26. Stoddart RW, Herbertson BM. The use of fluorescein-labelled lectins in the detection and identification of fungi pathogenic for men: a preliminary study. *J Med Microbiol* 1978; 11:315-24.
27. Bartnicki-Garcia S, Lippman E. Fungal cell wall composition. In: Laskin AI, Lechevalier HA, eds. *Handbook of Microbiology*, 2nd ed. Vol. IV. Microbial Composition: Carbohydrates, Lipids, and Minerals. Boca Raton, FL: CRC Press, 1977; 229-39.
28. Bowers B, Korn ED. The fine structure of *Acanthamoeba castellanii*. I. The trophozoite. *J Cell Biol* 1968; 39:95-111.
29. Bowers B, Korn ED. Localization of lipophosphoglycan on both sides of *Acanthamoeba* plasma membrane. *J Cell Biol* 1974; 62:533-40.
30. Bowers B, Korn ED. The fine structure of *Acanthamoeba castellanii* (Neff strain). II. Encystment. *J Cell Biol* 1969; 41:786-805.