

Isavuconazole brain penetration in cerebral aspergillosis

F. Lamothe^{1,2*}, T. Mercier³, P. André³, J. L. Paganí⁴,
O. Pantet⁴, R. Maduri⁵, B. Guery¹ and L. A. Decosterd³

¹Service of Infectious Diseases, Lausanne University Hospital, Lausanne, Switzerland; ²Institute of Microbiology, Lausanne University Hospital, Lausanne, Switzerland; ³Service and Laboratory of Clinical Pharmacology, University Hospital, Lausanne, Switzerland; ⁴Service of Intensive Care Medicine, Lausanne University Hospital, Lausanne, Switzerland; ⁵Department of Clinical Neurosciences, Service of Neurosurgery, Lausanne University Hospital, Lausanne, Switzerland

*Corresponding author. Infectious Diseases Service, Centre Hospitalier Universitaire Vaudois, Rue du Bugnon 46, 1011 Lausanne, Switzerland. Tel: +41-21-314-11-11; E-mail: Frederic.Lamothe@chuv.ch

Sir,

Cerebral aspergillosis is a rare, but often fatal, infection in immunocompromised patients. The new triazole drug isavuconazole was recently approved for the treatment of invasive aspergillosis (IA) and may be associated with less hepatotoxicity compared with voriconazole.¹ Some reports suggest that isavuconazole is also effective for the treatment of cerebral aspergillosis and other fungal infections of the CNS, but experience is limited.^{2–5}

We report data of isavuconazole concentrations within the brain lesion of a patient with cerebral aspergillosis. The patient developed IA during the neutropenic phase following induction chemotherapy for AML. The diagnosis initially relied on a positive galactomannan in serum, a positive PCR for *Aspergillus fumigatus* in a bronchial aspirate and nodular chest CT lesions. Cerebral CT and MRI showed a frontoparietal abscess consistent with cerebral aspergillosis. Initial amphotericin B therapy was switched to intravenous isavuconazole (200 mg q8h for days 1 and 2, then 200 mg q24h).¹ This latter drug was preferred over voriconazole because of severe cholestasis and renal failure requiring continuous haemofiltration. After 4 days of isavuconazole therapy, a biopsy of the brain lesion was performed by craniectomy. The diagnosis of cerebral aspergillosis was confirmed by culture of the brain specimen growing *A. fumigatus* and histopathology showing mycelial elements and infiltrates of polymorphonuclear neutrophils. The MIC of isavuconazole was 1 mg/L. The patient died 4 days later in the context of multiple organ failure.

Isavuconazole concentrations were measured in plasma at two different timepoints and in two specimens of the brain lesion, consisting of the surrounding cerebral parenchyma and liquid content of the abscess. Measurement was performed by LC-MS/MS,

with isavuconazole-¹³C-d4 as internal standard using an adaptation of our validated method.⁶ The brain biopsy was washed with 0.9% NaCl, dried under nitrogen flux and accurately weighed. The specimen (2.0 mg), mixed with 20 µL of 0.9% NaCl, 20 µL of MeOH containing internal standard and 40 µL of acetonitrile with 0.5% formic acid, was ground with 1.4 mm zirconium oxide beads using a Precellys® Evolution homogenizer. After centrifugation, the supernatant was analysed by LC-MS/MS. For abscess content, measurement was performed directly in the liquid without pre-dilution. The quantification limit was 0.01 mg/L. A Bayesian *maximum a posteriori* estimation method was used to compute the estimated isavuconazole concentration curve based on two-compartment population pharmacokinetics adapted according to plasma isavuconazole concentration.⁷

Trough plasma concentrations of isavuconazole (24 h after last dose) on day 3 and day 6 of therapy were 0.6 and 2.9 mg/L, respectively. Isavuconazole concentration in the brain tissue measured 6 h after the end of the administration of the drug on day 4 was 1.46 mg/kg. The estimated curve showed that the expected plasma concentration on day 4 (timing of brain biopsy) was 1.7 mg/L with an estimated accumulation of 44% (Figure 1). Thus, the estimated brain/plasma concentration ratio at this time was 0.9. The concentration measured within the abscess fluid was 0.02 mg/L.

Pharmacokinetic studies in rats showed an isavuconazole brain/plasma concentration ratio of 1.8 after single-dose administration (similar to voriconazole) and a ratio close to 1 after repeated administration (day 7),⁸ which is consistent with our results. There are currently limited data about the penetration of isavuconazole or other mould-active azoles in brain, most of them being derived from animal models or human autopsies with measurements performed in healthy brain tissue.^{8,9} However, drug bioavailability in the inflammatory tissue of fungal encephalitis may be different compared with healthy brain. To our knowledge, our data represent the first report of isavuconazole concentrations in a brain lesion of a patient with cerebral aspergillosis. Our results show that the isavuconazole concentration measured in the inflammatory brain tissue surrounding the abscess was equivalent to the predicted concentration in plasma at this timepoint. While targeted isavuconazole concentrations are not defined for therapeutic drug monitoring, the concentrations reported here in plasma and brain tissue were superior to the MIC for the present *A. fumigatus* isolate (i.e. 1 mg/L) and within the range of plasma trough concentrations observed in the SECURE trial on day 7 (mean 2.6 ± 1.0 mg/L),¹⁰ which may thus be considered as appropriate. However, the concentration of isavuconazole in the liquid of the abscess was quasi-null, which further demonstrates that penetration of antimicrobials within abscesses is an issue and that surgery is required in such cases.

These results should be interpreted cautiously as they are derived from a single case experience, with a low amount of tissue and using a measurement method that has not been validated for such biological material. Moreover, isavuconazole measurements were performed relatively early after start of therapy, while

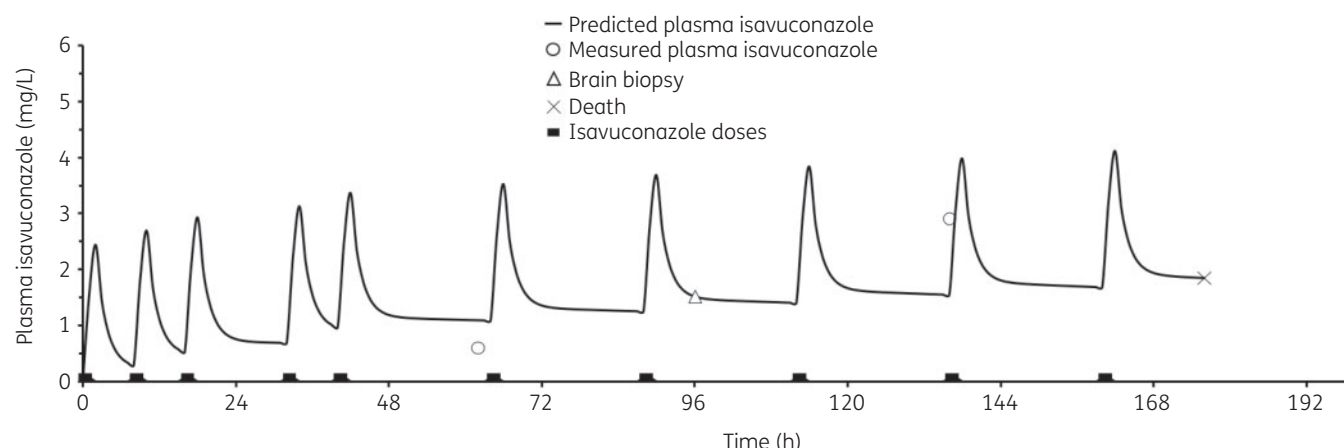


Figure 1. Patient's isavuconazole plasma concentrations estimated by a Bayesian *maximum a posteriori* method based on two plasma samples (open circles). Brain biopsy and abscess puncture, patient's death and isavuconazole doses are indicated by an open triangle, a cross and filled rectangles, respectively. Note: one loading dose of isavuconazole on day 2 was missing.

steady-state drug concentrations were not achieved. Further analyses would be warranted to better define the bioavailability of isavuconazole in human brain tissue.

Funding

This study was carried out as part of our routine work.

Transparency declarations

None to declare.

References

- 1 Maertens JA, Raad II, Marr KA *et al.* Isavuconazole versus voriconazole for primary treatment of invasive mould disease caused by *Aspergillus* and other filamentous fungi (SECURE): a phase 3, randomised-controlled, non-inferiority trial. *Lancet* 2016; **387**: 760–9.
- 2 Guest JM, Singh PK, Revankar SG *et al.* Isavuconazole for treatment of experimental fungal endophthalmitis caused by *Aspergillus fumigatus*. *Antimicrob Agents Chemother* 2018; **62**: e01537–18.
- 3 Peixoto D, Gagne LS, Hammond SP *et al.* Isavuconazole treatment of a patient with disseminated mucormycosis. *J Clin Microbiol* 2014; **52**: 1016–9.
- 4 Schwartz S, Cornely OA, Marty FM *et al.* Efficacy of isavuconazole in patients with central nervous system invasive fungal disease. In: *Abstracts of the ASM Microbe Meeting, New Orleans, LA, USA, 2017*. Abstract 229. American Society for Microbiology, Washington, DC, USA.
- 5 Wiederhold NP, Kovanda L, Najvar LK *et al.* Isavuconazole is effective for the treatment of experimental cryptococcal meningitis. *Antimicrob Agents Chemother* 2016; **60**: 5600–3.
- 6 Decosterd LA, Rochat B, Pesse B *et al.* Multiplex ultra-performance liquid chromatography-tandem mass spectrometry method for simultaneous quantification in human plasma of fluconazole, itraconazole, hydroxyitraconazole, posaconazole, voriconazole, voriconazole-*N*-oxide, anidulafungin, and caspofungin. *Antimicrob Agents Chemother* 2010; **54**: 5303–15.
- 7 Desai A, Kovanda L, Kowalski D *et al.* Population pharmacokinetics of isavuconazole from phase 1 and phase 3 (SECURE) trials in adults and target attainment in patients with invasive infections due to *Aspergillus* and other filamentous fungi. *Antimicrob Agents Chemother* 2016; **60**: 5483–91.
- 8 Schmitt-Hoffmann AH, Kato K, Townsend R *et al.* Tissue distribution and elimination of isavuconazole following single and repeat oral-dose administration of isavuconazonium sulfate to rats. *Antimicrob Agents Chemother* 2017; **61**: e01292–17.
- 9 Lutsar I, Roffey S, Troke P. Voriconazole concentrations in the cerebrospinal fluid and brain tissue of guinea pigs and immunocompromised patients. *Clin Infect Dis* 2003; **37**: 728–32.
- 10 Desai AV, Kovanda LL, Hope WW *et al.* Exposure-response relationships for isavuconazole in patients with invasive aspergillosis and other filamentous fungi. *Antimicrob Agents Chemother* 2017; **61**: e01034–17.