

Treatment of allergic bronchopulmonary aspergillosis: from evidence to practice

Sahajal Dhooria¹, Inderpaul S Sehgal¹, Valliappan Muthu¹ & Ritesh Agarwal^{*,1}¹Department of Pulmonary Medicine, Postgraduate Institute of Medical Education & Research, Chandigarh, India*Author for correspondence: Fax: +91 172 274 8215; agarwal.ritesh@outlook.in

Allergic bronchopulmonary aspergillosis (ABPA) is a complex pulmonary disorder caused by dysregulated immune responses against *Aspergillus fumigatus*. The disorder usually complicates the course of patients with asthma and cystic fibrosis. Patients with ABPA most often present with asthma that is poorly controlled despite inhaled corticosteroids and long-acting β_2 agonists. The treatment of ABPA is complicated due to the occurrence of recurrent exacerbations and spontaneous remissions. The drugs used for treating ABPA include systemic glucocorticoids, antifungal agents and biologics, each with its own benefits and drawbacks. In this review, we illustrate the treatment pathway for ABPA in different situations, using a case-based approach. In each case, we present the options for treatment based on the available evidence from recent clinical trials.

First draft submitted: 4 October 2019; Accepted for publication: 12 February 2020; Published online: 14 April 2020

Keywords: abpm • *Aspergillus* • asthma • azole • cystic fibrosis • fungus • itraconazole • mycosis • triazole • voriconazole

Allergic bronchopulmonary aspergillosis (ABPA) is the manifestation of a misbalanced immune response to the ubiquitous fungus, *Aspergillus fumigatus* [1]. While usually complicating the course of patients with bronchial asthma and cystic fibrosis, it can occasionally occur in other lung disorders [2–7]. In the absence of a reference standard, the criteria for its diagnosis remain a work in progress. The commercial availability of better diagnostic tests, such as automated immunoassays for the detection of IgE and IgG antibodies against the crude and recombinant antigens of *A. fumigatus* promises to improve the diagnostic accuracy for this disease [8–10]. Currently, the diagnosis and staging of ABPA are based on the recommendations of the International Society for Human and Animal Mycology working group (Tables 1–3) [11]. Untreated ABPA can lead to extensive bronchiectasis and pulmonary fibrosis, with resultant respiratory failure and cor pulmonale. Thus, it is crucial that the disease is recognized timely and treated appropriately.

From a clinician's perspective, the management of ABPA remains perplexing due to several reasons: its myriad presentations; imperfect diagnostic criteria and classification; the intertwining of the disease manifestations and natural history of ABPA with those of the underlying disorder (asthma or cystic fibrosis); and, the absence of a uniform approach to treatment [12]. Currently, several treatment options are available for the management of ABPA, with consistent progress in the emergence of evidence for their efficacy. While detailed descriptions of the current approach to the diagnosis and management of ABPA are available [9,13,14], a practical case-based approach to the treatment is required. Herein, we review the recent clinical trials of treatment in ABPA and exemplify the therapeutic approach to ABPA in different situations, using illustrative cases.

Case 1

A 28-year-old man, with history of bronchial asthma for 7 years, presented with complaints of increased breathlessness, expectoration of brownish mucus plugs and malaise for 5 months. He had been receiving a combination of formoterol (24 μ g/day) and budesonide (1600 μ g/day) through a metered-dose inhaler, with good adherence. On examination, he had a body weight of 62 kg. Chest auscultation revealed the presence of wheezing and crackles at the lung bases. The forced vital capacity (FVC) was 3.21 l (72% of the predicted value), forced expiratory volume in 1 s (FEV₁) was 1.83 l

Table 1. Modified International Society for Human and Animal Mycology-allergic bronchopulmonary aspergillosis working group criteria used for the diagnosis of allergic bronchopulmonary aspergillosis.

Predisposing conditions
Asthma, cystic fibrosis
Obligatory criteria (both should be present)
Serum <i>Aspergillus fumigatus</i> -specific IgE >0.35 kUA/l
Serum total IgE >1000 IU/ml
Other criteria (at least two out of three)
Peripheral blood eosinophil count >500 cells/ μ l
Typical imaging findings of ABPA on computed tomography of the chest
Serum <i>A. fumigatus</i> -specific IgG >27 mgA/l
ABPA: Allergic bronchopulmonary aspergillosis. Adapted with permission from [11].

Table 2. International Society for Human and Animal Mycology-allergic bronchopulmonary aspergillosis working group radiologic classification of allergic bronchopulmonary aspergillosis.

Classification	Features
Serological ABPA (ABPA-S)	– All the diagnostic features of ABPA listed in Table 1 – No evidence of bronchiectasis on HRCT chest
ABPA with bronchiectasis (ABPA-B)	All the findings of ABPA including bronchiectasis on HRCT chest
ABPA with high-attenuation mucus (ABPA-HAM)	All features of ABPA along with the presence of HAM on HRCT chest
ABPA with chronic pleuropulmonary fibrosis (ABPA- CPF)	ABPA with radiologic findings of pulmonary fibrosis, bleb, bullae, pneumothorax, parenchymal scarring, emphysematous change, multiple cysts, fibro-cavitary lesions, mycetoma and pleural thickening
Adapted with permission from [11]. ABPA: Allergic bronchopulmonary aspergillosis; CPF: Chronic pleuropulmonary fibrosis; HAM: High-attenuation mucus; HRCT: High-resolution computed tomography.	

Table 3. Staging of allergic bronchopulmonary aspergillosis in patients with asthma.

Stage	Definition	Features
0	Asymptomatic	– Fulfilling the diagnostic criteria of ABPA – No previous diagnosis of ABPA – Controlled asthma
1	Acute	– Meeting the diagnostic criteria of ABPA – No previous diagnosis of ABPA – Symptoms consistent with ABPA
1a	With mucoid impaction	Presence of mucoid impaction on thoracic imaging
1b	Without mucoid impaction	Absence of mucoid impaction on thoracic imaging
2	Response	Clinical or radiological improvement and decline in serum total IgE by at least 25% of baseline at 8 weeks
3	Exacerbation	Clinical or radiological worsening and increase in serum total IgE by at least 50% from the 'new' baseline established following response or remission
4	Remission	Sustained clinical and radiological improvement and serum total IgE levels persisting at or below baseline (or an increase by <50%) for at least 6 months, off therapy
5a	Treatment-dependent ABPA	Two or more exacerbations within 6 months of stopping therapy or clinical or radiological worsening, along with an increase in serum total IgE levels, on tapering oral glucocorticoids or azoles
5b	Glucocorticoid-dependent asthma	Systemic glucocorticoids required for control of asthma while the ABPA activity is controlled (as indicated by serum total IgE and thoracic imaging)
6	Advanced ABPA	Extensive bronchiectasis secondary to ABPA along with either cor pulmonale or chronic type II respiratory failure
ABPA: Allergic bronchopulmonary aspergillosis. Adapted with permission from [11].		

(68% of the expected value), with an FEV₁/FVC ratio of 0.57, suggestive of moderate airflow obstruction. A significant post-bronchodilator reversibility was present. Serum *A. fumigatus*-specific IgE (Af-IgE), total IgE and *A. fumigatus*-specific IgG (Af-IgG) values were 43.8 kUA/l, 16,289 IU/ml and 61.2 mgA/l, respectively. The blood eosinophil count was

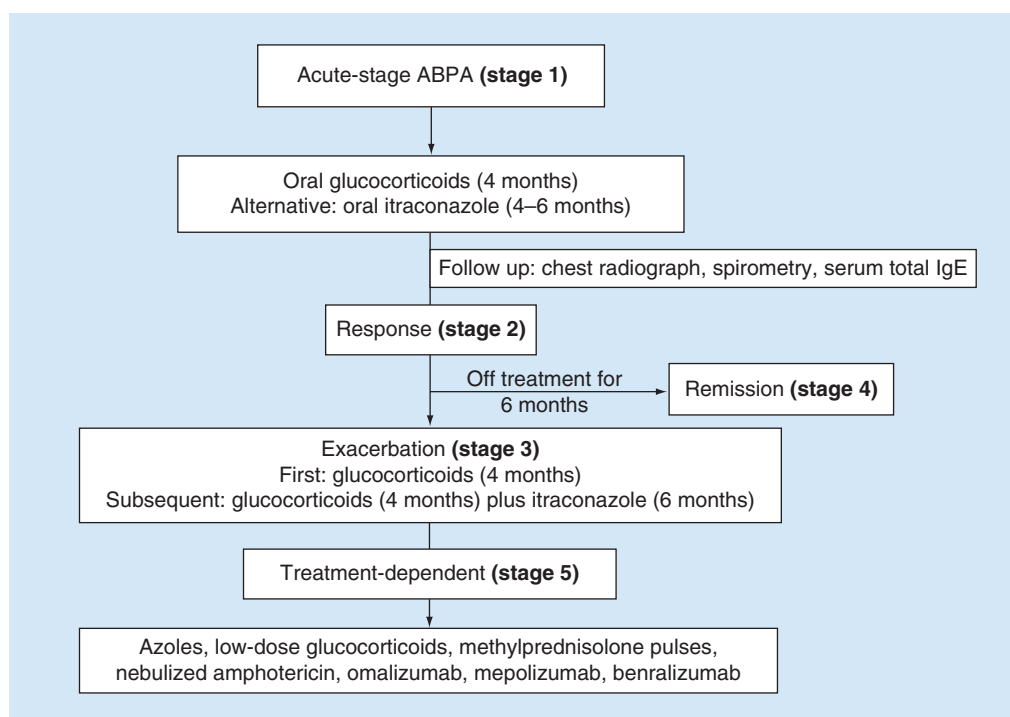


Figure 1. Suggested treatment approach for the management of allergic bronchopulmonary aspergillosis.

889 cells/ μ l. Chest radiograph showed the presence of toothpaste and gloved-finger opacities. High-resolution computed tomography (HRCT) of the chest revealed the presence of bronchiectasis in three bronchopulmonary segments and extensive mucus impaction. A diagnosis of acute ABPA with bronchiectasis and mucoid impaction (stage 1a) was made (Tables 1–3). What should be the further management of the patient?

A suggested approach for the treatment of ABPA is summarized in Figure 1. Glucocorticoids are currently the mainstay of treatment of ABPA, [15] especially for the acute stage with mucoid impaction (stage 1) and for exacerbations (stage 3) [16]. Prednisolone is the most widely used glucocorticoid in ABPA and has been used in various doses (Supplementary Table 1). Prednisolone may be administered in a low dose (0.5 mg/kg/day for 2 weeks, 0.5 mg/kg on alternate days for 8 weeks, then taper by 5 mg every 2 weeks and discontinue) for a duration of 3–5 months (Regimen A, Table 4) [17]. Alternately, a higher dose regimen (0.75 mg/kg/day for 6 weeks, 0.5 mg/kg/day for 6 weeks, then taper by 5 mg every 6 weeks and discontinue after 8–10 months) may also be instituted (Regimen B, Table 4). In a randomized controlled trial (RCT), the lower dose regimen was as effective as the higher dose in terms of the improvement in lung function, the time to first exacerbation, the number of subjects with exacerbation at 1 year and the occurrence of glucocorticoid-dependent ABPA at 2 years [16]. The lower dose regime also resulted in a lesser cumulative glucocorticoid dose and fewer side effects. However, the early composite response at 6 weeks (defined as a combination of clinical [improvement in cough and dyspnea >75% of the baseline], immunological [decline in IgE levels by >25%] and radiologic [partial/complete clearance of opacities on chest radiograph] improvement) was not achieved in about 13% of subjects with regimen A, while it was achieved in all subjects using the regimen B. A dose of prednisolone with a slightly higher initial glucocorticoid dose intensity than regimen A (0.5 mg/kg/day for 4 weeks, 0.25 mg/kg/day for 4 weeks, 0.125 mg/kg/day for 4 weeks, then taper by 5 mg every 2 weeks and discontinue after 4 months) was associated with 100% early composite response (at 6 weeks) in three later studies from the authors' group (Regimen C, Table 4) [18–20]. Therefore, regimen C may offer the right balance between early treatment response and toxicity. Patients on long-term glucocorticoid therapy should be routinely offered calcium and vitamin D supplements alone in case of a low fracture risk and combined with bisphosphonates in cases with a high fracture risk [21]. Vitamin D has also been proposed as a disease modifying agent in patients with ABPA complicating cystic fibrosis [22–24]. However, in a small randomized study, there was no difference in the clinical or the immunological outcomes on adding vitamin D to glucocorticoids in ABPA complicating asthma [20].

Table 4. Doses of various drugs used in the management of allergic bronchopulmonary aspergillosis.

Oral glucocorticoids
Prednisolone (or equivalent)
Regimen A: 0.5 mg/kg/day for 2 weeks, 0.5 mg/kg on alternate days for 8 weeks. Then taper by 5 mg every 2 weeks and discontinue after 3–5 months With this protocol, patients need to be closely followed, as 13% of patients may require escalation of steroid dose
Regimen B: 0.75 mg/kg/day for 6 weeks, 0.5 mg/kg/day for 6 weeks, then taper by 5 mg every 6 weeks and discontinue after 8–10 months
Regimen C: 0.5 mg/kg/day for 4 weeks, 0.25 mg/kg/day for 4 weeks, 0.125 mg/kg/day for 4 weeks, then taper by 5 mg every 2 weeks, discontinue after 4 months
Oral azoles
Itraconazole 200–300 mg twice a day, for at least 16 weeks (trough levels 0.5–2 mg/l)
Voriconazole 200–300 mg twice a day, for at least 16 weeks (trough levels 0.5–2 mg/l)
Posaconazole suspension 400 mg twice a day, for at least 16 weeks (trough levels 0.5–1.5 mg/l)
Nebulized amphotericin B
Liposomal amphotericin B Intermittent: 25 mg twice a week
Amphotericin B lipid complex Intermittent: 50 mg twice a week
Amphotericin B deoxycholate Daily: 5–40 mg twice a day Intermittent: 20 mg (10 mg twice daily) thrice a week
Pulse methylprednisolone
15–20 mg/kg/day (maximum 1 gm) by intravenous infusion for 3 consecutive days
Omalizumab
375 mg subcutaneous injection administered every 2 weeks for 6–12 months
Mepolizumab
300 mg subcutaneous injection administered every month
Benralizumab
30 mg subcutaneous injection administered once every 4 weeks for the first three doses, thereafter once every 8 weeks
Inhaled glucocorticoids
Inhaled corticosteroids should not be used alone for controlling the immunological activity of ABPA with bronchiectasis. However, they are useful in the management of asthma and serological ABPA
Follow-up and monitoring
<ul style="list-style-type: none"> • Monitoring of clinical symptoms (cough, dyspnea), chest radiograph, spirometry and serum total IgE levels, every 8 weeks • Monitor for adverse effects of treatment • A satisfactory response is present when there is a clinical or radiological improvement and at least 25% decline in serum total IgE levels • Monitor IgE frequently to establish the 'new' baseline level for an individual patient • Clinical or radiological worsening and a 50% increase in serum total IgE values suggests an exacerbation
ABPA: Allergic bronchopulmonary aspergillosis.

The patient was treated with oral prednisolone 30 mg/day for 4 weeks, followed by 15 mg/day for 4 weeks. At 8 weeks, there was a marked improvement in his symptoms and a reduction in wheeze on chest auscultation. Serum IgE level dropped to 10,918 IU/ml. The FVC and FEV₁ improved to 3.57 l and 2.39 l, respectively, with an FEV₁/FVC ratio of 0.67. The chest radiograph showed a partial clearing of opacities.

The patient has achieved an early composite response (stage 2), with partial improvement in the clinical and radiologic parameters. The improved FEV₁/FVC ratio and FVC indicate a decrease in airflow obstruction and hyperinflation, respectively. After starting treatment for acute ABPA, monitoring is performed with clinical evaluation, spirometry, chest radiograph and serum total IgE levels. There is no utility of measuring either *Af*-IgE or *Af*-IgG during treatment, as their levels do not generally conform to clinical or radiologic improvement or the reduction in the serum total IgE [25,26]. Chest radiographs are usually sufficient for monitoring; HRCT chest is not required routinely.

The patient was further administered prednisolone 7.5 mg/day for 4 weeks, 5 mg/day for 2 weeks and 2.5 mg/day for 2 weeks. At 4 months of treatment, the patient had well-controlled asthma on the same dose of inhaled corticosteroid and long-acting bronchodilator, as at the baseline. There was a complete resolution of gloved-finger and toothpaste opacities on the chest radiograph, with the presence of residual tram-track and ring-shaped opacities in bilateral lower lobes, representing bronchiectasis. Serum IgE levels were 8231 IU/ml at 4 months. Prednisolone was stopped. The patient

remained stable at the usual dose of inhaled corticosteroid plus long-acting bronchodilator in the subsequent year with total IgE values of 6978, 5626, 5280 and 6091 IU/ml, at 6, 9, 12 and 18 months, respectively.

The patient had a good response to glucocorticoid treatment with expected clinical (well-controlled asthma), radiologic (complete resolution of mucoid impaction on the chest radiograph) and immunologic (persistent decline in IgE levels) outcomes at 4 months (end of treatment). As the patient has remained largely asymptomatic with stable IgE levels for at least 6 months (without the requirement of glucocorticoid or antifungal therapy), he may be considered to have a remission (stage 4). In case of a good response at 4 months, subsequent monitoring may be performed every 3 months for a year and then every 6 months with a clinical examination and serum total IgE levels. A chest radiograph may be obtained if clinically indicated.

At 23 months after the initial visit, the asthma control of the patient worsened with frequent nocturnal symptoms and regular usage of reliever medication. Chest radiograph showed the presence of a large homogeneous opacity in the right lower zone. Serum IgE levels were 9134 IU/ml. The FVC and FEV1 fell to 2.93 and 1.62 l, respectively.

After a period of remission, the patient has a worsening of respiratory symptoms and the appearance of new radiographic abnormalities. There is an increase of >50% in the serum total IgE values from the last value (6091 IU/ml) achieved during the period of remission. The patient is now considered to have an exacerbation (stage 3). It is important to remember that in several patients, the IgE values can wax and wane over time. A mere elevation in serum total IgE without clinical or radiological worsening does not constitute an exacerbation and does not warrant treatment. The treatment of the first exacerbation is like the treatment of acute disease. Any of the three glucocorticoid regimens can be used. An alternative is to use a combination of glucocorticoids and an antifungal azole.

The patient was again started on regimen C. At 6 weeks, the patient had less than 25% improvement in cough and breathlessness; however, serum IgE had declined to 5140 IU/ml. The chest radiograph showed a persistent opacity in the right lower zone. Computed tomography (CT) of the chest revealed the presence of a soft tissue density (with an attenuation higher than the paraspinal muscle) in the medial segment of the right lower lobe, causing a collapse of the entire segment.

The patient has shown only a partial clinical response and the HRCT chest has revealed the presence of segmental collapse [27]. The collapse is due to bronchial obstruction by high-attenuation mucus, also known as high-density mucus. In most cases, lung collapse resolves after the administration of glucocorticoids. As the collapse had not resolved with oral glucocorticoid alone, as in this case, a therapeutic bronchoscopy is required for removing the impacted mucus.

Flexible bronchoscopy was performed and mucus plugging of the medial segment of the lower right lobe was noticed. Bronchial toileting was performed by instillation of normal saline, repeated suctioning and the use of flexible forceps. Given the failure of these conventional methods to remove the plug, a cryoprobe was utilized to remove it. There was a complete resolution of the lower right lobe opacity along with the re-expansion of the collapsed segment at 6 weeks after bronchoscopy. At 6 months, the patient had good control of asthma with an IgE level of 5398 IU/ml. Prednisolone was stopped.

The mucus plug was removed using flexible bronchoscopic cryoextraction in this case [28]. The patient seems to have a good response at 6 months, with control of asthma symptoms, a >25% reduction in the serum IgE levels and an improved chest radiograph.

*Five months after stopping prednisolone, the patient presented with recurrence of cough and increased breathlessness. The IgE levels rose to 11,249 IU/ml. The chest radiograph showed a few bilateral small nodular opacities. Sputum grew *A. fumigatus*, which was susceptible to azoles.*

The patient has a second relapse without entering a period of remission. The optimal treatment at this juncture would be a combination of glucocorticoid (regimen A) along with an antifungal azole.

The patient was administered 30 mg/day of prednisolone for 2 weeks, followed by 30 mg on alternate days for 8 weeks. The patient was also given oral itraconazole 200 mg twice a day. At 2 weeks, the trough level was 3.21 mg/l. The dose was reduced to 100 mg twice a day and subsequently, a trough level of 1.09 mg/l was attained. Liver function tests and plasma glucose levels at 2, 4, 8 and 24 weeks were normal. At 6 months of treatment, the patient achieved good clinical, radiologic and immunological response once again. Prednisolone and itraconazole were stopped at 4 and 6 months, respectively. Appropriate monitoring was continued during the subsequent follow-up visits.

The antifungal azoles, namely, itraconazole, voriconazole and posaconazole, have all been used in the treatment of ABPA (Supplementary Table 2) [29,30]. The most extensive evidence is available for the use of itraconazole [18,19,31,32]. Itraconazole is widely used in the prevention of exacerbation and maintenance of remission, based on the results of two RCTs [31,32]. In both the studies, the use of itraconazole led to a decline in the number of exacerbations [31,32].

Case 2

A 56-year-old lady, a known case of bronchial asthma for 30 years, presented with increased breathlessness and productive cough for 3 months. She was receiving a combination of formoterol (24 µg/day), fluticasone (500 µg/day) and tiotropium (18 µg/day), all in inhaled forms. The patient had reasonable asthma control prior to the current illness. She had suffered from several exacerbations of asthma in the past, for which she was treated with short courses of oral glucocorticoids. She also suffered from obesity, hypertension, Type 2 diabetes mellitus and osteoporosis. A mild expiratory wheeze was present on chest auscultation. Serum levels of Af-IgE, total IgE and Af-IgG were 15.6 kUA/l, 4823 IU/ml and 42.8 mgA/l, respectively. The blood eosinophil count was 409 cells/µl. Spirometry showed a poorly reversible airflow obstruction. The chest radiograph revealed the presence of ring shadows in the right lower lobe, while the HRCT chest showed the presence of bronchiectasis in five bronchopulmonary segments along with centrilobular nodules. A diagnosis of acute ABPA with bronchiectasis (stage 1b) was made. What would be an appropriate way to treat this patient?

While glucocorticoids are the treatment of choice in ABPA, they are associated with a myriad of side effects, including weight gain, osteopenia, hyperglycemia and others [33]. This patient has obesity, Type 2 diabetes mellitus and osteoporosis, all of which can worsen with the use of glucocorticoids. Recently, two RCTs have evaluated azole monotherapy in patients with acute-stage ABPA. In one RCT (131 subjects), itraconazole monotherapy had similar long-term efficacy as treatment with prednisolone alone, in patients with acute-stage ABPA [19]. The percent decline in IgE at 6 weeks and 3 months, the number of subjects with exacerbations at the end of one and 2 years and the improvement in lung function were similar in both the treatment groups. Subjects who received prednisolone had a higher incidence of adverse effects. The only drawback of itraconazole monotherapy was the failure to achieve a composite response in 12% of the subjects at 6 weeks, compared with none with prednisolone. The other RCT evaluated voriconazole monotherapy in 50 subjects with acute-stage ABPA [18]. In this study, voriconazole monotherapy (400 mg/day for 4 months) had similar efficacy to prednisolone alone in terms of the composite response, the number of subjects with exacerbations after 1 and 2 years, the time to first exacerbation and the change in lung function. Thus, triazoles are an effective alternative to glucocorticoids in acute stages of ABPA.

In our experience, voriconazole is not as well tolerated as itraconazole, mainly due to photosensitivity and mucositis [34]. On the other hand, posaconazole, another azole used in the treatment of ABPA (Supplementary Table 2), is expensive as compared with itraconazole. Also, more evidence is needed before posaconazole can be considered as a first-line antifungal azole. Therefore, azole therapy is usually begun with itraconazole; voriconazole and posaconazole are reserved for those who fail therapy or experience adverse reactions with itraconazole or fail to achieve optimal serum levels of itraconazole, despite maximum dose (600 mg/day) [30].

The patient was initiated on oral itraconazole (400 mg/day). The trough serum level of itraconazole at 2 weeks was 0.29 mg/l. Subsequently, itraconazole was increased to 300 mg twice a day, with a subsequent trough level of 0.97 mg/l. Cough resolved and the patient achieved good asthma control in about 6 weeks. The serum IgE levels at 2, 4 and 6 months were 3634 IU/ml, 2987 IU/ml and 2467 IU/ml, respectively. The chest radiograph remained normal.

We routinely perform therapeutic drug monitoring while the patient is on azole therapy, as it not only ensures compliance, but also there is a large variation in the bioavailability of itraconazole, especially while using generic preparations [35]. The optimum trough level of itraconazole in the serum is between 0.5 and 2.0 mg/l [36,37]. The drug should be administered after food or with an acidic drink (lemonade, fruit juice or cola) for good absorption (on the other hand, voriconazole should be given on an empty stomach). Gastric acid suppressants and calcium supplements should be avoided, as far as possible, during itraconazole therapy. Liver function tests should also be performed periodically for monitoring adverse effects. The duration of itraconazole treatment is a minimum of 4 months but can be extended for a longer period depending on the patient's response. It is essential to obtain sputum for fungal cultures and drug susceptibility testing in those receiving long-term azole therapy [38]. The prevalence of azole resistance in *A. fumigatus* has been variably reported between 1 and 20% in different countries [39]. While azole resistance can occur during long-term triazole therapy (including those with ABPA), the most common route of resistance is believed to be due to the environmental fungicide exposure [40]. The azoles act by inhibiting fungal lanosterol 14- α demethylase, which is encoded by cytochrome P (cyp) 51A and mutations in cyp51A induce resistance to triazoles [39].

Case 3

A 32-year-old woman, a known case of bronchial asthma and ABPA for 6 and 3 years, respectively, presented with increased breathlessness for 2 weeks. She was receiving inhaled formoterol (24 µg/day), fluticasone (1000 µg/day)

and tiotropium (18 µg/day), oral montelukast and oral prednisolone (5 mg/day) for the control of asthma. She had suffered from exacerbations of asthma five times in the preceding 2 years and was hospitalized during two of the occasions. In the preceding 3 years, she had also received two 4-month courses of oral prednisolone and one 9-month long course of itraconazole for ABPA exacerbations. During the current episode, the patient had tachypnea and hypoxemia. Chest auscultation revealed profuse wheezing and coarse crackles. The patient was obese, with mild Cushingoid habitus and no other comorbid conditions. The serum IgE level was 5109 IU/ml compared with a previous baseline level of 3050 IU/ml. Chest radiograph revealed a few ill-defined rounded opacities, bilaterally. The patient was diagnosed to have an exacerbation of both asthma and ABPA (stage 3). What treatment should be administered to the patient?

The patient should be given appropriate treatment for the exacerbation of asthma, according to best practice guidelines [41]. In this case, it would include oxygen, nebulization with bronchodilators and systemic glucocorticoids. The patient has already received oral glucocorticoids and itraconazole for ABPA exacerbations in the past. Currently, she is on regular low-dose glucocorticoids for asthma control and has glucocorticoid-related adverse effects. The options for maintaining remission in patients with recurrent exacerbations of ABPA include low-dose glucocorticoids, antifungal azoles, pulse doses of intravenous methylprednisolone, nebulized amphotericin B, omalizumab and anti-Th2 therapies (mepolizumab and benralizumab) [42–44]. As this patient also has a severe exacerbation of asthma, pulse doses of methylprednisolone may be useful for the control of both asthma and ABPA. Pulse doses of methylprednisolone have nongenomic effects and may also act as a steroid-sparing agent [42]. The nongenomic effects of glucocorticoids are independent of the cytoplasmic glucocorticoid receptor. These actions are mediated through the regulation of intracellular calcium homeostasis, direct effects on smooth muscle function, reduction of oxygen free radicals and through anti-inflammatory and apoptotic pathways [45]. The steroid sparing action of methylprednisolone pulses is due to the decreased dosing frequency compared with the side effects of daily glucocorticoids [46].

The patient was administered three daily doses of intravenous methylprednisolone (1 g). She improved and was discharged after 4 days. She was subsequently maintained on monthly doses of methylprednisolone and daily voriconazole (200 mg twice a day). Therapeutic drug monitoring for voriconazole was performed to ensure adequate drug levels. After 5 months, she had another asthma exacerbation. Her serum IgE level was 2592 IU/ml (compared with the previous value of 5109 IU/ml), suggesting only an exacerbation of asthma. Pulse methylprednisolone was stopped at 6 months and voriconazole was continued. However, 2 months later, the patient had worsening of symptoms. The serum total IgE was 6200 IU/ml and the chest radiograph was normal. Sputum grew *A. fumigatus*, which was sensitive to both itraconazole and voriconazole. What is the treatment at this stage?

Unfortunately, this patient has a phenotype with recurrent exacerbations of asthma and ABPA. She is already on voriconazole and has received pulse doses of methylprednisolone. It is important to remember that itraconazole can increase the drug levels of methylprednisolone (but not prednisolone) [47]. On the other hand, voriconazole can increase the drug levels of both prednisolone and methylprednisolone [48]. Conversely, glucocorticoids can decrease the plasma levels of voriconazole [49]. Thus, therapeutic drug monitoring for voriconazole is mandatory when the patient is receiving both voriconazole and glucocorticoids. At this stage, nebulized amphotericin, omalizumab or mepolizumab may be considered for treating this patient after inducing an initial response with glucocorticoids. When omalizumab is administered for severe asthma without ABPA, the dosing is based on the IgE levels and body weight (0.016 mg/kg body weight/IU of IgE per ml). In ABPA, as the IgE levels are very high, the dose calculated based on IgE may not be tolerated. In one study (13 subjects), a 750 mg monthly dose was used, which resulted in a significant reduction in exacerbations [44]. We use omalizumab at a dose of 375 mg subcutaneously every 2 weeks. In our experience, it takes at least 4 months for omalizumab to effect a meaningful clinical response. In those with a response, we continue omalizumab for 1–2 years [50].

The patient was given regimen C along with omalizumab (375 mg subcutaneously every 2 weeks). The patient had only one mild asthma exacerbation in the following 6 months. Prednisolone was tapered and stopped at 6 months. She remained free of exacerbations in the following year with omalizumab combined with the previous maintenance treatment for asthma (except oral prednisolone). The serum levels of total IgE were 3019 IU/ml, 3205 IU/ml and 3678 IU/ml at 6, 12 and 18 months, respectively.

Case 4

A 49-year-old man, a known case of bronchial asthma, presented with cough and low-grade fever for 45 days. He had well-controlled asthma with inhaled formoterol (24 µg/day) and fluticasone (1000 µg/day). He was diagnosed to have ABPA 4 years back. He had three exacerbations of ABPA in the past. He received prednisolone alone (for 4 months),

itraconazole monotherapy (for 6 months) and a combination of prednisolone (4 months) and itraconazole (9 months), respectively, for these exacerbations. Therapeutic drug monitoring was performed during itraconazole therapy. The present chest radiograph showed a consolidation of the middle lobe. Serum total IgE levels were 7509 IU/ml, a >50% increase from the level 10 months ago. Sputum staining for acid-fast bacilli and cultures for bacteria and fungus were negative. The patient was diagnosed to have an ABPA exacerbation (stage 3). What is the optimal management of this patient?

The patient has a phenotype of recurrent exacerbations of ABPA with well-controlled asthma. The current exacerbation developed after 10 months of a prolonged course of itraconazole (9 months). As discussed previously, several options are available for recurrent ABPA exacerbations. In this case, voriconazole may be used to induce a response as the patient has already received prednisolone and itraconazole combination therapy. Importantly, one should exclude other causes of consolidation (bacterial, fungal and others) in such a presentation (fever, cough, radiological opacity), especially in patients on long-term glucocorticoid therapy.

The patient was administered oral voriconazole 200 mg twice a day (after food) for 4 months. His trough drug level was 1.32 mg/l at 2 weeks. His liver functions remained normal and he did not develop any visual disturbances or photosensitivity. He had a good clinical, radiologic and immunological response. Remission was maintained using nebulized liposomal amphotericin B at a dose of 50 mg/week (25 mg in 5 ml sterile water twice a week) for the following year.

Nebulized amphotericin is an option for maintaining remission in those with recurrent exacerbations. In one RCT (21 subjects), nebulized amphotericin B deoxycholate was found to be efficacious in maintaining remission in those with recurrent exacerbations, after inducing response with either glucocorticoids or azoles. On the other hand, nebulized amphotericin has poor efficacy in inducing a response in patients with acute-stage ABPA or during an exacerbation of ABPA [51]. Nebulized amphotericin has the potential to precipitate or worsen bronchospasm, especially the deoxycholate preparation; therefore, the first dose should be administered under supervision [52]. The use of short-acting bronchodilator 15–30 min prior to nebulized amphotericin may prevent bronchospasm and improve patient tolerability [43].

Case 5

A 29-year-old man, a known case of bronchial asthma, presented with cough and increasing breathlessness of 3 months duration. Previously, he had well-controlled asthma with his medication that included inhaled formoterol (12 µg/day) and budesonide (400 µg/day). In view of asthma, he was screened for ABPA. Serum Af-IgE, total IgE and Af-IgG levels were 9.56 kUA/l, 2156 IU/ml and 71.8 mgA/l, respectively. The blood eosinophil count was 509 cells/µl. Spirometry showed mild airflow obstruction with bronchodilator reversibility. The chest radiograph was normal. HRCT chest showed mosaic attenuation with air trapping; however, there was no bronchiectasis. The patient was diagnosed as having serological ABPA with poorly controlled asthma. What is the optimal management of this patient?

Patients with ABPA-S (i.e., ABPA without bronchiectasis) may be managed like uncontrolled asthma. A combination of inhaled corticosteroids and long-acting β₂ agonists is used (single maintenance and reliever therapy approach) [53]. The doses of the components are adjusted, as required clinically. If asthma still remains uncontrolled, inhaled tiotropium and leukotriene modifiers should be added [41]. We also prefer instituting omalizumab in patients with ABPA-S before instituting glucocorticoids. In our experience, patients with ABPA-S can be effectively managed without systemic glucocorticoids or antifungal agents. We have followed patients with ABPA-S managed with inhaled corticosteroids alone and no patient has developed bronchiectasis at 5-year follow-up (unpublished data) [54].

In this patient, the doses of formoterol and budesonide were increased to 24 and 800 µg/day, respectively. He achieved good control of asthma and remained well during the subsequent follow-up visits. An HRCT chest repeated after 2 years showed no evidence of bronchiectasis.

Future perspective

Several newer treatment modalities are likely to be available in the next 5–10 years. The most exciting of these are the anti-Th2 therapies. In ABPA, the immunity against *A. fumigatus* is predominantly Th2 mediated and IL-4, IL-5 and IL-13 are the major cytokines implicated. IL-5 recruits eosinophils, which further perpetuate the damage to the airways. Biologic agents targeting IL-5 reduce the recruitment of eosinophils. Recently, the benefit of anti-IL-5 antibodies (mepolizumab and benralizumab) in ABPA has been described in several case series [55–60]. However, a larger randomized trial is required to define the role of these treatments. While triazoles are widely used, they are fraught with several systemic side effects. An interesting proposition is to deliver itraconazole

and voriconazole at the site of abnormality, in other words, the lung, by using inhaled forms [61]. Similarly, randomized trials of systemic glucocorticoids proposed to have lesser side effects, such as deflazacort, are underway (clinicaltrials.gov: NCT04227483). Whether the use of a combination of glucocorticoids and itraconazole is superior to glucocorticoids alone is also not known. A randomized trial addressing this question has been completed (clinicaltrials.gov: NCT02440009). Future studies must involve phenotyping patients of ABPA to define specific therapies for the various subgroups. For instance, we need to explore whether those with high-attenuation mucus (a distinct phenotype), respond better with a combination of glucocorticoids and azoles. Although vitamin D was not found to be useful in a small randomized trial in ABPA, a *post hoc* subgroup analysis did show better outcomes in those with vitamin D deficiency [20]. Future trials should evaluate the role of vitamin D in vitamin D-deficient patients with ABPA.

Executive summary

- Glucocorticoids are currently the treatment of choice in allergic bronchopulmonary aspergillosis (ABPA). The treatment duration is usually 4 months.
 - Patients with acute-stage ABPA with bronchiectasis (stage 1) should generally be treated with oral glucocorticoids.
 - Glucocorticoids are generally preferred over antifungal agents in patients with acute-stage ABPA with uncontrolled asthma.
 - Patients with newly diagnosed ABPA and bronchiectasis, who have well-controlled asthma (stage 0) should also receive treatment with glucocorticoids or azoles to control the underlying inflammation and maximally optimize the lung function.
- An alternative treatment approach in these patients is to use oral itraconazole, especially in those with an increased risk of glucocorticoid-related adverse reactions.
- Most patients with acute-stage ABPA show a good response to treatment characterized by a decline in serum IgE, improvement in lung function and clearing of radiologic opacities (stage 2). About 40–50% of these patients experience an exacerbation (stage 3), most commonly in the first year after stopping treatment. The remaining patients experience long-term remission (stage 4) and require only inhaled medications for asthma control.
- A small but substantial number of patients experience recurrent exacerbations (stage 5) and require treatment with either azoles, low-dose glucocorticoids, methylprednisolone pulses, nebulized amphotericin, omalizumab, mepolizumab or benralizumab, either alone or in combination.
- Patients with ABPA-S generally do not require oral glucocorticoids or antifungal azoles and can be managed like those with asthma alone.
- The treatment outcomes in ABPA are far better when compared with other causes of bronchiectasis. This emphasizes the need for recognizing the disease early in the course of the illness and instituting appropriate treatment.

Financial & competing interests disclosure

R Agarwal has received grant support from Cipla, India for research in ABPA and consultancy fee from Pulmatrix Inc., USA. The authors have no other relevant affiliations or financial involvement with any organization or entity with a financial interest in or financial conflict with the subject matter or materials discussed in the manuscript apart from those disclosed.

No writing assistance was utilized in the production of this manuscript.

References

Papers of special note have been highlighted as: • of interest; •• of considerable interest

1. Agarwal R. Allergic bronchopulmonary aspergillosis. *Chest* 135(3), 805–826 (2009).
2. Agarwal R, Gupta D, Aggarwal AN, Behera D, Jindal SK. Allergic bronchopulmonary aspergillosis: lessons from 126 patients attending a chest clinic in north India. *Chest* 130(2), 442–448 (2006).
3. Dhooria S, Kumar P, Saikia B *et al.* Prevalence of *Aspergillus* sensitisation in pulmonary tuberculosis-related fibrocavitary disease. *Int. J. Tuberc. Lung Dis.* 18(7), 850–855 (2014).
4. Sehgal IS, Dhooria S, Bal A, Agarwal R. Allergic bronchopulmonary aspergillosis in an adult with Kartagener syndrome. *BMJ Case Rep.* 2015, bcr-2015-211493 (2015).
5. Sehgal IS, Dhooria S, Behera D, Agarwal R. Allergic bronchopulmonary aspergillosis complicating Swyer-James-Macleod's syndrome: case report and review of literature. *Eur. Ann. Allergy Clin. Immunol.* 48(3), 99–102 (2016).
6. Agarwal R, Bhogal S, Choudhary H *et al.* *Aspergillus* sensitisation in bidi smokers with and without chronic obstructive lung disease. *Mycoses* 60(6), 381–386 (2017).

7. Maturu VN, Agarwal R. Prevalence of *Aspergillus* sensitization and allergic bronchopulmonary aspergillosis in cystic fibrosis: systematic review and meta-analysis. *Clin. Exp. Allergy* 45(12), 1765–1778 (2015).
8. Agarwal R, Maskey D, Aggarwal AN *et al.* Diagnostic performance of various tests and criteria employed in allergic bronchopulmonary aspergillosis: a latent class analysis. *PLoS ONE* 8(4), e61105 (2013).
9. Agarwal R, Sehgal IS, Dhooria S, Aggarwal AN. Developments in the diagnosis and treatment of allergic bronchopulmonary aspergillosis. *Expert Rev. Respir. Med.* 10(12), 1317–1334 (2016).
- **Updated review on the diagnosis and treatment of allergic bronchopulmonary aspergillosis.**
10. Muthu V, Singh P, Choudhary H *et al.* Diagnostic cutoffs and clinical utility of recombinant *Aspergillus fumigatus* antigens in the diagnosis of allergic bronchopulmonary aspergillosis. *J. Allergy Clin. Immunol. Pract.* 8(2), 579–587 (2019).
11. Agarwal R, Chakrabarti A, Shah A *et al.* Allergic bronchopulmonary aspergillosis: review of literature and proposal of new diagnostic and classification criteria. *Clin. Exp. Allergy* 43(8), 850–873 (2013).
- **The International Society for Human and Animal Mycology guidelines for the diagnosis and treatment of allergic bronchopulmonary aspergillosis.**
12. Denning DW, Pashley C, Hartl D *et al.* Fungal allergy in asthma-state of the art and research needs. *Clin. Transl. Allergy* 4, 14 (2014).
13. Dhooria S, Agarwal R. Diagnosis of allergic bronchopulmonary aspergillosis: a case-based approach. *Future Microbiol.* 9(10), 1195–1208 (2014).
14. Moss RB. Treatment options in severe fungal asthma and allergic bronchopulmonary aspergillosis. *Eur. Respir. J.* 43(5), 1487–1500 (2014).
- **Excellent article delineating the treatment options in fungal asthma and allergic bronchopulmonary aspergillosis.**
15. Patel AR, Patel AR, Singh S, Singh S, Khawaja I. Treating allergic bronchopulmonary aspergillosis: a review. *Cureus* 11(4), e4538 (2019).
16. Agarwal R, Aggarwal AN, Dhooria S *et al.* A randomised trial of glucocorticoids in acute-stage allergic bronchopulmonary aspergillosis complicating asthma. *Eur. Respir. J.* 47(2), 490–498 (2016).
- **First randomized trial evaluating two different doses of glucocorticoids in acute stages of allergic bronchopulmonary aspergillosis.**
17. Bains SN, Judson MA. Allergic bronchopulmonary aspergillosis. *Clin. Chest Med.* 33(2), 265–281 (2012).
18. Agarwal R, Dhooria S, Sehgal IS *et al.* A randomised trial of voriconazole and prednisolone monotherapy in acute-stage allergic bronchopulmonary aspergillosis complicating asthma. *Eur. Respir. J.* 52(3), (2018).
- **First randomized trial evaluating monotherapy of voriconazole versus prednisolone in acute stages of allergic bronchopulmonary aspergillosis.**
19. Agarwal R, Dhooria S, Singh Sehgal I *et al.* A randomized trial of itraconazole vs prednisolone in acute-stage allergic bronchopulmonary Aspergillosis complicating asthma. *Chest* 153(3), 656–664 (2018).
- **First randomized trial evaluating monotherapy of itraconazole versus prednisolone in acute stages of allergic bronchopulmonary aspergillosis.**
20. Dodamani MH, Muthu V, Thakur R *et al.* A randomised trial of vitamin D in acute-stage allergic bronchopulmonary aspergillosis complicating asthma. *Mycoses* 62(4), 320–327 (2019).
21. Buckley L, Guyatt G, Fink HA *et al.* 2017 American College of Rheumatology guideline for the prevention and treatment of glucocorticoid-induced osteoporosis. *Arthritis Rheumatol.* 69(8), 1521–1537 (2017).
22. Nguyen N, Chen K, Alcorn J, Kolls J. Vitamin D regulation of Th2 immune responses to *Aspergillus fumigatus* in mice and humans: role of OX40L. *J. Immunol.* 188(1), (2012).
23. Nguyen NL, Chen K, Mcleer J, Kolls JK. Vitamin D regulation of OX40 ligand in immune responses to *Aspergillus fumigatus*. *Infect. Immun.* 81(5), 1510–1519 (2013).
24. Nguyen NL, Pilewski JM, Celedon JC *et al.* Vitamin D supplementation decreases *Aspergillus fumigatus* specific Th2 responses in CF patients with aspergillus sensitization: a Phase I open-label study. *Asthma Res. Pract.* 1, 3 (2015).
25. Agarwal R, Aggarwal AN, Sehgal IS, Dhooria S, Behera D, Chakrabarti A. Utility of IgE (total and *Aspergillus fumigatus* specific) in monitoring for response and exacerbations in allergic bronchopulmonary aspergillosis. *Mycoses* 59(1), 1–6 (2016).
26. Agarwal R, Dua D, Choudhary H *et al.* Role of *Aspergillus fumigatus*-specific IgG in diagnosis and monitoring treatment response in allergic bronchopulmonary aspergillosis. *Mycoses* 60(1), 33–39 (2017).
27. Agarwal R, Aggarwal AN, Gupta D. High-attenuation mucus in allergic bronchopulmonary aspergillosis: another cause of diffuse high-attenuation pulmonary abnormality. *AJR Am. J. Roentgenol.* 186(3), 904 (2006).
28. Sehgal IS, Dhooria S, Agarwal R, Behera D. Use of a flexible cryoprobe for removal of tracheobronchial blood clots. *Respir. Care* 60(7), e128–131 (2015).
29. Hogan C, Denning DW. Allergic bronchopulmonary aspergillosis and related allergic syndromes. *Semin. Respir. Crit. Care Med.* 32(6), 682–692 (2011).

30. Agarwal R. What is the current place of azoles in allergic bronchopulmonary aspergillosis and severe asthma with fungal sensitization. *Expert Rev. Respir. Med.* 6(4), 363–371 (2012).
31. Stevens DA, Schwartz HJ, Lee JY *et al.* A randomized trial of itraconazole in allergic bronchopulmonary aspergillosis. *N. Engl. J. Med.* 342(11), 756–762 (2000).
32. Wark PA, Hensley MJ, Salto N *et al.* Anti-inflammatory effect of itraconazole in stable allergic bronchopulmonary aspergillosis: a randomized controlled trial. *J. Allergy Clin. Immunol.* 111(5), 952–957 (2003).
33. Oray M, Abu Samra K, Ebrahimiadib N, Meese H, Foster CS. Long-term side effects of glucocorticoids. *Expert Opin. Drug Saf.* 15(4), 457–465 (2016).
34. Eiden C, Peyriere H, Cociglio M *et al.* Adverse effects of voriconazole: analysis of the French Pharmacovigilance database. *Ann. Pharmacother.* 41(5), 755–763 (2007).
35. Pasqualotto AC, Denning DW. Generic substitution of itraconazole resulting in sub-therapeutic levels and resistance. *Int. J. Antimicrob. Agents* 30(1), 93–94 (2007).
36. Ashbee HR, Barnes RA, Johnson EM, Richardson MD, Gorton R, Hope WW. Therapeutic drug monitoring (TDM) of antifungal agents: guidelines from the British Society for Medical Mycology. *J. Antimicrob. Chemother.* 69(5), 1162–1176 (2014).
37. Zhang J, Liu Y, Nie X, Yu Y, Gu J, Zhao L. Trough concentration of itraconazole and its relationship with efficacy and safety: a systematic review and meta-analysis. *Infect. Drug Resist.* 11, 1283–1297 (2018).
38. Burgel PR, Baixench MT, Amsellem M *et al.* High prevalence of azole-resistant *Aspergillus fumigatus* in adults with cystic fibrosis exposed to itraconazole. *Antimicrob. Agents Chemother.* 56(2), 869–874 (2012).
39. Chowdhary A, Sharma C, Meis JF. Azole-resistant Aspergillosis: epidemiology, molecular mechanisms and treatment. *J. Infect. Dis.* 216(Suppl. 3), S436–S444 (2017).
40. Chowdhary A, Kathuria S, Xu J, Meis JF. Emergence of azole-resistant *Aspergillus fumigatus* strains due to agricultural azole use creates an increasing threat to human health. *PLoS Pathog.* 9(10), e1003633 (2013).
41. Agarwal R, Dhooira S, Aggarwal AN *et al.* Guidelines for diagnosis and management of bronchial asthma: joint ICS/NCCP (I) recommendations. *Lung India* 32(Suppl. 1), S3–S42 (2015).
42. Singh Sehgal I, Agarwal R. Pulse methylprednisolone in allergic bronchopulmonary aspergillosis exacerbations. *Eur. Respir. Rev.* 23(131), 149–152 (2014).
43. Ram B, Aggarwal AN, Dhooira S *et al.* A pilot randomized trial of nebulized amphotericin in patients with allergic bronchopulmonary aspergillosis. *J. Asthma* 53(5), 517–524 (2016).
- **An interesting randomized trial evaluating nebulized amphotericin for maintaining remission in patients with recurrent exacerbations of allergic bronchopulmonary aspergillosis.**
44. Voskamp AL, Gillman A, Symons K *et al.* Clinical efficacy and immunologic effects of omalizumab in allergic bronchopulmonary aspergillosis. *J. Allergy Clin. Immunol. Pract.* 3(2), 192–199 (2015).
- **First crossover randomized trial evaluating the clinical efficacy of omalizumab in allergic bronchopulmonary aspergillosis.**
45. Panettieri RA, Schaafsma D, Amrani Y, Koziol-White C, Ostrom R, Tliba O. Non-genomic effects of glucocorticoids: an updated view. *Trends Pharmacol. Sci.* 40(1), 38–49 (2019).
46. Pasricha JS. Pulse therapy as a cure for autoimmune diseases. *Indian J. Dermatol. Venereol. Leprol.* 69(5), 323–328 (2003).
47. Lebrun-Vignes B, Archer VC, Diquet B *et al.* Effect of itraconazole on the pharmacokinetics of prednisolone and methylprednisolone and cortisol secretion in healthy subjects. *Br. J. Clin. Pharmacol.* 51(5), 443–450 (2001).
48. Li M, Zhu L, Chen L, Li N, Qi F. Assessment of drug–drug interactions between voriconazole and glucocorticoids. *J. Chemother.* 30(5), 296–303 (2018).
49. Dolton MJ, Ray JE, Chen SC, Ng K, Pont LG, McLachlan AJ. Multicenter study of voriconazole pharmacokinetics and therapeutic drug monitoring. *Antimicrob. Agents Chemother.* 56(9), 4793–4799 (2012).
50. Agarwal R, Sehgal IS, Dhooira S, Aggarwal AN. Challenging cases in fungal asthma. *Med. Mycol.* 57(Suppl. 2), S110–S117 (2019).
51. Chishimba L, Langridge P, Powell G, Niven RM, Denning DW. Efficacy and safety of nebulised amphotericin B (NAB) in severe asthma with fungal sensitisation (SAFS) and allergic bronchopulmonary aspergillosis (ABPA). *J. Asthma* 52(3), 289–295 (2015).
52. Otu AA, Langridge P, Denning DW. An evaluation of nebulised amphotericin B deoxycholate (Fungizone((R))) for treatment of pulmonary aspergillosis in the UK National Aspergillosis Centre. *Mycoses* 62(11), 1049–1055 (2019).
53. Agarwal R, Khan A, Aggarwal AN, Gupta D. Is the SMART approach better than other treatment approaches for prevention of asthma exacerbations? A meta-analysis. *Monaldi Arch. Chest Dis.* 71(4), 161–169 (2009).
54. Sehgal IS, Agarwal R. Is treatment of serological ABPA similar to that of ABPA with bronchiectasis? *J. Allergy Clin. Immunol. Pract.* 5(5), 1474 (2017).
55. Altman MC, Lenington J, Bronson S, Ayars AG. Combination omalizumab and mepolizumab therapy for refractory allergic bronchopulmonary aspergillosis. *J. Allergy Clin. Immunol. Pract.* 5(4), 1137–1139 (2017).

56. Terashima T, Shinozaki T, Iwami E, Nakajima T, Matsuzaki T. A case of allergic bronchopulmonary aspergillosis successfully treated with mepolizumab. *BMC Pulm. Med.* 18(1), 53 (2018).
 57. Hirota S, Kobayashi Y, Ishiguro T *et al.* Allergic bronchopulmonary aspergillosis successfully treated with mepolizumab: case report and review of the literature. *Respir. Med. Case Rep.* 26, 59–62 (2019).
 58. Soeda S, Kono Y, Tsuzuki R *et al.* Allergic bronchopulmonary aspergillosis successfully treated with benralizumab. *J. Allergy Clin. Immunol. Pract.* 7(5), 1633–1635 (2019).
 59. Soeda S, To M, Kono Y *et al.* Case series of allergic bronchopulmonary aspergillosis treated successfully and safely with long-term mepolizumab. *Allergol. Int.* 68(3), 377–379 (2019).
 60. Tsubouchi H, Tsuchida S, Yanagi S *et al.* Successful treatment with mepolizumab in a case of allergic bronchopulmonary aspergillosis complicated with nontuberculous mycobacterial infection. *Respir. Med. Case Rep.* 28, 100875 (2019).
 61. Hava DL, Tan L, Johnson P *et al.* A Phase I/Ib study of PUR1900, an inhaled formulation of itraconazole, in healthy volunteers and asthmatics to study safety, tolerability and pharmacokinetics. *Br. J. Clin. Pharmacol.* doi:10.1111/bcp.14166 (2019) (Epub ahead of print).
- **First study evaluating the safety, tolerability and pharmacokinetics of inhaled itraconazole in healthy volunteers and asthmatics.**