

Article abstract—We reviewed the clinical histories, operative results, and neuropathologic findings of 23 consecutive patients who had heart transplants. Prolonged preoperative hypotension and failure of cerebral autoregulation of blood flow, followed by postoperative elevation of blood pressure beyond the limits of cerebral autoregulation, may account for the high incidence of neurologic complications (70%); 60% were vascular. Immunosuppressive therapy may have been responsible for the high incidence (20%) of opportunistic intracranial infections. Lymphoproliferative disorders occurred in three patients (13%).

NEUROLOGY 1986;36:1149-1154

Neuropathology of heart transplantation: 23 cases

Carlos G. Montero, MD, and A. Julio Martinez, MD

The 5-year survival rate of heart transplantation is 50%.¹ To analyze complications, clinicians and pathologists have focused attention on the heart itself, but other organs are also affected, especially the brain.¹⁻³ Hotson and Pedley¹ found that neurologic complications were the primary cause of death in one-fifth of the cases. We have studied 23 consecutive patients.

Materials and methods. We reviewed 13 men (56%) and 10 women (44%) with a mean age of 36 years (range, 16 to 53). Orthotopic heart transplants were performed between July 1981 and June 1985, under moderate (28 °C) hypothermia and cardiopulmonary bypass. In that time, 155 heart transplants were performed at Presbyterian-University Hospital (PUH); on June 30, 1985, 101 patients were still alive (65%). Myocardial protection was done with topical cooling and hypothermic (4 °C) cardioplegia. The perfusion pressure was maintained at a 50- to 80-mm Hg level during the cross-clamp period, which averaged 65 minutes (range, 38 to 114). Mean pump time was 125 minutes (range, 81 to 270). Prophylactic antibiotics were used in all cases and continued for 4 postoperative days. The immunosuppressive protocol consisted of cyclosporin-A (CyA) administered at an initial dose of 17.5 mg/kg before the transplant, and then the dose was adjusted to maintain whole-blood levels of between 800 and 1,000 ng/ml (radioimmunoassay). Methylprednisolone (1 g IV) was given before the patient was taken off the bypass, and continued with 200 mg/d of prednisone on POD 1, tapering down to 20 mg/d by POD 10. For CyA nephrotoxicity, the dose was lowered, and azathioprine was given. Endomyocardial-biopsy-proven rejection was treated with bolus of methylprednisolone (1 g/d x3 IV), and rabbit antithymocyte globulin (100 mg/d x3 IM) was given if rejection persisted.

In all 23 cases, the brain and spinal cord were studied

macro- and microscopically after 10% formaldehyde fixation for at least 14 days. Histologic sections of the CNS from different areas including the pituitary gland were studied with hematoxylin and eosin (H-E) and other special stains when indicated.

Results. Cerebrovascular complications. No neuropathologic lesions were found in four cases (17%). Most cerebral lesions were vascular (60%) or infectious (20%) (table 1). In six cases (26%), lesions were considered secondary to circulatory collapse (postoperative hypotension, decreased cardiac output, or increased peripheral vascular resistance).

Vascular lesions (thrombosis, embolism, old or recent infarcts, and recent hemorrhages) were found in 10 cases (43%). Persistent cardiac rejection was present throughout the clinical course in case 4. Rejection was not observed in case 19 because he died 15 hours after transplantation. Neither patient had clinical manifestations of the cerebral lesions. Infarct of the adenohypophysis and ischemic-anoxic neuronal changes were found in case 4. Recent hemorrhage and infarct of the right parietal lobe with platelet thrombi and ischemic-anoxic changes were found in case 19. Case 4 died of an acute myocardial infarct, and case 19 died because of acute right heart failure and shock.

Case 2 died 20 days after the transplant. Obtundation, right hemiplegia, and seizures began 10 days before the heart transplant, and an old infarct of the right thalamus and a recent infarct of the left putamen were found (figure 1). Laminar cortical necrosis was also found on the occipital cortices. Case 3 had been on aortic balloon counterpulsation before the heart transplant. She developed thrombosis of the aortic arch and descending aorta, which was unnoticed during the cross clamping. In the immediate postoperative period, emboli lodged in the right femoral artery, which was re-

From the Department of Cardiothoracic Surgery (Dr. Montero) and Division of Neuropathology (Dr. Martinez), Presbyterian-University Hospital, Pittsburgh, PA. Supported in part by a grant from Spanish Insalud of the Ministry of Health, no. 84-6.

Dr. Carlos G. Montero was a recipient of a grant from Fondo de Investigaciones Sanitarias de la Seguridad Social of Spain (FISS).

Accepted for publication January 8, 1986.

Address correspondence and reprint requests to Dr. Martinez, Division of Neuropathology, Presbyterian University Hospital, DeSoto at O'Hara Streets, Pittsburgh, PA 15213.

Table 1. Neuropathologic findings in heart transplantation

Case no.	Sex/age	Neurologic manifestations	Survival interval (days)	Cause of death	Neuropathologic findings
PA-81-173 (1)	M/36	None	360	Right ventricular failure, pulmonary hypertension	NPC, pituitary siderosis
PA-81-201 (2)	M/38	Obtundation, seizures, right hemiplegia	20	Sepsis, secondary to small bowel necrosis	Infarct, old, right thalamus; infarct, recent, left putamen & insular cortex; laminar cortical necrosis
PA-82-46 (3)	F/52	Fatigue, seizures, right hemiparesis	17	Intracerebral hemorrhage	Hemorrhage, recent, right & left occipital; infarcts, old and recent, cerebral hemispheres, pons, and cerebellum
PA-82-120 (4)	M/48	None	350	Chronic rejection, acute myocardial infarct	Pituitary infarct, ischemic-anoxic neuronal changes
PA-82-135 (5)	F/31	None	50	Acute rejection, disseminated; toxoplasmosis	<i>Toxoplasma gondii</i> encephalitis, pituitary infarct, pituitary microadenoma
PA-82-136 (6)	F/25	Seizures, hyperflexia, CC	1	Acute myocardial infarct	NPC
PA-82-163 (7)	M/48	Fatigue, nausea, headache, CC	420	Chronic rejection, pulmonary fibrosis, heart failure	Infarct, old, left frontal & left basal ganglia
PA-82-206 (8)	M/22	Obtundation, CC	350	Sepsis, lymphoma	Infarct, old, right temporal
PA-83-2 (9)	F/41	Seizures	33	Overwhelming infection (candidiasis & toxoplasmosis), polymicrobial bronchopneumonia	<i>Toxoplasma gondii</i> encephalitis, cerebral candidiasis
PA-83-52 (10)	M/34	Headache, tremor, seizures, coma	150	Pancreatitis, pneumonitis, renal failure	Infarcts, old, left temporal & left insula; leptomeningitis, subsiding; pituitary siderosis (<i>Listeria monocytogenes</i>)
PA-83-61 (11)	F/50	Obtundation, CC	8	Hyperacute rejection, congestive cardiomyopathy	Ischemic-anoxic neuronal changes
PA-83-67 (12)	M/53	Seizures, coma, CC	44	Renal failure, pulmonary abscess, DIC, pulmonary thrombosis	Astrocytosis, focal; phagocytic nodules
PA-83-77 (13)	M/51	Fatigue, seizures, obtundation	180	Sepsis, renal failure, lymphoproliferative pneumonitis	Cerebral aspergillosis, right frontal
PA-83-110 (14)	M/20	Obtundation	173	Pulmonary cryptococcosis, lymphoma, ileal perforation, acute peritonitis, ARDS	Infarcts, old, right & left basal ganglia
PA-83-132 (15)	F/44	Seizures	72	Renal failure, acute	Ischemic-anoxic neuronal changes, ganglia

CC Circulatory collapse, postoperative hypoperfusion, or low cardiac output.
ARDS Adult Respiratory Distress Syndrome
NPC No pathologic changes.
DIC Disseminated intravascular coagulation

Case no.	Sex/age	Neurologic manifestations	Survival interval (days)	Cause of death	Neuropathologic findings
PA-84-1 (19)	F/29	Obtundation	26	ARDS; beta thalassemia major	Pituitary siderosis
PA-84-4 (17)	F/52	None	1	Hyperacute rejection, sarcoidosis	NPC
PA-84-55 (18)	M/16	Seizures	14	ARDS, pseudomonas pneumonia, renal failure, sepsis	Cerebral aspergillosis, Alzheimer type II astrocytosis, frontal hematomas, left middle frontal & left parieto-occipital
PA-84-148 (19)	M/20	None	0.5 (15 hrs)	Acute right heart failure & ARDS	Infarct, recent, right, parietal, small; ischemic-anoxic neuronal changes
PA-84-133 (20)	M/36	Transitory aphasia	6	Bronchopneumonia, sepsis	Ischemic-anoxic changes
PA-85-28 (21)	M/36	Seizures	86	Rejection, acute	Subarachnoid petechial hemorrhages; infarct, small, old, thoracic spinal cord
PA-85-54 (22)	F/17	None	1	Hyperacute rejection, familial hyperlipidemia	Pituitary siderosis; infarcts, right frontal, recent, small
PA-85-96 (23)	F/37	None, CC	1/3 (5 hrs)	Hyperacute rejection, heart failure	NPC

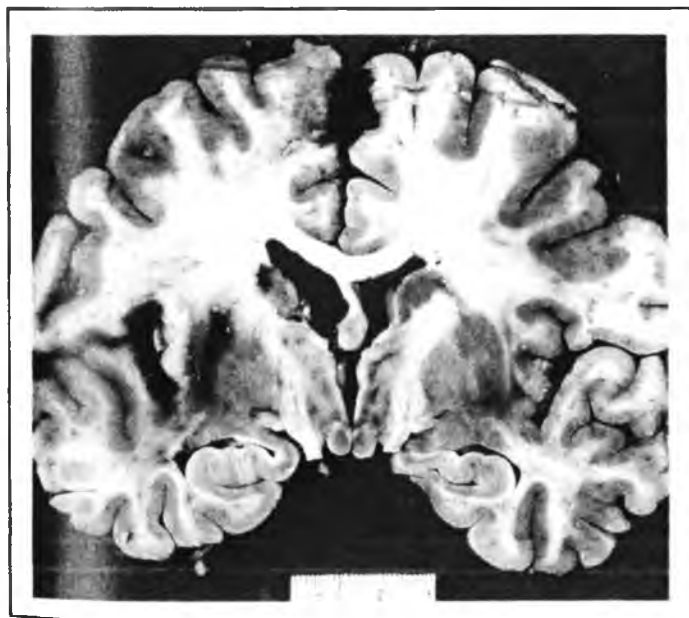

Figure 1 Recent hemorrhagic infarct of the left putamen, the insular cortex, and on both superior frontal gyri, mesial surface (case 2).

moved, and in the left carotid artery, which was responsible for a right hemiplegia and seizures. The cerebral hemispheres showed left parietal hemorrhagic infarct (figure 2) and other infarcts in the right occipital cortex.

In cases 1, 10, 16, and 22, there was siderosis of the pituitary gland, probably due to numerous blood transfusions. Obtundation was noted in cases 2, 8, 11, 13, 14 and 16. Case 21 had small subarachnoid and a focal, subdural hemorrhage and two episodes of cardiac rejection.

Seizures were present in nine cases (39%) and transitory aphasia in one (case 20). Case 22 was a 17-year-old girl with a type II-familial hypercholesterolemia. For coronary and valve disease, she had three open-heart procedures: mitral and aortic valve replacement, left ventricular outflow tract enlargement, and replacement of the prosthetic aortic valve that became infected. After severe dyspnea and refractory congestive heart failure, she was considered for a combined heart/liver transplant. Femorocaval venous bypass and aortic return was used, and in a 10-hour flawless operation she received both organs. In the next 48 hours she was treated for mediastinal bleeding, cardiac tamponade, and abdominal compression that was relieved by partial hepatectomy. Eventually both organs had to be replaced again for continuing low cardiac output and liver damage, but she could not be weaned from bypass and she died 1 day after surgery. Multiple recent infarcts of the right frontal cerebral cortex, diffuse ischemic-anoxic neuronal changes, and siderosis of the neurohypophysis were found. Circulatory collapse was thought to be the main cause of neurologic symptoms in six patients (26%).

CNS infections. Systemic cytomegalovirus (CMV) infection occurred in one case (no. 10), but without cerebral lesions. Diagnosis was based on serologic studies and culture. The findings included old infarcts in the temporal and insular cortices, astrocytosis, and chronic "subsiding" leptomenigitis. No phagocytic nodules or inclusion bodies were seen. The infection occurred 112 days after the transplant, at which time there was also a *Candida* sp pneumonia. Neurologically, he had frontal headache and tremor, progressing to seizures and coma.

Case no.	Sex/age	Neurologic manifestations	Survival interval (days)	Cause of death	Neuropathologic findings
PA-84-1 (16)	F/29	Obtundation	26	ARDS; beta thalassemia major	Pituitary siderosis
PA-84-4 (17)	F/52	None	1	Hyperacute rejection, sarcoidosis	NPC
PA-84-55 (18)	M/16	Seizures	14	ARDS, pseudomonas pneumonia, renal failure, sepsis	Cerebral aspergillosis, Alzheimer type II astrocytosis, frontal hematomas, left middle frontal & left parieto-occipital
PA-84-148 (19)	M/20	None	0.5 (15 hrs)	Acute right heart failure & ARDS	Infarct, recent, right, parietal, small; ischemic-anoxic neuronal changes
PA-84-133 (20)	M/36	Transitory aphasia	6	Bronchopneumonia, sepsis	Ischemic-anoxic changes
PA-85-28 (21)	M/36	Seizures	86	Rejection, acute	Subarachnoid petechial hemorrhages; infarct, small, old, thoracic spinal cord
PA-85-54 (22)	F/17	None	1	Hyperacute rejection, familial hyperlipidemia	Pituitary siderosis; infarcts, right frontal, recent, small
PA-85-96 (23)	F/37	None, CC	1/3 (5 hrs)	Hyperacute rejection, heart failure	NPC

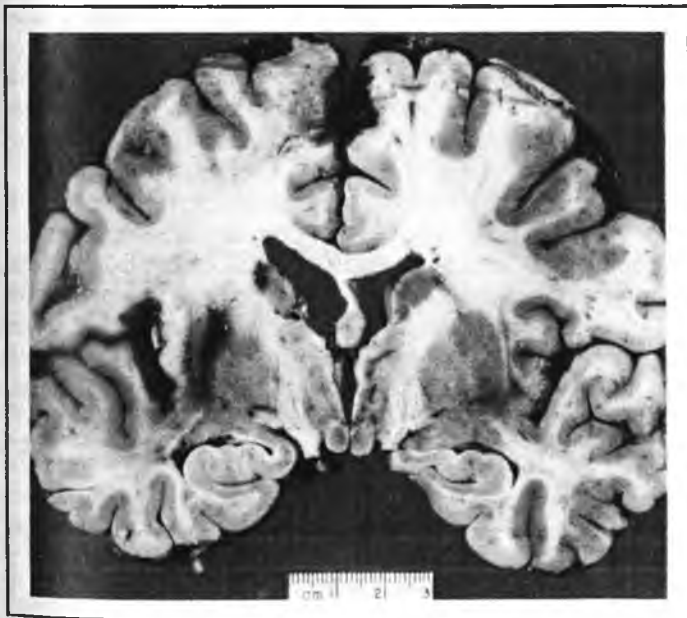

Figure 1. Recent hemorrhagic infarct of the left putamen, the insular cortex, and on both superior frontal gyri, mesial surface (case 2).

moved, and in the left carotid artery, which was responsible for a right hemiplegia and seizures. The cerebral hemispheres showed left parietal hemorrhagic infarct (figure 2) and other infarcts in the right occipital cortex.

In cases 1, 10, 16, and 22, there was siderosis of the pituitary gland, probably due to numerous blood transfusions. Obtundation was noted in cases 2, 8, 11, 13, 14 and 16. Case 21 had small subarachnoid and a focal, subdural hemorrhage and two episodes of cardiac rejection.

Seizures were present in nine cases (39%) and transitory aphasia in one (case 20). Case 22 was a 17-year-old girl with a type II-familial hypercholesterolemia. For coronary and valve disease, she had three open-heart procedures: mitral and aortic valve replacement, left ventricular outflow tract enlargement, and replacement of the prosthetic aortic valve that became infected. After severe dyspnea and refractory congestive heart failure, she was considered for a combined heart/liver transplant. Femorocaval venous bypass and aortic return was used, and in a 10-hour flawless operation she received both organs. In the next 48 hours she was treated for mediastinal bleeding, cardiac tamponade, and abdominal compression that was relieved by partial hepatectomy. Eventually both organs had to be replaced again for continuing low cardiac output and liver damage, but she could not be weaned from bypass and she died 1 day after surgery. Multiple recent infarcts of the right frontal cerebral cortex, diffuse ischemic-anoxic neuronal changes, and siderosis of the neurohypophysis were found. Circulatory collapse was thought to be the main cause of neurologic symptoms in six patients (26%).

CNS infections. Systemic cytomegalovirus (CMV) infection occurred in one case (no. 10), but without cerebral lesions. Diagnosis was based on serologic studies and culture. The findings included old infarcts in the temporal and insular cortices, astrocytosis, and chronic "subsiding" leptomenigitis. No phagocytic nodules or inclusion bodies were seen. The infection occurred 112 days after the transplant, at which time there was also a *Candida* sp pneumonia. Neurologically, he had frontal headache and tremor, progressing to seizures and coma.

Fungal organisms were isolated in the lung, but not in the brain.

Aspergillus infection was recognized in two cases, nos. 13 and 18 (table 2), both disseminated from a pulmonary focus. A large area of hemorrhagic encephalomalacia was present in case 13 (figure 3). Case 18 showed severe cerebral edema and, in both cases, the fungi could be identified surrounding blood vessel walls, protruding into the lumen and causing thrombosis. The inflammatory response was minimal. Alzheimer type II astrocytosis was also present in case 18.

Toxoplasma gondii encephalitis was found in two cases (nos. 5 and 9). In case 5, the protozoa were found 28 days after the heart transplant (figure 4). Neurologically, the infection was silent. Cardiac rejection was treated on three occasions. Diagnosis was established by the immunofluorescence antibody technique. Death occurred 12 days later. CT showed no lesions, and CSF was normal. Postmortem examination disclosed the typical *Toxoplasma* pseudocysts and tachyzoites

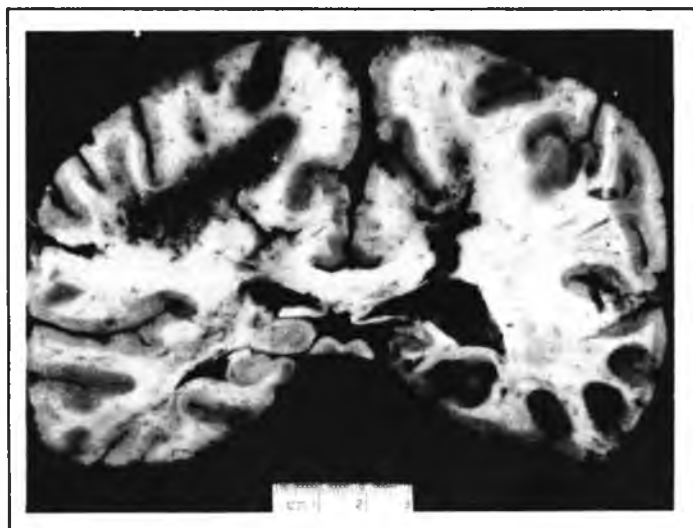

Figure 2. Hemorrhagic infarct on the subcortical white matter of the left parietal lobe. There are also small cortical infarcts on the right calcarine and occipital cortices (case 3).

(figure 4) intra- and extracellularly. A recent infarct of the adenohypophysis and numerous phagocytic nodules and a chromophobic microadenoma of the hypophysis were also present in case 5. The myocardium showed toxoplasmic myocarditis. This probably preceded the CNS infection. In case 9, both *Toxoplasma gondii* and *Candida* spp were present in CNS tissue.

No CNS lymphoma was encountered. There were three patients with systemic lymphoproliferative disorders (two with lymphoma and one with lymphoproliferative pneumonitis).

Discussion. The neuropathologic findings of these cases were similar to those that follow renal transplantation.⁶ Hypertension and encephalopathy are rare in heart transplant recipients. However, there are usually transient and immediate postoperative hypertensive episodes in cardiac transplant patients. Vascular lesions are probably due to surgery, rejection, or immunosuppression,¹ or secondary to hypoperfusion or low cardiac output.

The high incidence of vascular complications (60%) suggests that chronic preoperative hypotension, followed by changes in the hemodynamics of blood flow and possibly a short period of postoperative, transient hypertension, impedes cerebral autoregulation. These factors probably acted in combination with low-viscosity of the blood, insensitivity of atrial and aortic receptors, and possible ischemic-anoxic damage to the neurons during the cardiopulmonary bypass. This induces moderately elevated blood pressure that exceeded the threshold of cerebral autoregulation, and resulted in vascular complications (hemorrhages, infarcts, thrombosis, and embolism).

The high incidence of opportunistic infection (20%) was attributed to depressed immune status.⁷⁻¹² *Aspergillus* infection was found in two cases, both after pulmonary infection. CNS aspergillosis is suspected when there are cerebral symptoms in a patient with known pulmonary lesions. CT may reveal the cerebral lesion, but findings are usually nonspecific, and it must be repeated frequently to disclose variation in size. CSF

Table 2. Infection of central nervous system in cardiac transplant recipients

Case no.	Organism	Associated disorders	Time post-Tx (days)	Primary site	Mode of diagnosis
5	<i>Toxoplasma gondii</i>	Sepsis	28	Heart	IFAT
13	<i>Aspergillus</i>	EBV, CMV	177	Lung	Culture, postmortem
10	CMV <i>Listeria monocytogenes</i>	Diabetes, renal failure	112	Lung	Serology
18	<i>Aspergillus</i>	DICS renal failure	6	Lung	Culture, postmortem
9	<i>Toxoplasma gondii</i> Candidiasis	Polymicrobial sepsis	33	Lung	Serology, postmortem tissue

Tx Cardiac transplantation.
 IFAT Immunofluorescent antibody technique.
 EBV Epstein-Barr virus.
 CMV Cytomegalovirus.
 DICS Disseminated intravascular coagulation syndrome.

Fungal organisms were isolated in the lung, but not in the brain.

Aspergillus infection was recognized in two cases, nos. 13 and 18 (table 2), both disseminated from a pulmonary focus. A large area of hemorrhagic encephalomalacia was present in case 13 (figure 3). Case 18 showed severe cerebral edema and, in both cases, the fungi could be identified surrounding blood vessel walls, protruding into the lumen and causing thrombosis. The inflammatory response was minimal. Alzheimer type II astrocytosis was also present in case 18.

Toxoplasma gondii encephalitis was found in two cases (nos. 5 and 9). In case 5, the protozoa were found 28 days after the heart transplant (figure 4). Neurologically, the infection was silent. Cardiac rejection was treated on three occasions. Diagnosis was established by the immunofluorescence antibody technique. Death occurred 12 days later. CT showed no lesions, and CSF was normal. Postmortem examination disclosed the typical *Toxoplasma* pseudocysts and tachyzoites

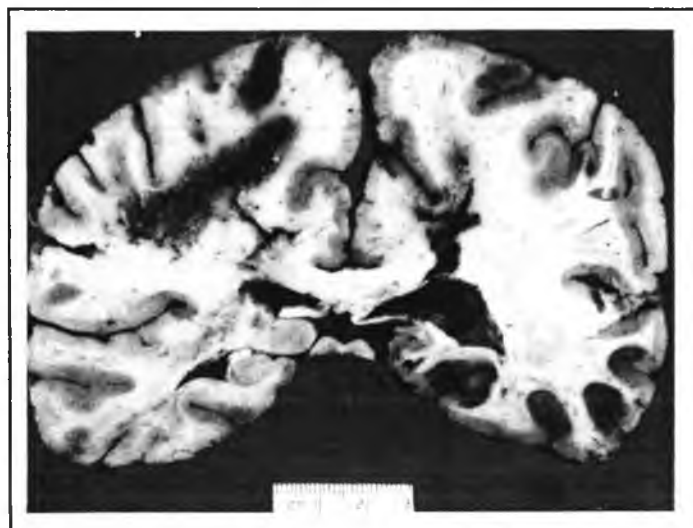


Figure 2. Hemorrhagic infarct on the subcortical white matter of the left parietal lobe. There are also small cortical infarcts on the right calcarine and occipital cortices (case 3).

(figure 4) intra- and extracellularly. A recent infarct of the adenohypophysis and numerous phagocytic nodules and a chromophobic microadenoma of the hypophysis were also present in case 5. The myocardium showed toxoplasmic myocarditis. This probably preceded the CNS infection. In case 9, both *Toxoplasma gondii* and *Candida* spp were present in CNS tissue.

No CNS lymphoma was encountered. There were three patients with systemic lymphoproliferative disorders (two with lymphoma and one with lymphoproliferative pneumonitis).

Discussion. The neuropathologic findings of these cases were similar to those that follow renal transplantation.⁶ Hypertension and encephalopathy are rare in heart transplant recipients. However, there are usually transient and immediate postoperative hypertensive episodes in cardiac transplant patients. Vascular lesions are probably due to surgery, rejection, or immunosuppression,³ or secondary to hypoperfusion or low cardiac output.

The high incidence of vascular complications (60%) suggests that chronic preoperative hypotension, followed by changes in the hemodynamics of blood flow and possibly a short period of postoperative, transient hypertension, impedes cerebral autoregulation. These factors probably acted in combination with low-viscosity of the blood, insensitivity of atrial and aortic receptors, and possible ischemic-anoxic damage to the neurons during the cardiopulmonary bypass. This induces moderately elevated blood pressure that exceeded the threshold of cerebral autoregulation, and resulted in vascular complications (hemorrhages, infarcts, thrombosis, and embolism).

The high incidence of opportunistic infection (20%) was attributed to depressed immune status.^{7, 12} *Aspergillus* infection was found in two cases, both after pulmonary infection. CNS aspergillosis is suspected when there are cerebral symptoms in a patient with known pulmonary lesions. CT may reveal the cerebral lesion, but findings are usually nonspecific, and it must be repeated frequently to disclose variation in size. CSF

Table 2. Infection of central nervous system in cardiac transplant recipients

Case no.	Organism	Associated disorders	Time post-Tx (days)	Primary site	Mode of diagnosis
5	<i>Toxoplasma gondii</i>	Sepsis	28	Heart	IFAT
13	<i>Aspergillus</i>	EBV, CMV	177	Lung	Culture, postmortem
10	CMV <i>Listeria monocytogenes</i>	Diabetes, renal failure	112	Lung	Serology
18	<i>Aspergillus</i>	DICS renal failure	6	Lung	Culture, postmortem
9	<i>Toxoplasma gondii</i> Candidiasis	Polymicrobial sepsis	33	Lung	Serology, postmortem tissue

Tx Cardiac transplantation.
 IFAT Immunofluorescent antibody technique.
 EBV Epstein-Barr virus.
 CMV Cytomegalovirus.
 DICS Disseminated intravascular coagulation syndrome.

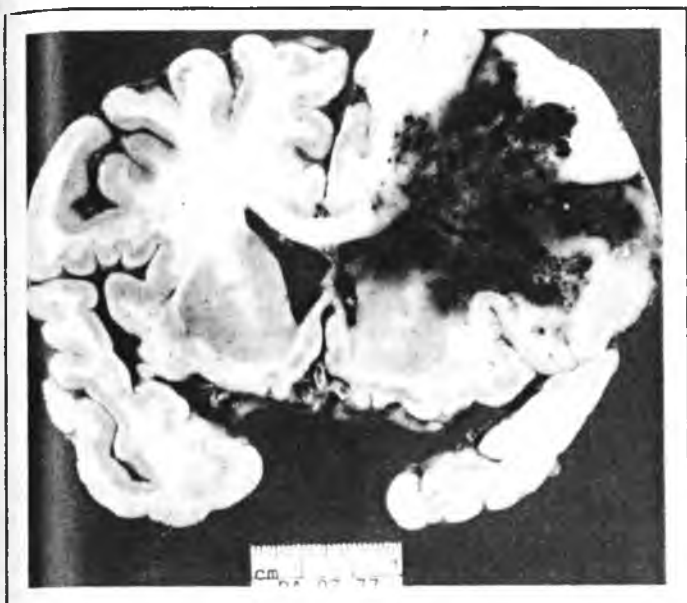


Figure 3. A large area of hemorrhagic encephalomalacia due to aspergillosis on the right cerebral hemisphere (case 13).

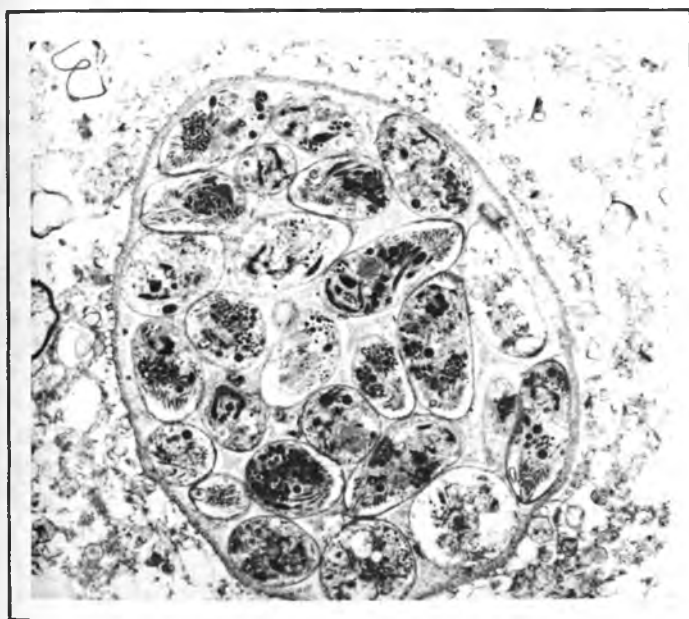


Figure 4. Cerebral toxoplasmosis. *Toxoplasma gondii* pseudocyst filled with tachyzoites. Electronmicrograph (case 5). $\times 4,500$ before 21% reduction.

examination has not been helpful, and cultures do not tend to grow the microorganisms. Therefore, needle aspiration, stereotactic needle biopsy, or even open craniotomy of a cerebral lesion demonstrated by CT is required for premortem diagnosis, although the clinical course, once the CNS is involved by *Aspergillus* or other microorganism, is usually fatal.^{8,9} Despite success in some cases of *Aspergillus* infection in renal recipients,⁶ amphotericin B and 5-fluorocytosine have not been effective in CNS infections with this organism.

Toxoplasma spp also invades the CNS in immunocompromised hosts,^{13,16} and the transplanted heart may be a source of latent infection.¹⁶ The organism could spread from graft to blood stream and brain or menin-

ges. In immunocompromised patients, Ruskin and Remington¹⁷ found that infection was recognized before death in only 20% of the cases, and those cases had diffuse encephalopathy, meningoencephalitis, or a progressively enlarging focal brain lesion. Treatment with pyrimethamine and trimethoprim sulfamethoxazole (TMP-SMZ) has resulted in clinical improvement in 80% of the cases.

Aspergillus, Epstein-Barr virus (EBV), and CMV were all involved in one patient (table 2). Immunosuppression in heart transplant recipients may result not only in a higher susceptibility to opportunistic infections but also in an enhanced risk for neoplasms. This is a consequence of decreased antibody formation by selective killing of lymphocytes and reduction in the number of germinal centers in lymph nodes and spleen. Inflammatory response as well as delayed hypersensitivity and interferon production is also suppressed by azathioprine and steroids. Steroids also depress the bactericidal action of neutrophils, alveolar macrophages, and monocytes; antithymocyte globulins, whether equine- or rabbit-derived, have a deleterious effect on T-cell lymphocytes and reticuloendothelial system.^{10,11} CyA is a nephrotoxic agent¹⁸ and has a positive effect on suppressor T cells, inhibiting the induction of cytotoxic cells and decreasing the humoral response to cell proliferation.¹⁹ The opportunistic infections often accompany rejection when immunosuppression is maximal.^{7,11,12,18,19}

The risk of neoplasms in immunocompromised hosts is between 2 and 10%.²⁰ Lymphomas constitute most of these lymphoproliferative disorders. We encountered three cases with lymphoproliferative disorders without CNS involvement (13%).^{4,20,21}

Neurologic symptoms affected 70% of our patients. Vascular lesions (60%) and infections (20%) were most frequent. Infective organisms were those of usually low pathogenicity. Clinicians must be alert when mild mental impairment appears in the immediate postoperative period, or when unexplained personality changes occur later. Infection must be considered even in the absence of fever or CSF abnormalities and appropriate search should be instituted urgently, because prognosis is poor once the CNS is involved, especially by *Aspergillus*. Aggressive treatment of pulmonary infections must be carried out expeditiously, for they usually herald CNS infection. IFAT must be done routinely to rule out *Toxoplasma* infection, and Gram's stain and india ink preparation may also be useful. Low cardiac output states should be corrected urgently. Care must be taken with symptoms of so-called "metabolic encephalopathy" or "ICU neurosis," which may disguise an underlying infection.

Acknowledgments

We thank Drs. Bartley P. Griffith, Robert L. Hardesty, and Henry T. Bahnson, Department of Surgery, Division of Cardiothoracic Surgery, University of Pittsburgh, School of Medicine for the clinical information on this series. We also thank Drs. Mamdouha Ahdab-Barmada, neuropathologist at University Health Center of Pittsburgh (UHCP), Bicher Barmada, Chief, Cardiothoracic Division, St. Francis Hospital, and Amin Faris, neurologist at UHCP for helpful suggestions during the preparation of the manuscript.

References

1. Griffith BP, Hardesty RL, Bahnson HT. Powerful but limited immunosuppression for cardiac transplantation with cyclosporine and low-dose steroid. *J Thorac Cardiovasc Surg* 1984;87:35-42.
2. Hardesty RL, Griffith BP, Debski RF, Bahnson HT. Experience with cyclosporine in cardiac transplantation. *Transplant Proc* 1983;14(suppl 1):2553-8.
3. Hardesty RL, Griffith BP, Deeb GM, Bahnson HT, Starzl TE. Improved cardiac function using cardioplegia during procurement and transplantation. *Transplant Proc* 1983;15:1253-5.
4. Hotson JR, Pedley TA. The neurological complications of cardiac transplantation. *Brain* 1976;99:673-94.
5. Schober R, Herman MM. Neuropathology in cardiac transplantation: survey of 31 cases. *Lancet* 1973;1:962-7.
6. Burton JR, Zachery JB, Bessin R, et al. Aspergillosis in 4 renal transplant patients: diagnosis and effective treatment with Amphotericin B. *Ann Intern Med* 1972;77:383-8.
7. Baumgartner WA. Infection in cardiac transplantation. *Heart Transplant* 1983;3:75-80.
8. Britt RH, Enzmann DR, Remington JS. Intracranial infection in cardiac transplant recipients. *Ann Neurol* 1981;9:107-19.
9. Gurwith MJ, Stinson EB, Remington JS. *Aspergillus* infection complicating cardiac transplantation: report of 5 cases. *Arch Intern Med* 1971;128:54-5.
10. Hooper DC, Pruitt AA, Rubin RH. Central nervous system infection in the chronically immunosuppressed. *Medicine (Baltimore)* 1982;61:166-88.
11. Mason JW, Stinson EB, Hunt SA, et al. Infections after cardiac transplantation. Relation to rejection therapy. *Ann Intern Med* 1976;6:468-75.
12. Reece JJ, Painvin GA, Zeluff B, et al. Infection in cyclosporine-immunosuppressed cardiac allograft recipients. *Heart Transplant* 1984;3:239-49.
13. Frenkel JK, Nelson BM, Arias-Stella J. Immunosuppression and toxoplasmic encephalitis. Clinical and experimental aspects. *Hum Pathol* 1975;6:97-111.
14. Ghatak NR, Sawyer DR. A morphologic study of opportunistic cerebral toxoplasmosis. *Acta Neuropathol (Berl)* 1978;42:217-21.
15. Powell HC, Gibbs CJ, Lorenzo AM, Lampert PW, Gajdusek DC. Toxoplasmosis of the central nervous system in the adult: electron microscopic observations. *Acta Neuropathol (Berl)* 1978;41:211-6.
16. Rynning FW, McLeod R, Maddox JC, et al. Probable transmission of *Toxoplasma gondii* by organ transplantation. *Ann Intern Med* 1979;90:47-9.
17. Ruskin J, Remington JS. Toxoplasmosis in the compromised patient. *Ann Intern Med* 1976;84:193-9.
18. Borel JF, Feurer C, Gubler HU, et al. Biological effects of Cyclosporin A: a new antilymphocytic agent. *Agents and Actions* 1976;6:468-75.
19. Hess AD, Tutschka PJ, Santos GW. The effect of cyclosporin-A on T-lymphocyte subpopulations. In: White DJG, ed. *Cyclosporin A*. New York: Elsevier Biomedical Press, 1982:208-31.
20. Penn I. Problems of cancer in organ transplantation. *Heart Transplant* 1982;2:71-7.
21. Lanza RP, Cooper DKC, Cassidy MJD, Barnard CN. Malignant neoplasms occurring after cardiac transplantation. *JAMA* 1983;249:1746-8.