

Pulmonary Cavitation and Massive Hemoptysis in Invasive Pulmonary Aspergillosis

Influence of Bone Marrow Recovery in Patients with Acute Leukemia^{1,2}

STEVEN M. ALBELDA, GEORGE H. TALBOT, STANTON L. GERSON, WALLACE T. MILLER, and PETER A. CASSILETH

Introduction

Opportunistic pulmonary infections are a leading cause of morbidity and mortality in immunocompromised hosts (1). Fungal pneumonias, particularly invasive pulmonary aspergillosis (IPA), have become increasingly common (2, 3). Although IPA occurs in a variety of immunocompromised patients and occasionally in normal individuals, 50 to 70% of reported cases have been associated with acute leukemia (4-7). Furthermore, IPA has been discovered at autopsy in as many as 15 to 20% of patients dying with acute leukemia (3,8).

Although IPA was once a uniformly fatal disease (4,6), early diagnosis and treatment with amphotericin B can lead to recovery from the infection (5, 7, 9, 10), at least in those leukemic patients in whom chemotherapy-induced granulocytopenia resolves. Thus, there is a group of patients with acute leukemia who attain hematologic remission and survive *Aspergillus* pneumonia. The information available about the clinical characteristics of this group of patients is limited because previous large clinical studies were primarily autopsy-derived series (2-4, 6, 8, 11). Similarly, most of the descriptions of the radiographic appearance of IPA have been based on data obtained from patients in whom the diagnosis of IPA was made by autopsy (11-14).

Over the past four and one half years, 27 patients with acute leukemia and IPA have been treated in the Oncology Study Unit of the Hospital of the University of Pennsylvania. Although bone marrow recovery was critical for patient survival, we observed that the period immediately after recovery from granulocytopenia was associated with marked changes in the radiographic appearance of the pulmonary infiltrates and on occasion with

SUMMARY The influence of bone marrow recovery on the clinical and radiographic course of invasive pulmonary aspergillosis in patients with acute leukemia has not been well characterized. We studied 26 patients with acute leukemia and invasive pulmonary aspergillosis, comparing those who recovered from chemotherapy-induced granulocytopenia (Group 1, 15 patients) with those who did not (Group 2, 11 patients). Radiographic evidence of pulmonary cavitation was not seen in any Group 2 patient, but developed in 11 of 15 (73%) Group 1 patients ($p < 0.005$). In these patients, cavitation always occurred after marrow recovery, an average of 2.0 days (range: 0 to 6 days) after the granulocyte count exceeded $500/\text{mm}^3$. Eight patients in Group 1 and 2 in Group 2 experienced a total of 38 episodes of hemoptysis. Four of the 26 patients, all in Group 1, developed massive hemoptysis (>150 ml of blood per episode), leading to 1 death. In 3 of these 4 patients, cavitation preceded the episode of massive hemoptysis. At the time of massive bleeding, the granulocyte count was $>500/\text{mm}^3$, the platelet count $>38,000/\text{mm}^3$, and the other coagulation parameters were normal in all 4 patients. Our findings demonstrate that in patients with acute leukemia undergoing chemotherapy, bone marrow recovery markedly influences the clinical and radiographic course of invasive pulmonary aspergillosis. Development of a granulocyte count $>500/\text{mm}^3$ is associated with pulmonary cavitation, and on occasion with massive hemoptysis.

AM REV RESPIR DIS 1985; 131:115-120

the occurrence of massive hemoptysis, supposedly an uncommon complication of IPA (15). This paper examines differences between the radiographic and clinical courses of patients with IPA and acute leukemia who recovered from granulocytopenia and those who did not.

Methods

Incidences of IPA among patients hospitalized in the Oncology Study Unit between July 1, 1978 and December 31, 1982 were identified by retrospective review of all patients admitted prior to November 1980 and by prospective evaluation of all subsequently admitted patients. Invasive pulmonary aspergillosis was diagnosed in 27 of 130 adult patients with acute leukemia (including chronic myelogenous leukemia in blast crisis) admitted during the study period. Data were collected by review of the patient's chart, pathology records, the bronchoscopy suite logbook, and the mycology laboratory logbook. The results of fiberoptic bronchoscopy in these patients have been reported elsewhere (16), as have analyses of risk factors for IPA (17), utility of *Aspergillus* antigen detection (18), and other clinical features (19).

Review and interpretation of the chest radiographs were performed by one of the inves-

tigators (WTM) without knowledge of the clinical course of the patients. Radiographically defined pulmonary infiltrates were characterized as having one of the following patterns: (1) nodule(s); (2) cavitory alveolar infiltrate(s) (cavities); (3) wedge-shaped, pleural-based defect(s); (4) nonspecific alveolar infiltrate(s); (5) diffuse lung disease; or (6) "miliary" pattern (diffuse, finely nodular pattern).

All physicians' and nurses' progress notes were examined for information regarding the presence and quantity of hemoptysis. Hemoptysis was graded as follows: massive (greater than 150 ml of blood per episode), intermediate (between 20 and 150 ml blood per epi-

(Received in original form March 28, 1984 and in revised form June 1, 1984)

¹ From the Cardiovascular-Pulmonary Division, Infectious Diseases Section, and Hematology-Oncology Section, Department of Medicine and the Department of Radiology, Hospital of the University of Pennsylvania, University of Pennsylvania School of Medicine, Philadelphia, Pennsylvania.

² Requests for reprints should be addressed to Dr. George H. Talbot, Hospital of the University of Pennsylvania, 3400 Spruce St., Philadelphia, PA 19104.

sode), and minor (20 ml or less of blood per episode).

Patients were placed into 1 of 2 groups for analysis. Patients who received chemotherapy, developed granulocytopenia (defined as a granulocyte count $<500/\text{mm}^3$), and then recovered from granulocytopenia were designated as Group 1. These patients did not necessarily achieve complete remission of their leukemia. Those patients who received chemotherapy, developed granulocytopenia, but never recovered granulocyte counts greater than $500/\text{mm}^3$ were designated as Group 2. One patient who never received chemotherapy during the admission in which IPA developed was placed in the latter group. One patient was not included in the final study group because of transfer to another hospital early in the course of her illness.

Data were analyzed for significance by the two-tailed Fisher exact test, Mann-Whitney ranked sum test, or by the Kruskal-Wallis non-parametric statistic. Values of $p < 0.05$ were considered significant.

Results

Twenty-one patients had acute myelogenous leukemia; 13 of these were undergoing initial treatment. A variety of chemotherapeutic protocols were administered, but the regimen of daunorubicin, cytosine arabinoside, and 6-thioguanine was used most frequently (12 of 26 patients). We observed no relationship between a particular chemotherapeutic regimen and the subsequent course.

The diagnosis of invasive pulmonary aspergillosis was established as follows: (1) histologic demonstration of lung invasion by branched septate hyphae consistent with *Aspergillus* spp. (22 patients); (2) multiple expectorated sputum cultures positive for *Aspergillus flavus* during an episode of obvious lower respiratory tract disease (4 patients); (3) histology and culture of bronchoscopically obtained pulmonary secretions (2 patients).

Aspergillus spp. were cultured in 18 of 26 (69%) patients: *A. flavus* in 16 patients, and *A. niger* and *A. fumigatus* in 1 patient each. Seven patients had concomitant pulmonary infections with another organism. The pathogens included *Candida* spp. (5 patients), cytomegalovirus (1 patient), *Nocardia* spp. (1 patient), and gram-negative bacilli (2 patients).

There were 15 patients in Group 1 (bone marrow recovery) and 11 patients in Group 2 (no bone marrow recovery). The 2 groups were similar with respect to age as well as in the frequency of acute myelogenous leukemia, bacteremia, and white blood cell transfusions (table 1).

The number of days of granulocytopenia before the appearance of the infiltrate ultimately diagnosed as IPA was not different between groups, but, as would be expected, the total days of granulocytopenia and the days of granulocytopenia after the infiltrate had appeared were significantly greater in Group 2 patients. Although significantly more patients in Group 1 had the diagnosis of IPA established premortem, there was no significant difference in the proportion of patients receiving amphotericin B therapy (15 of 15 Group 1 patients versus 9 of 11 Group 2 patients) because of the frequent use of empiric amphotericin B in this patient population at this institution. Therapy with amphotericin B was initiated an average of 2.7 days (range: -20 to +20 days) after the first infiltrate ultimately diagnosed as IPA was visualized on chest radiograph in the Group

1 patients and an average of 4 days (range: -8 to +18 days) after the appearance of the initial infiltrate in Group 2 patients. This difference was not statistically significant. Significantly more patients in Group 1 survived longer than 2 months after the onset of the infection. *Aspergillus* pneumonia caused or contributed to the death of 6 of 15 Group 1 patients and 10 of 11 Group 2 patients.

The radiographic findings of both groups are compared in table 2. There were no significant differences in the initial appearance of the infiltrates ultimately diagnosed as IPA. Twenty-three patients presented with either single or multiple nodular infiltrates. Nodular infiltrates appeared an average of 17 days after the onset of the chemotherapy-induced granulocytopenia; infiltrate(s) usually enlarged slowly, and often additional nodules appeared in other parts

TABLE 1
CORRELATION OF CLINICAL FEATURES TO MARROW RECOVERY

	Group 1 (Marrow Recovery) n = 15	Group 2 (No Marrow Recovery) n = 11	p Value
Age	46.4 \pm 15.7*	50 \pm 14.6	NS
Number with AML	11 (73%)	10 (91%)	NS
Number with documented bacteremia	6 (40%)	6 (55%)	NS
Number receiving WBC transfusions	3 (20%)	6 (55%)	NS
Number with premortem diagnosis of IPA	14 (93%)	3 (27%)	< 0.001
Number receiving Amphotericin B	15 (100%)	9 (82%)	NS
Number who survived longer than 2 months after appearance of radiographic infiltrate ultimately diagnosed as IPA	9 (60%)	0	< 0.05
Total days of granulocytopenia†	27.1 \pm 10.0	36.5 \pm 9.7	< 0.05
Days of granulocytopenia before appearance of infiltrate	16.7 \pm 7.5	18.6 \pm 10	NS
Days of granulocytopenia after appearance of infiltrate	11.1 \pm 10.5	21.6 \pm 12	< 0.05

Definition of abbreviations: NS = not significant; AML = acute myelogenous leukemia; WBC = white blood cell; IPA = invasive pulmonary aspergillosis.

* Mean \pm standard deviation.

† Less than 500 granulocytes/ mm^3 .

TABLE 2
CORRELATION OF RADIOGRAPHIC FINDINGS TO MARROW RECOVERY

	Group 1 (Marrow Recovery) n = 15	Group 2 (No Marrow Recovery) n = 11	p Value
Initial Findings			
Singular nodular infiltrate	8 (55%)	3 (27%)	NS*
Multiple nodular infiltrates	7 (45%)	5 (45%)	NS
Nonspecific alveolar infiltrates	0	1 (9%)	NS
"Miliary" pattern	0	2 (18%)	NS
Cavitation	0	0	NS
Later Findings			
Cavitation	11 (73%)	0	< 0.005
Multiple nodular infiltrates	11 (73%)	9 (82%)	NS
Diffuse lung disease	0	8 (73%)†	< 0.005

* NS = not significant.

† Many of these patients had concomitant congestive heart failure or other infections.

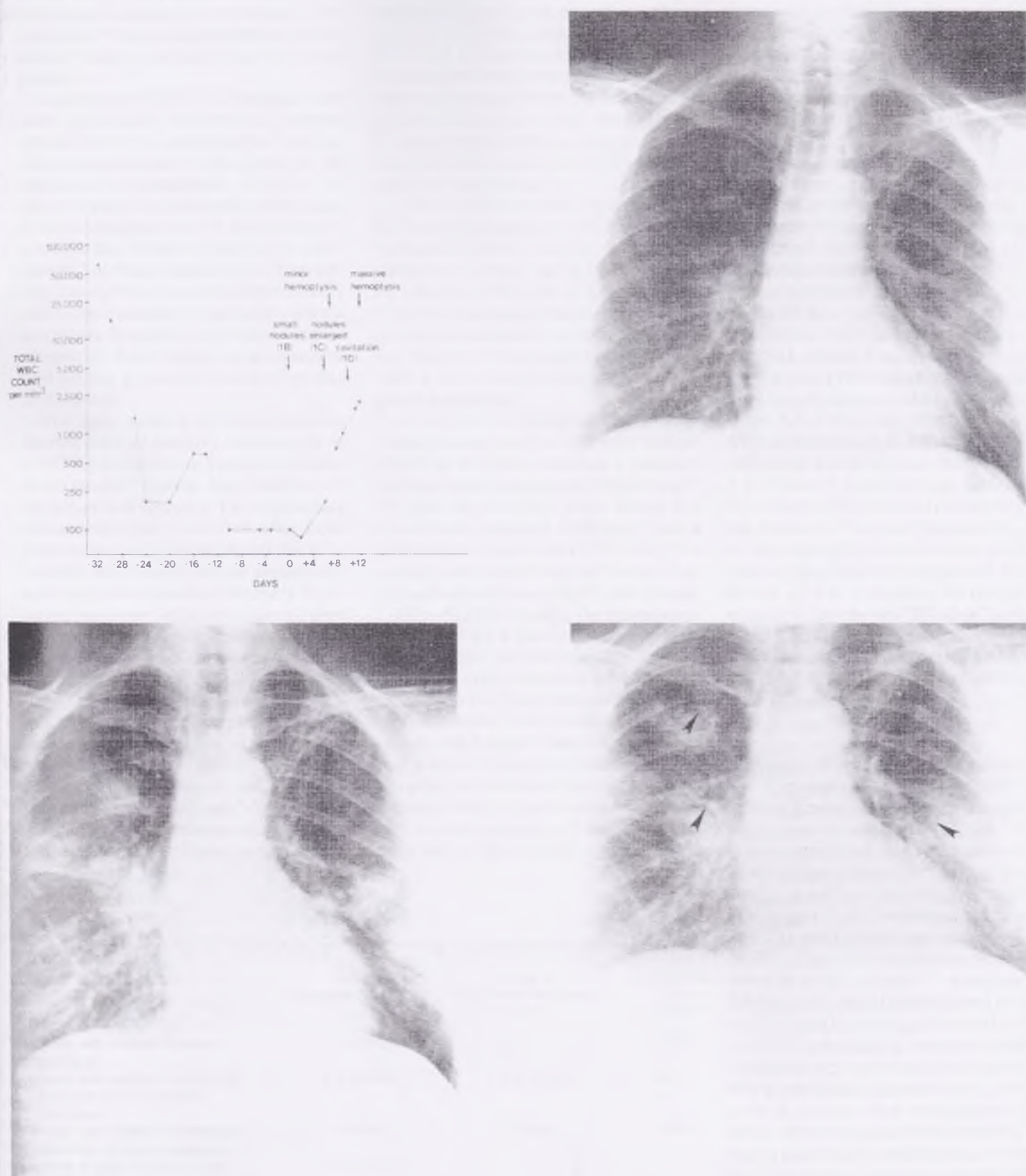


Fig. 1 Clinical and radiographic events correlated with total white blood cell counts in a patient with invasive pulmonary aspergillosis and acute leukemia. A. (top left) The total white blood cell count on a logarithmic scale is plotted against time. Day 0 represents the first day that the infiltrate ultimately diagnosed as invasive pulmonary aspergillosis was visualized. The patient received courses of chemotherapy on Day -31 and Day -16. An episode of minor hemoptysis occurred on Day 6 followed by a fatal episode of massive hemoptysis on Day 12, 2 days after cavity formation. B. (top right). Multiple small nodules were the first radiographic manifestation of invasive pulmonary aspergillosis. C. (bottom left). Five days later the nodules have enlarged in size. D. (bottom right). Cavitation of the nodules (arrows) occurred on Day 10, 3 days after the total white blood cell count exceeded 1,000/mm³ and the granulocyte count exceeded 500/mm³.

of the lung. There seemed to be no predominant location for the nodules. The peripheral "wedge-shaped pleural-based defect" pattern was not observed in any patient.

In contrast to the initial findings, there were significant differences between groups when the radiographic findings that developed later in the course of the infection were analyzed. Eight of 11 Group 2 patients developed diffuse lung disease, whereas none of the patients in Group 1 did. Autopsy results were available in 7 of these 8 patients. Diffuse disease most often occurred preterminally and represented either pulmonary edema secondary to severe renal failure and/or congestive heart failure, or a concomitant diffuse pneumonia most often due to *Candida*.

The most striking difference was the development of cavitory lesions in 11 of 15 (73%) of the Group 1 patients, whereas no cavitory lesions were observed in the patients in Group 2. The appearance of cavitation only occurred after bone marrow recovery. We analyzed this relationship with respect to both granulocyte and total white blood cell recovery. Cavitation was observed an average of 2 days (range: 0 to 6 days) after the granulocyte count exceeded 500/mm³ and an average of 3.6 days (range: 2 to 7 days) after the total white blood cell count exceeded 1,000/mm³. No cavitory lesion was observed in any patient who had a total white blood cell count less than 1,000/mm³; only 1 patient had a granulocyte count below 500/mm³. The clinical and radiographic features of a representative patient are shown in figure 1.

Autopsy or lobectomy specimens were available from the 4 patients without cavities in Group 1 and from 8 patients in Group 2. Cavities not visualized on radiographs were discovered in 2 patients from each group. When the incidence of cavities detected by both radiographic and histologic methods was analyzed, there was still a significant difference between groups (table 3).

There were 38 episodes of hemoptysis in 10 patients, including 8 of the 15 (53%) patients in Group 1 and 2 of the 11 (18%) patients in Group 2 (table 3). Four of the 26 patients (16%), all in Group 1, had massive hemoptysis. One patient died following this episode. The other 3 patients survived after emergency bronchoscopy with a rigid bronchoscope and subsequent lobectomy.

At the time of bleeding, the average platelet count was 205,000/mm³ (range: 38,000 to 493,000), and only 1 patient's platelet count was less than 50,000/mm³. All had an absolute white blood cell count that exceeded 1000/mm³ and a granulocyte count above 500/mm³. The average total white blood cell count during each episode was 18,850/mm³ (range: 1,000 to 52,000). Finally, the coagulation profiles of all 4 patients were normal.

In 3 of the 4 patients experiencing massive hemoptysis, the appearance of a cavitory lesion on chest radiograph preceded the episode by an average of 1.7 days (range: 1 to 2 days). One of these patients had a minor episode of hemoptysis one day prior to the massive bleed. The fourth patient, who did not have a cavity, also had a small amount of hemorrhage 2 days before the episode of massive he-

moptysis. None of the remaining 8 patients with cavitory lung lesions had any hemoptysis.

In summary, 3 of 11 patients (27%) with cavitory lung lesions demonstrated by chest radiograph and 4 of 15 (26%) of Group 1 patients had massive hemoptysis.

The survival of each patient was, for the most part, dependent on successful treatment of the underlying leukemia. All 11 patients whose granulocytes remained <500/mm³ died within 2 months of the first appearance of the radiographic infiltrate ultimately diagnosed as IPA. Six of the 15 patients who had granulocyte recovery to >500/mm³ died during this 2-month period: 1 secondary to massive hemoptysis, 1 from an unexplained cardiopulmonary arrest, and 4 in leukemic relapse. All of the 9 survivors were treated with amphotericin B for a period of 6 to 8 wk to a total dose of approximately 2 g. Three of these patients underwent lobectomy of the involved pulmonary tissue because of massive hemoptysis. All of the remaining 6 patients had cavitory lesions that slowly disappeared over a period of 2 to 3 months. As resolution occurred, the cavities "filled-in" and became nodular, ultimately appearing as small linear scars. The 9 patients who survived for 2 months or longer ultimately died in leukemic relapse.

Discussion

A number of investigators have described the appearance of "fungus balls" or "aspergillomas" in patients with invasive pulmonary aspergillosis (14, 20, 21). It is now recognized that these cavitory lesions are not true mycetomas but are actually areas of pulmonary necrosis caused by fungal invasion of pulmonary vascular and parenchymal structures (11, 21, 22). The cavity characteristically appears as an "air crescent"—a nodular infiltrate with central necrosis and peripheral crescentic or circumferential cavitation (21). Although a number of entities (including echinococcal cysts, mucormycosis, tuberculosis, nocardiosis, bacterial lung abscess, and malignancy) have been reported to cause "air crescents," invasive pulmonary aspergillosis is the most likely origin in an immunocompromised host with lower respiratory tract infection (21).

Some controversy exists about the frequency of cavitation in IPA. In the large autopsy series of Young and associates (4) and Meyer and coworkers (6), cavities were visualized in only 6 of 185 (3%)

TABLE 3
CORRELATION OF CAVITATION AND HEMOPTYSIS TO MARROW RECOVERY

	Group 1 (Marrow Recovery) n = 15	Group 2 (No Marrow Recovery) n = 11	p Value
Number with cavities on chest radiograph	11 (73%)	0	< 0.005
Number with cavities in pathologic specimen but not on chest radiograph	2 of 4 (50%)	2 of 8 (25%)	NS*
Number with cavities in pathologic specimen or chest radiograph	13 (87%)	2 (18%)	< 0.001
Number of days of granulocytes >500/mm ³ before appearance of cavity on chest radiograph†	2.0 ± 2.0‡		
Number with hemoptysis of any degree	8 (53%)	2 (18%)	NS
Number with massive hemoptysis§	4 (27%)	0	NS

* NS = not significant.

† Excluding one patient with cavity formation prior to recovery of granulocytes to greater than 500/mm³.

‡ Mean ± standard deviation.

§ Greater than 150 ml of blood per episode.

of patients. Later studies by Orr and colleagues (11), Libshitz and Pagani (12), and Curtis and associates (21), report a higher prevalence of cavitation: 13 to 16%. In 1982, Slevin and colleagues (22) claimed that in patients with acute leukemia the "formation of air crescents appears to be rare, and to our knowledge only 12 similar cases have been reported."

In contrast, the study of Sinclair and associates (23) found that 7 of 9 patients with IPA and leukemia developed cavitary infiltrates on chest radiographs. This report differed from the previous studies in that the host population included only adult patients with leukemia, and that only 2 patients had the diagnosis of IPA established postmortem. Six of the 9 patients survived. In reports describing the radiographic appearance of IPA in renal transplant patients, Burton and coworkers (24) found cavities in 3 of 4 patients and Weiland and colleagues (25) reported cavities in 10 of 11 patients with "primary lung aspergillosis."

The explanation for the widely differing estimates of the frequency of cavitation in IPA probably resides in the host populations studied. This study has shown that granulocytes seem to be important in cavity formation. It is therefore not surprising that the prevalence of cavitation in IPA is higher in groups of patients without leukopenia, e.g., renal transplant recipients (24, 25). We found cavitation to be unusual in patients dying with leukemia who remained granulocytopenic.

Burke (20), Przyjemski (26), and Brinker (27) all described single patients with IPA and acute leukemia who developed cavitary lung lesions shortly after granulocyte recovery. Przyjemski and Mattii (26) hypothesized that potent proteolytic enzymes are released by the influx of granulocytes. These leukocyte enzymes are known to facilitate tissue destruction (28) and are probably responsible for formation of a necrotic "lung ball."

The influx of leukocytes may also lead to destruction of vascular structures, explaining the association of massive hemoptysis with recovery from granulocytopenia. Although hemoptysis is common in patients with aspergillomas, this complication has been considered rare in invasive pulmonary aspergillosis (15). Meyer and coworkers (6) observed hemoptysis in only 2 of 93 patients, and Young and colleagues (4) described hemoptysis in only 3 of 98 patients. In no patient was hemoptysis massive. In a re-

view of IPA associated with fatal massive hemoptysis, Borkin and associates (15) reported one case in a young female with acute lymphoblastic leukemia and could cite only two other examples in patients with leukemia. Aisner and coworkers (5) reported a case of massive hemoptysis associated with acute leukemia, and Curtis and associates (21) reported that 2 of 4 patients with IPA and acute leukemia who developed cavitary lung lesion had massive hemoptysis as well.

Our study shows that hemoptysis is not uncommon in patients with IPA and acute leukemia; 10 of our 26 patients had at least 1 episode of pulmonary bleeding. Surprisingly, massive hemoptysis was never observed in the patients who remained granulocytopenic, despite concurrent thrombocytopenia, but occurred in 4 of 15 (26%) of patients whose marrow recovered. Massive bleeding caused the death of one patient and necessitated emergency surgery in the other three. Like cavity formation, massive hemoptysis occurred only after the granulocyte counts had exceeded $500/\text{mm}^3$. It was not associated with either severe thrombocytopenia ($<20,000/\text{mm}^3$) or with a concurrent coagulopathy. We noted no relationship between other risk factors for hemoptysis such as previous bacterial infection (15), amphotericin B therapy, or white blood cell transfusions, although the sample size limits the power of these observations.

Because we purposely chose a relatively specific population, the potential for bias should be considered. All of the study patients had acute leukemia, and all were treated in a single oncology study unit. The prevalence of IPA during this study was relatively high, and almost all infections were due to *A. flavus*. The diagnosis of IPA was established by obtaining multiple positive sputum cultures for *Aspergillus* spp. in 4 of the 26 patients. Although evidence of both parenchymal invasion of lung tissue and growth of the fungus should be demonstrated to establish unequivocally the diagnosis of IPA (1), many authors consider the visualization of characteristic septate hyphae or recovery of *Aspergillus* spp. from multiple expectorated sputum samples combined with a compatible clinical and radiographic picture as strong presumptive evidence of infection (24, 25), as do we (16). Even if these 4 patients are excluded from analysis, the findings of this study remain unchanged.

In conclusion, this study demonstrates that in patients with acute leukemia un-

dergoing chemotherapy, bone marrow recovery can markedly affect the clinical and radiographic course of invasive pulmonary aspergillosis. Radiographic evidence of cavity formation did not occur in any of the 11 patients with acute leukemia and IPA whose granulocyte count was lower than $500/\text{mm}^3$, but 11 of 15 (73%) of our patients with marrow recovery developed one or more cavities within 6 days of the granulocyte count exceeding $500/\text{mm}^3$. The clinician should expect to see the characteristic "air crescent" sign of IPA only in leukemic patients who recover from granulocytopenia. The absence of the "air crescent" sign should *not* be used as evidence against the diagnosis of IPA in patients whose granulocyte count remains $<500/\text{mm}^3$.

We have found also that hemoptysis was a relatively common finding in our patients with IPA and acute leukemia and that massive, life-threatening hemoptysis occurred in 26% of our patients who achieved a marrow recovery. The period immediately following recovery of granulocytes may be a previously unrecognized danger period with respect to massive pulmonary hemorrhage. Vigilance should be heightened during this period, especially in the 1 to 2 days following cavity formation. Because 2 of the 4 patients with massive hemoptysis had smaller "sentinel" bleeds immediately before their massive hemorrhage, the appearance of any degree of hemoptysis during this period should be viewed with concern. We suggest that blood be available for transfusion and that the patient be evaluated by a thoracic surgeon in order to facilitate emergency surgery, if needed. As the success rate in the treatment of acute leukemia improves, prompt recognition and treatment of this problem could prevent needless mortality.

Acknowledgment

The authors would like to thank Mrs. Mary Provencher for her assistance in data collection, Dr. Edward Lusk for the statistical analysis, and Mr. Daniel Barrett for his expert preparation of the manuscript.

References

1. Williams DM, Krick JA, Remington JA. Pulmonary infection in the compromised host. Part 1. *Am Rev Respir Dis* 1976; 114:359-94.
2. Rose HD, Varkey B. Deep mycotic infection in the hospitalized adult: a study of 123 patients. *Medicine (Baltimore)* 1975; 54:499-507.
3. Mirsky HS, Cuttner J. Fungal infection of acute leukemia. *Cancer* 1972; 30:348-52.
4. Young RC, Bennett JE, Vogel CL, Carbone PP, DeVita VT. Aspergillosis: The spectrum of the dis-

- ease in 98 patients. *Medicine (Baltimore)* 1970; 49:147-72.
5. Aisner J, Schmpff SC, Wiernik PH. Treatment of invasive aspergillosis: relation of early diagnosis and treatment to response. *Ann Intern Med* 1977; 86:539-43.
6. Meyer RD, Young LS, Armstrong D, Yu B. Aspergillosis complicating neoplastic disease. *Am J Med* 1973; 54:6-15.
7. Herbert PA, Bayer AS. Fungal pneumonia: invasive pulmonary aspergillosis. *Chest* 1981; 80:220-5.
8. DeGregorio MW, Lee WMF, Linder CA, Jacobs RA, Ries CA. Fungal infections in patients with acute leukemia. *Am J Med* 1982; 73:543-8.
9. Fisher BD, Armstrong D, Yu B, Gold JWM. Invasive aspergillosis: progress in early diagnosis and treatment. *Am J Med* 1981; 71:571-7.
10. Pennington J. *Aspergillus* pneumonia in hematologic malignancy—improvements in diagnosis and therapy. *Arch Intern Med* 1977; 137:769-71.
11. Orr DP, Myerowitz RL, Dubois PJ. Patho-radiologic correlation of invasive pulmonary aspergillosis in the compromised host. *Cancer* 1978; 41:2028-39.
12. Libshitz HI, Pagani JJ. Aspergillosis and mucormycosis: two types of opportunistic fungal pneumonia. *Radiology* 1981; 140:301-6.
13. Pagani JJ, Libshitz HI. Opportunistic fungal pneumonias in cancer patients. *AJR* 1981; 137:1033-9.
14. Ramsay GC, Meyer RD. Cavitary fungus disease of the lungs. *Radiology* 1973; 109:29-32.
15. Borkin MH, Arena FP, Brown AE, Armstrong D. Invasive aspergillosis with massive fatal hemoptysis in patients with neoplastic disease. *Chest* 1980; 78:835-9.
16. Albelda SM, Talbot GH, Gerson SL, Miller WT, Cassileth PA. The role of fiberoptic bronchoscopy in the diagnosis of invasive pulmonary aspergillosis in patients with acute leukemia. *Am J Med* 1984; 76:1027-34.
17. Gerson SL, Talbot GH, Lusk EJ, Strom BL, Cassileth PA. Prolonged granulocytopenia: the major risk factor for invasive pulmonary aspergillosis in patients with acute leukemia. *Ann Intern Med* 1984; 100:345-51.
18. Weiner MH, Talbot GH, Gerson SL, Filice G, Cassileth PA. Antigen detection in the diagnosis of invasive aspergillosis: utility in controlled, blinded trials. *Ann Intern Med* 1983; 99:777-82.
19. Gerson SL, Talbot GH, Lusk EJ, *et al*. Invasive pulmonary aspergillosis: a case-control study of risk factors in adult acute leukemia (abstract). *Clin Res* 1982; 30:367A.
20. Burke PS, Coltman CA. Multiple pulmonary aspergillomas in acute leukemia. *Cancer* 1971; 28:1289-92.
21. Curtis AM, Smith GJW, Ravin CE. Air crescent of invasive aspergillosis. *Radiology* 1979; 133:17-21.
22. Stevin ML, Knowles GH, Phillips MJ, *et al*. The air crescent sign of invasive pulmonary aspergillosis in acute leukemia. *Thorax* 1982; 37:554-5.
23. Sinclair AJ, Rossof AH, Coltman CA. Recognition and successful management in pulmonary aspergillosis in leukemia. *Cancer* 1978; 42:2019-24.
24. Burton JR, Zachery JB, Bessin R, *et al*. Aspergillosis in four renal transplant recipients—diagnosis and effective treatment with amphotericin B. *Ann Intern Med* 1972; 77:383-8.
25. Weiland D, Ferguson RM, Peterson PK, *et al*. Aspergillosis in 25 renal transplant patients—epidemiology, clinical presentation, diagnosis and management. *Ann Surg* 1983; 198:622-9.
26. Przyjemski C, Mattij R. The formation of pulmonary mycetomata. *Cancer* 1980; 46:1701-4.
27. Brinker H, Hansen PB. Development of pulmonary aspergillomas coinciding with induction of remission in acute myeloid leukaemia. *Dan Med Bull* 1974; 21:37-40.
28. Janoff A, Sandhaus RA, Hopselhorn VD, Rosenbert R. Digestion of lung proteins by human leukocyte granules *in vitro*. *Proc Soc Exp Biol Med* 1972; 140:516-9.