

# **ASPERGILLOMATOUS ABSCESSSES OF THE BRAIN AND THYROID**

Robert Lisbona, Yves Lacourciere, and Leonard Rosenthal

*Montreal General Hospital, Montreal, Canada*

***A case of disseminated aspergillosis with radionuclide documentation of brain and thyroid involvement is presented. The serial nucleographic brain studies exhibited changes that paralleled the clinical course of remission and exacerbation.***

Aspergillosis, an infection produced by *aspergillus fumigatis* and other species of *aspergillus*, is a known but rare complication of the extensive use of adrenal steroids. The usual primary site of infection is the lung, and by hematogenous spread, abscesses can develop in the brain, kidney, spleen, and thyroid (2,3,5). We have recently encountered a case of primary pulmonary aspergillosis leading to aspergillomas of the brain and thyroid. Review of the literature reveals no documented radionuclide evaluation of simultaneous aspergillomatous abscesses of the brain and thyroid (1,4).

## **CASE REPORT**

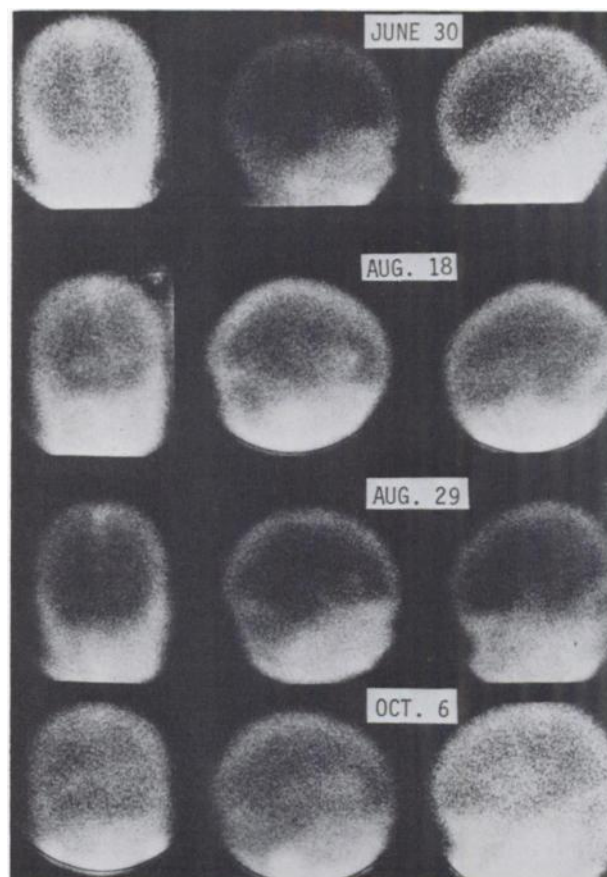
A 14-year-old boy was admitted to the hospital in May 1972 with the renal biopsy diagnosis of lupoid nephritis. Treatment was initiated with Prednisone, 80 mg every second day. A month later the patient developed a psychotic episode and severe muscular weakness. This was attributed to lupus involvement of the CNS and the dose of Prednisone was increased. A brain scan at that time was normal (Fig. 1, June 30).

In August 1972, the chest roentgenogram disclosed a cavitating lesion in the left lung. Secretions acquired at bronchoscopy grew aspergillosis. A repeat brain scan obtained on August 18 (Fig. 1) revealed foci of increased uptake of radiopertechnetate in both frontal lobes that, in light of the lung lesion, were interpreted as metastatic brain abscesses. Treatment with Amphotericin B was initiated at a dose of 80 mg every second day.

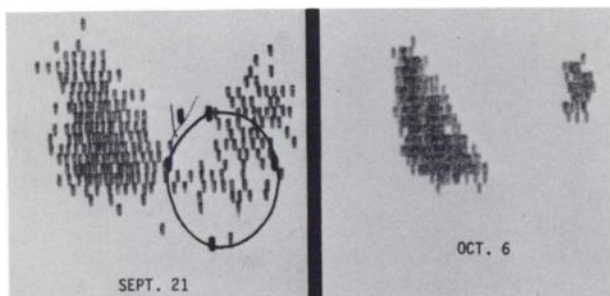
Subsequently the patient's CNS symptomatology improved and a repeat brain scan on August 29 (Fig. 1) showed partial resolution of the lesions.

Received Nov. 27, 1972; revision accepted Jan 18, 1973.

For reprints contact: Leonard Rosenthal, Div. of Nuclear Medicine, Montreal General Hospital, Montreal 109, P.Q., Canada.



**FIG. 1.** Serial radiopertechnetate brain static images in anterior right and left lateral projections, respectively. Study was normal on June 30. Bilateral frontal lobe foci were disclosed August 18. Improvement with Amphotericin B treatment was recorded on Aug. 29. Lesions became larger on Oct. 6 and coincided with exacerbation of CNS symptomatology.



**FIG. 2.** Radiopertechnetate thyroid scan on Sept. 21 showed diffuse reduction in function of left lobe and no function in palpable nodule. Thyroid scan of Oct. 6 is postlobectomy radiopertechnetate study.

However, this was complicated by a tender painful thyroid gland, and a radiopertechnetate scan on August 29 showed a diffuse reduction in trapping in the left lobe relative to the right (Fig. 2). A palpable nodule at the left lower pole was nonfunctioning (no perchlorate was administered so that the brain and thyroid could be imaged on the same day). The findings suggested diffuse involvement of the left thyroid lobe with abscess formation secondary to aspergillosis. A left hemithyroidectomy was performed and the diagnosis of aspergillomatous abscess was confirmed. Brain imaging on October 6 (Fig. 1) showed an increase in the size of the lesions and it corresponded to exacerbation of the CNS symptomatology.

#### DISCUSSION

This case represents the occurrence of a rare complication to prolonged steroid therapy. The presence

of disseminated aspergillosis with cerebral abscesses was verified by radionuclide studies. The brain scan was useful as a guide in assessing the efficacy of treatment as the radionuclide resolution of the abscesses correlated with the patient's clinical improvement. Clinical exacerbation of the cerebral process after initial improvement was reflected in the radiopertechnetate brain scan as an increase in the size of the lesions.

Radionuclide investigation of the thyroid was carried out because of the development of a painful gland. It showed the functional integrity of the right lobe and diffuse reduction in function of the left lobe complicated by an associated aspergillomatous abscess. This disclosure prompted surgical intervention.

#### REFERENCES

1. HALOZUN JF, ANAST CS, LUKENS JN: Thyrotoxicosis associated with aspergillus thyroiditis in chronic granulomatous disease. *J Pediatr* 80: 106-108, 1972
2. BRAUDE AI: Other deep mycoses: In *Harrison's Principles of Internal Medicine*, Wintrobe MM, Withorn G, Adams RD, et al, eds, 6th ed, New York, McGraw-Hill, 1970, p 919
3. KHOO TK, SUGAI K, LEONG TK: Disseminated aspergillosis. *Amer J Clin Path* 45: 697-703, 1966
4. MUKOYAMA M, GIMPLE K, POSER C: Aspergillosis of the central nervous system. *Neurology* 19: 967-974, 1969
5. YOUNG RC, BENNETT JE, VOGEL CL, et al: Aspergillosis: the spectrum of the disease in 98 patients. *Medicine (Balt)* 49: 147-173, 1970