

3. Riesco, MacClure, J. S.: Es el vertigo aural de origen exclusivamente periferico? *Rev. Otorrinolaring.*, 17:42-54, 1957.
4. Fernández, C., Alzate, R., and Lindsay, J. R.: Experimental observations on postural nystagmus in the cat. *Ann. Otol.*, 68:816-830, 1959.
5. Harrison, M. S., and Ozsahinoglu, C.: Positional vertigo. *Arch. Otolaryngol.*, 101:675-678, 1975.
6. Cawthorne, T.: Positional nystagmus. *Ann. Otol.*, 63:481-490, 1954.
7. Schuknecht, H.: Cupulolithiasis. *Arch. Otolaryngol.*, 90:765-778, 1969.
8. Schuknecht, H., and Ruby, R.: Cupulolithiasis. *Adv. Otorhinolaryngol.*, 20:434-443, 1973.
9. Sills, A., Baloh, R. W., and Honrubia, V.: Caloric testing. II. Results in normal subjects. *Ann. Otol.*, 86(Suppl. 43):7-23, 1977.
10. Ito, M.: The vestibulo-cerebellar relationships: vestibulo-ocular reflex arc and flocculus. In Naunton, R. F.: *The Vestibular System*. New York, Academic Press, Inc., 1975.
11. Cohen, B., Suzuki, J., and Bender, M. b.: Eye movements from semicircular canal nerve stimulation in the cat. *Ann. Otol.*, 73:153-169, 1964.
12. Allen, G., and Fernández, C.: Experimental observations in postural nystagmus. I. Extensive lesions in posterior vermis of the cerebellum. *Acta Otolaryngol.*, 51:2-14, 1960.
13. Fernández, C., Alzate, R., and Lindsay, J. R.: Interrelations between flocculonodular lobe and vestibular system. In Rasmussen, G. L., and Windle, W. F.: *Neural Mechanisms of the Auditory and Vestibular Systems*. Springfield, Illinois, Charles C Thomas, 1960.
14. Robinson, D. A.: Oculomotor control signals. In Lennérstrand, G., and Bach-Y-Rita, P.: *Mechanisms of Ocular Motility and Their Clinical Implications*. Oxford, Pergamon Press, 1975.
15. Baarsma, E. A., and Collewyn, H.: Eye movements due to linear accelerations in the rabbit. *J. Physiol.*, 245:227, 1975.

Reed Neurological Research Center
University of California
Los Angeles, California 90024 (Dr. Baloh)

Aspergillosis of the Nose and Paranasal Sinuses

ROBERT A. JAHRSDOERFER, M.D.,*
VICTOR S. EJERCITO, M.D.,†
MICHAEL M. E. JOHNS, M.D.,‡
ROBERT W. CANTRELL, M.D.,§
AND J. BRANTLEY SYDNOR, M.D.||

Aspergillosis of the nose and paranasal sinuses should not be considered an innocuous disease. In a review of 103 cases, other than in the Sudan, the mortality rate was 16 per cent. Intracranial extension of the fungus from the nose and sinuses carries a grave prognosis. Although aspergillosis occurs frequently in patients debilitated from other diseases, this is not always the case, and most deaths in the review series occurred in otherwise healthy individuals. The authors present eight cases of their own.

*Professor, Department of Otolaryngology and Maxillofacial Surgery, University of Virginia Medical Center. Clinical Staff, University of Virginia Hospital, Charlottesville, Virginia.

†Chief Resident, Department of Otolaryngology and Maxillofacial Surgery, University of Virginia Medical Center, Clinical Staff, University of Virginia Hospital, Charlottesville, Virginia.

‡Associate Professor, Department of Otolaryngology and Maxillofacial Surgery, University of Virginia Medical Center. Clinical Staff, University of Virginia Hospital, Charlottesville, Virginia.

§Professor and Chairman, Department of Otolaryngology and Maxillofacial Surgery, University of Virginia Medical Center. Clinical Staff, University of Virginia Hospital, Charlottesville, Virginia.

|| Clinical Assistant Professor, Department of Otolaryngology and Maxillofacial Surgery, University of Virginia School of Medicine, Charlottesville, Virginia. Clinical Staff, Roanoke Memorial Hospital, Roanoke, Virginia.

In the past decade the number of reported cases of aspergillosis of the nose and paranasal sinuses has risen threefold, probably representing an increased awareness of the disease. Despite this, aspergillosis of the nose and sinuses is an uncommon disease. Apart from the Sudan, where the disease is endemic, only 103 cases have been reported in the world literature.¹⁻⁷⁵

The fungus *Aspergillus* is a common saprophyte found in soil, dust, decaying organic matter, fruits, and grains. It may be pathogenic in man, animals, and birds. The usual portal of entry is the nose from where it may colonize in the sinuses, bronchi, or lung parenchyma or may disseminate widely.

Aspergillosis is not contagious and sources of infection are exogenous.⁷⁶ It may present in the lung as a clinically benign fungus ball, or as a necrotizing cavitory granulomatous process prone to hematogenous spread and carrying a grave prognosis. Aspergillosis is less common in the nose and paranasal sinuses. It may occur in a compromised host and may also affect otherwise healthy individuals with no underlying disease. Individuals prone to contract the disease are those debilitated from other primary diseases, and those receiving immunosuppressive therapy, steroids, and antibiotics. Disseminated aspergillosis is not limited to debilitated patients and has been reported in a non-neoplastic, non-neutropenic host.⁷⁷

The signs and symptoms of paranasal sinus aspergillosis may mimic those of chronic bacterial sinusitis. Intranasal examination may show polyps and pale edematous turbinates. Radiographs of the sinuses may show an opaque antrum. Antral lavage may yield little or no pus, and repeated irrigations may fail to improve the symptoms or clear the sinus radiographically. At this point the concerned physician will usually be suspicious of a neoplasm and perform a sinusotomy. The finding of a greenish black, rubbery, greasy material in the antrum is usually unexpected. Indeed most of the time the diagnosis of aspergillosis is made postoperatively from the morphologic appearance of tissue removed at the time of surgery.

Histologically *Aspergillus* can be identified by its septate hyphae and dichotomous branching. Conidiophores are usually not seen in tissue preparations, although on occasion they may be identified in tissue removed from the maxillary antrum.^{20, 74, 75} Conidiophores may also be seen in sputum from individuals with

cavitory aspergillosis. Identification on hematoxylin and eosin stained specimens is often difficult and special fungal stains are preferable (Gridley, PAS, methenamine silver). Whenever possible, a direct culture of the fungus should be made by spreading the specimen over the surface of a glucose-peptone agar slant. The medium should contain an antibiotic for inhibition of bacterial growth.

Aspergillus fumigatus is the species most often implicated in paranasal sinus disease. *A. flavus* is less common, and *A. niger*, *A. oryzae*, and *A. nidulans* have been isolated on occasion. One notable exception to this is paranasal sinus granuloma in the Sudan where cultures from affected individuals have exclusively shown *A. flavus*.⁷⁸

Hora³⁵ is of the opinion that aspergillosis of the paranasal sinuses may be classified as invasive or noninvasive. The invasive form, it is stated, behaves similarly to a malignant neoplasm with bone destruction, orbital involvement, and occasionally intracranial extension. The noninvasive form, on the other hand, may present much like common bacterial sinusitis with rhinorrhea, nasal congestion, fullness over the anterior face, and an opaque antrum on radiography.

The distinction between invasive and noninvasive forms is not clear-cut. The severity of the infection probably depends on the health of the host and the duration of the infection. Given enough time, noninvasive aspergillosis would probably become invasive.

Milosev et al.⁷⁹ believe that *Aspergillus* becomes pathogenic when a sinus cavity is obstructed and ventilation is impeded. In brief, it is stated that *Aspergillus* grows best in an anaerobic environment. Although we believe that *Aspergillus* may be a secondary invader of a diseased sinus, we do not consider anaerobiosis to be essential for fungal growth. Mycotic infections are known to be opportunistic invaders of the body and grow well in aerated locations, i.e., bronchi, nose, and ear canal.

One hundred three cases of aspergillosis of the nose and paranasal sinuses have been reported in the world literature exclusive of the Sudan. There were 17 deaths. All deaths were due to intracranial extension of *Aspergillus*. Two patients with intracranial extension were alive at the time of the report.^{15, 61} One was hemiparetic and blind in one eye, and the other had ominous cavernous sinus involvement and had been followed for only three months.

The maxillary sinus was the most prevalent site of *Aspergillus* infection, being singularly involved in 46 of the 103 cases. The nose was involved in eight cases, the sphenoidal sinus alone in eight cases, the ethmoidal sinus in three, and the frontal sinus in two. In all other cases the sinuses were involved in combination. Of interest is the fact that almost all the deaths from intracranial extension occurred in patients who were otherwise healthy. The one exception was a patient with alcoholic cirrhosis.⁷³

The sphenoidal sinus was involved with *Aspergillus* in a total of 14 cases.^{4, 9, 13, 17, 18, 31, 37, 39, 40, 57, 61, 71, 73} In eight of these the infection was limited to the sphenoidal sinus,^{4, 18, 37, 40, 57, 61, 71} and four died of their disease.^{4, 18, 40, 57} In six cases the sphenoidal infection occurred in combination with disease of other sinuses or neighboring structures,^{9, 13, 17, 31, 39, 73} and four of these six patients died as a result of intracranial extension of their disease.^{17, 31, 39, 73} One was alive six months postoperatively and one was lost to follow-up.^{9, 13} Subsequent death of these patients from their disease would be considered likely.

The diagnosis of aspergillosis occurring at or near the base of the skull may be difficult to make. Headache or facial pain may be the initial complaint. Schnyder¹⁷ described a case in which the presenting symptoms were those of trigeminal neuralgia. The diagnosis was later changed to retrobulbar tumor when the patient developed blindness and paresis of the extraocular muscles. The correct diagnosis of intracranial extension of aspergillosis was made at postmortem examination. In a case reported by Weidenbecher,⁶⁰ blindness and proptosis were the presenting complaints in an otherwise healthy individual.

In three cases *Aspergillus* entry was thought to be secondary to a penetrating foreign body injury of the face and maxillary sinus.^{36, 44, 52} Two of these patients were involved in separate automobile accidents and sustained facial injuries. One had a pebble in the maxillary sinus,⁴⁴ whereas the other developed multiple *Aspergillus* nodules in the skin and a maxillary sinus aspergilloma, both presumably from invasion of road dirt.³⁶ The third foreign body case associated with aspergillosis involved a steel splinter in the maxillary antrum.⁵² Other pertinent clinical information includes one patient with an *Aspergillus* pseudomembrane in the tracheobronchial tree, one patient

with allergic bronchopulmonary aspergillosis, and four patients with diabetes mellitus.^{15, 24, 45, 56, 63, 74}

Fungal cultures yielded positive identification in 40 of 103 cases. *Aspergillus fumigatus* was identified in 25 patients, *A. flavus* in eight, *A. oryzae* in two, and *A. niger* and *A. nidulans* in one each; in three patients *Aspergillus* species only was noted.

REPORT OF CASES

CASE 1

A 50 year old female presented in 1971 with a diagnosis of chronic lymphocytic leukemia of four years' duration. She had been treated with cyclophosphamide and oxymetholone. There was pain and discomfort over the left anterior face, a sensation of sinus fullness, and a mass in the left naris. The mass was subjected to biopsy and culture. Histopathologic study revealed branching septate hyphae consistent with *Aspergillus*. Culture isolates grew out *Aspergillus fumigatus*. The course was complicated by *Pseudomonas* and staphylococcal septicemia, and she was treated with gentamicin, carbenicillin, chloramphenicol, methicillin, and penicillin. No surgery was performed on the nose or sinuses. She died of leukemia three years later. An autopsy was not done.

CASE 2

A 54 year old female presented in 1972 with signs and symptoms of chronic right maxillary sinusitis. The right antrum failed to clear with medical management and antral irrigations. A Caldwell-Luc operation was performed. The mucous membrane of the antrum was noted to be markedly hyperplastic, polypoid in appearance, and gray in color. The lining was interspersed with yellow abscesses and there was free pus in the antrum. Histopathologic study showed branching septate hyphae compatible with *Aspergillus*. At the time of this writing the patient had remained free of aspergillosis for six years.

CASE 3

A 52 year old female had a long history of allergic asthma and bronchitis controlled medically with cortisone. She presented in 1974 with fullness in the left anterior face associated with increased postnasal drainage. The left maxillary sinus was opaque on transillumination and radiography. There was no evidence of bone erosion. The opaque antrum failed to clear despite four antral irrigations. A left Caldwell-Luc operation with intranasal antrostomy was performed, and a large amount of black, necrotic, cheesy material was encountered. Identification of *Aspergillus* species was made postoperatively from

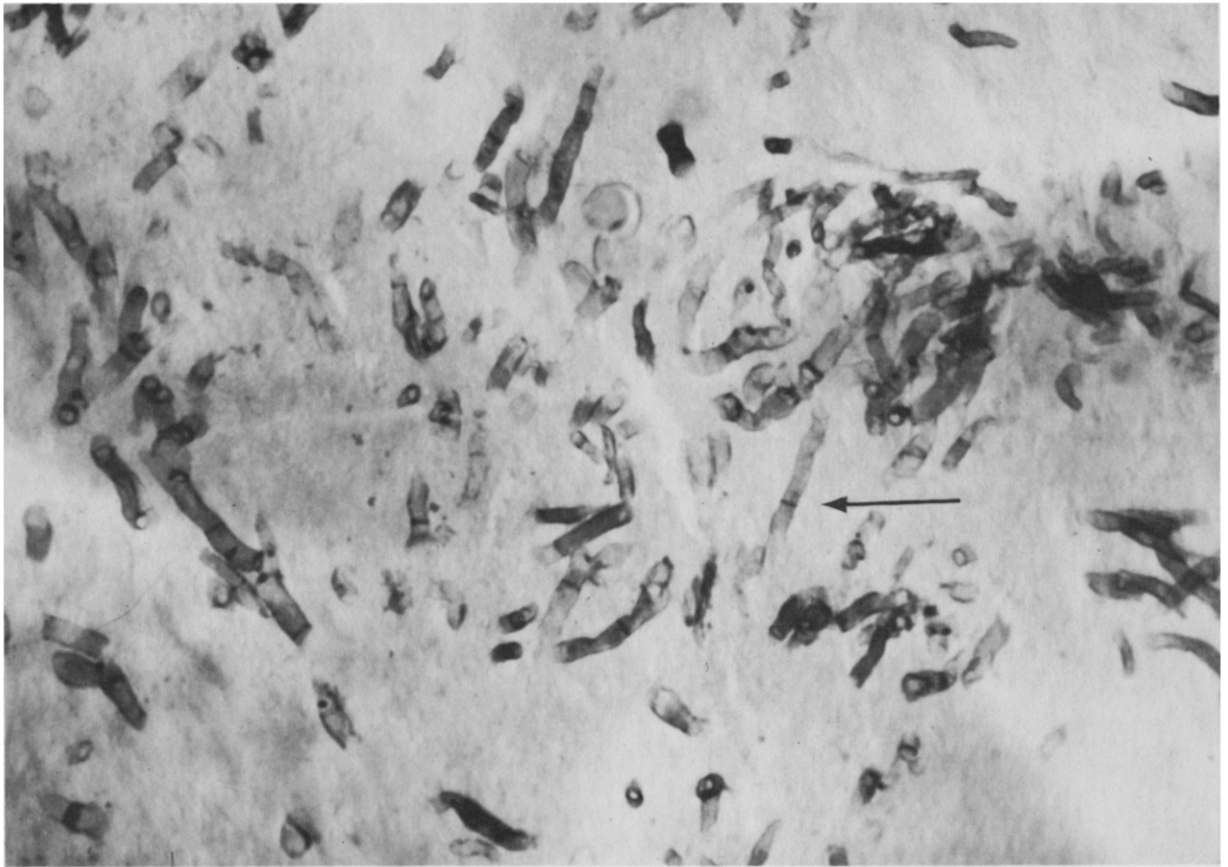


Figure 1. Histologic appearance of *Aspergillus* in tissue. Note septate hyphae (arrow) and branching. (Case 3. Methenamine-silver stain, $\times 580$.)

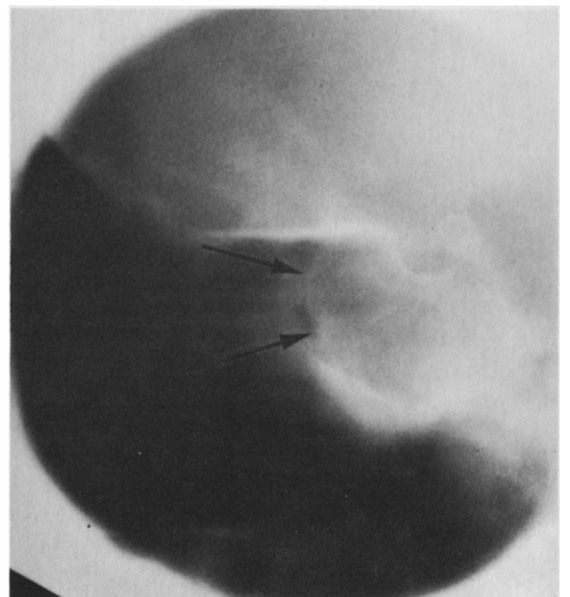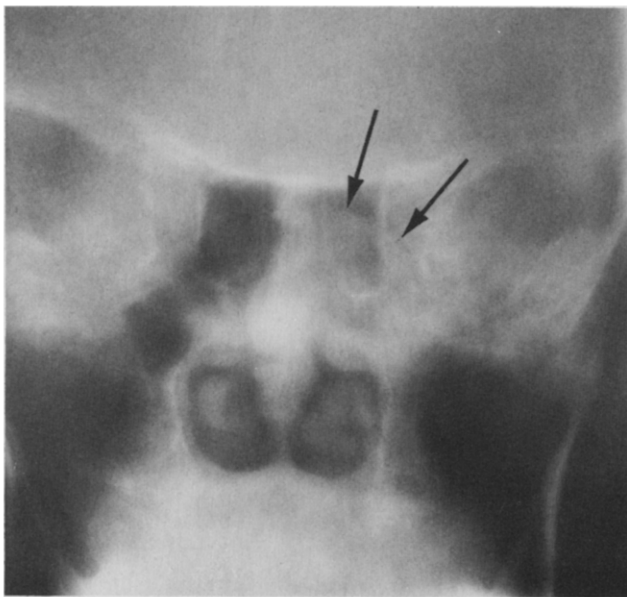


Figure 2. Tomographs showing soft tissue mass (arrows) in sphenoidal sinus.

tissue sections (Fig. 1). There was no recurrence of aspergillosis in four years' follow-up.

CASE 4

A 53 year old female presented in April 1977 with left facial pain and left sided headache of one year's duration. She was otherwise in good health. Sinus x-ray films revealed a soft tissue mass in the left sphenoidal sinus (Fig. 2). A sublabial trans-septal sphenoidal sinusotomy was performed. A firm, dark brownish yellow mass was found filling the left sphenoidal sinus. The mass had eroded the left lateral wall of the sphenoidal sinus, and there was a small leak of cerebrospinal fluid following removal of the mass. The anterior wall of the sphenoidal sinus was removed for aeration and to facilitate follow-up examination. Histologic sections showed *Aspergillus*. Because of the possibility of intracranial extension, the patient was given amphotericin B. After receiving a total of 345 mg. of amphotericin B over two weeks' time, it was necessary to discontinue the drug because of adverse side effects. There was no sign of recurrence in two years' follow-up.

CASE 5

A 23 year old female taking immunosuppressant therapy for acute myelomonocytic leukemia presented in June 1977 with a mass in the left naris. The mass extended from the septum to the lateral wall of the nose and appeared to involve the left maxillary sinus (Fig. 3). A biopsy showed branching septate hyphae and a culture grew out *A. fumigatus*. She was treated with amphotericin B preoperatively followed by resection of the mass through a lateral rhinotomy (Fig. 4). Ten months later *Aspergillus* recurred in the nose. She was treated with amphotericin B, 30 mg. every other day for two months. She died of leukemia in July 1978. Postmortem examination showed no evidence of aspergillosis.

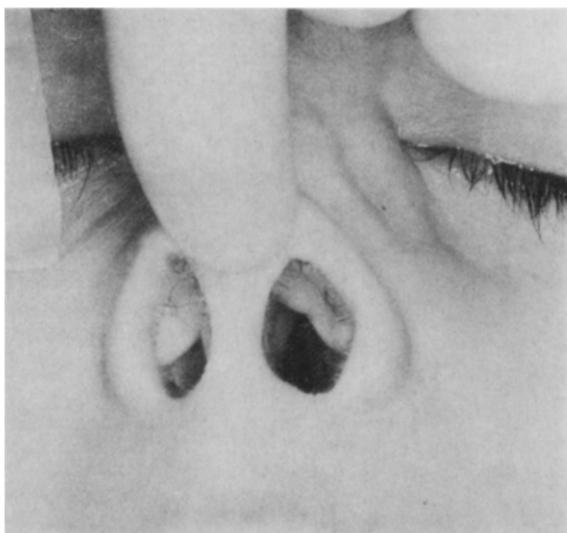


Figure 3. Black-brown fungal mass in left naris.

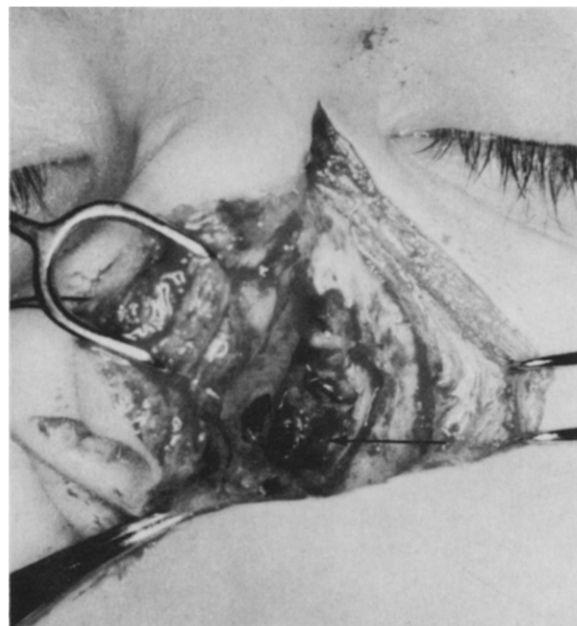

Figure 4. Lateral rhinotomy showing fungal mass filling left nasal cavity and involving septum and lateral wall.

CASE 6

A 56 year old male, otherwise healthy, presented in December 1977 with right pansinusitis. Tomographs of the right maxillary sinus revealed destruction of the medial wall. The radiologic findings were consistent with a neoplasm and he underwent a right Caldwell-Luc operation. A foul smelling, necrotic mass was encountered in the right antrum and right naris. Subtotal removal was performed. Tissue section findings were compatible with *Aspergillus* species. One month later the patient was readmitted and underwent right frontal sinus trephination and right external ethmoidectomy. Cultures of purulent material obtained from the sinus at that time were negative for fungus. Antral irrigation was also negative for fungus. There was no evidence of recurrent aspergillosis in one year.

CASE 7 (ROANOKE MEMORIAL HOSPITAL)

A 54 year old male was referred by his local physician in September 1977 for evaluation of an abnormal appearing tympanic membrane. In the course of routine otolaryngologic examination an opaque left maxillary antrum was noted on transillumination. Radiographs revealed an opaque left antrum with no evidence of bone destruction. The appearance of the antrum did not clear after antibiotic therapy and sinus irrigations. A Caldwell-Luc procedure was performed and several concretions were noted in the sinus. These had the appearance and consistency of a soft, rough, yellowish submaxillary stone. The largest was approximately 8 millimeters in diameter. The mucosa was dark and polypoid. There

was no evidence of purulence. Histopathologic examination showed large fragments of material representing colonies of a fungus identified as *Aspergillus*. There was no recurrence in 18 months.

CASE 8

A 71 year old male with chronic lymphocytic leukemia was referred for evaluation of multiple subcutaneous leukemic infiltrations involving the head and neck. Radiographs and computed tomography showed a mass in the posterior ethmoidal area. Intranasal examination was normal. There were signs of involvement of cranial nerves III, IV, and VI on the left. It was assumed that the posterior ethmoidal mass was a leukemic infiltrate, and the patient received 2000 rads directed to the left orbit and left posterior ethmoidal area. He was also treated with dexamethasone, cyclophosphamide, and vincristine. His course was rapidly downhill and he developed aspiration pneumonia, which required intubation. Sputum cultures grew out *Aspergillus fumigatus*, and amphotericin B therapy was begun. He died on the thirteenth hospital day.

Postmortem examination revealed a posterior ethmoidal cavity filled with necrotic tissue, which was identified as containing *Aspergillus* and leukemic infiltrates. The lesion had eroded into the cavernous sinus and had affected the cranial nerves in that location. There was disseminated aspergillosis, including multiple brain foci.

COMMENT

Of the eight patients reported herein, five were females and three were males (Table 1). Three patients had leukemia and were taking immunosuppressive drugs at the time aspergillosis was diagnosed. All three patients died of leukemia. Only one of these three (case 8) had evidence of aspergillosis at the time of death. Fungal cultures were positive for *A. fumigatus* in all three leukemia patients.

In four of the other five cases aspergillosis occurred in healthy individuals whose presenting symptoms mimicked those of chronic sinusitis. One patient was completely asymptomatic

and had been referred for evaluation of an abnormal appearing eardrum. An opaque sinus on transillumination prompted further investigation. Another patient with sphenoidal aspergillosis had a left sided headache and left sided facial pain for one year. Erosion of the left lateral wall of the sphenoidal sinus and the presence of a cerebrospinal fluid leak suggested intracranial extension. The patient received a course of amphotericin B and underwent surgical excision of the fungal mass. There was no recurrence in two years' time. Surgery in the three cases of isolated maxillary sinus aspergillosis proved curative at follow-ups of one and one-half, four, and six years.

The gross appearance of the fungal mass at operation varied from black to dark brown to gray-tan. The consistency was either soft and cheesy, or firm and rubbery. The appearance seemed to depend on the degree of necrosis and the presence or absence of bacterial infection. In one of our patients several rough rounded yellow concretions were found on the floor of the antrum. Grunberg²⁶ reported a similar case in which the concretions appeared as foreign bodies on sinus radiographs. In four of our cases a fungus etiology was not suspected and cultures were omitted, the diagnosis being made morphologically from tissue sections.

DISCUSSION

Although many patients with isolated maxillary sinus aspergillosis and some with isolated sphenoidal sinus aspergillosis have been cured by a simple surgical excision and ventilation of the sinus, this is not always the case, and deaths have occurred. Most cases of orbital aspergillosis presumably start in the ethmoidal or maxillary sinus. Pain, proptosis, and amaurosis may occur, and intracranial extension is not uncommon from this site.

Once the disease extends beyond its primary

TABLE 1. Aspergillosis of the Nose and Paranasal Sinuses

Case	Sex	Age	Location	Species	Other
1	F	50	Nose, maxillary, ethmoidal	<i>A. fumigatus</i>	Chronic lymphocytic leukemia, died
2	F	54	Maxillary	Unknown	Alive and well, 6 years
3	F	52	Maxillary	Unknown	Alive and well, 4 years
4	F	53	Sphenoidal	Unknown	Alive and well, 2 years
5	F	23	Nose, maxillary	<i>A. fumigatus</i>	Acute myelomonocytic leukemia, died
6	M	56	Maxillary, ethmoidal, frontal	Unknown	Alive and well, 1 year
7	M	54	Maxillary	Unknown	Alive and well, 1½ years
8	M	71	Ethmoidal	<i>A. fumigatus</i>	Chronic lymphocytic leukemia, died

focus, the spread is unrestricted by normal anatomic barriers. *Aspergillus* hyphae have been found to invade dura, blood vessel walls, and bone. *Aspergillus* may involve the internal carotid artery in its intracranial course, often causing thrombosis or rupture with fatal hemorrhage.^{18, 60, 61} In this respect it is not unlike mucormycosis in which a predilection for invasion of vascular structures is well recognized.

Aspergillus may involve the arterial and venous circulation of the brain, either by direct extension from paranasal sinuses or by fungal aneurysms secondary to hematogenous spread from infected sinuses.^{18, 57, 61, 80, 81} Horten⁸⁰ believes that the mechanism of *Aspergillus* aneurysm formation is direct invasion of the arterial wall either from an intraluminal embolus that extends its hyphae outward or from fungal meningitis that penetrates into the adventitia. The meningitis is believed to be secondary to paranasal sinus aspergillosis with intracranial extension.

Routine sinus radiographs frequently show bone erosion and are erroneously interpreted as showing a malignant neoplasm. In fact, many patients come to surgery for diagnosis precisely because a malignant tumor cannot otherwise be ruled out. Antral irrigations are often unrewarding in either establishing a diagnosis or resolving the antral opacity. Intranasal examination may reveal polyps, edematous mucosa, and a mass on the lateral wall of the nose. The clinical picture of nasal and paranasal sinus aspergillosis may be confused with that of other diseases. The differential diagnosis includes malignant neoplasm, bacterial sinusitis, mucormycosis and other fungal infections, tuberculosis, Wegener's granuloma, lues, rhinoscleroma, and osteomyelitis of the maxilla.

An aspergilloma limited to one sinus may well be cured by surgical excision. Ventilation by anrostomy may or may not be helpful. If one suspects that the infection is invasive intracranially, and thereby life threatening, amphotericin B should be administered. This drug is a potent antifungal antibiotic with dangerous side effects. The patient must be carefully monitored and parenteral treatment usually requires hospitalization. Radiotherapy has been shown to be of no value.^{9, 13, 17, 46, 82}

Exposure to *Aspergillus* without clinical evidence of tissue invasion is assumed to be fairly common. Patients with allergic bronchopulmo-

nary aspergillosis may show high titers in serologic testing as well as a positive skin test with *Aspergillus* antigen. Patients with cystic fibrosis may show positive sputum cultures as well as positive testing to allergic aspergillosis. However, no case of invasive aspergillosis of the nose and paranasal sinuses has been reported in cystic fibrosis patients.

Aspergillosis in the Sudan

The Sudan appears to be an endemic area for paranasal *Aspergillus* granuloma.^{78, 79, 82, 83} Over 60 cases have been recorded.⁷⁸ In this area *Aspergillus* appears to be ubiquitous. The climate is hot and dry, and desert-like conditions prevail. A high dust content in the atmosphere and summer sandstorms enhance the dissemination of *Aspergillus* spores. *Aspergillus* can be cultured from the bedding, straw roofs, timber, and earth floors of the Sudanese dwellings. Moreover, cultures of nasal swabs from asymptomatic individuals often show *Aspergillus*.⁸²

The warm moist confines of the maxillary and ethmoidal sinuses are thought to be fertile ground for the seeding of the fungal spores. The arid climate predisposes to nasal crusting, and the altered physiology of the nose may then influence the change of *Aspergillus* from a common saprophyte to a pathogen. Once it is entrenched, the growth of the fungus often involves the orbit, and if untreated may ultimately invade intracranially and cause death.

In all fungal isolates grown from Sudanese patients with clinical disease, *A. flavus* has thus far been the sole causative agent.⁷⁸ Other species of *Aspergillus* (*niger*, *terreus*, *nidulans*) have been cultured from nasal cavities of the general population, but have not been implicated in clinical disease, at least not in the Sudan. There are a few reports outside the Sudan where *Aspergillus* species other than *A. flavus* and *A. fumigatus* have been pathogenic. One of the patients in the series from the Sudan was a five year old boy, only the second child with clinical *Aspergillus* infection to be reported in the world literature.

Veress et al.⁸³ believe that three factors may play a role in the pathogenicity of paranasal *Aspergillus* granuloma: recurrent inflammation from a hot, dry, sandy atmosphere, the inherent invadability of the fungus when conditions are right, and an immunologic process once fungal invasion has begun.

Although aspergillosis is not considered endemic in areas outside the Sudan, it is, nonetheless, being encountered with greater frequency. One should not be lulled into believing that aspergillosis of the nose and sinuses is a harmless disease. Surgical eradication is the preferred treatment. Extension intracranially is life threatening and should be vigorously treated with amphotericin B or a comparable antifungal agent as determined by culture and sensitivity tests.

References

- Shubert, J.: Zur kasuistik der Aspergillusmykosis. Dtsch. Arch. Klin. Med., 36:162, 1885.
- Zarnico, C.: Aspergillus mykose der kieferhöhle. Dtsch. Med. Wschr., 17:1222, 1891.
- MacKenzie, J. N.: Aspergillus mycosis of the antrum maxillare. N.Y. Med. J., 60:238-240, 1894.
- Oppe, W.: Zur kenntnis der schimmelpilzmykosen beim menschen. Zbl. Allg. Path., 8:301-306, 1897.
- Dalmeyer, J. J.: Casuistische mededeelingen. Ned. Tijdschr. Geneesk., 57:2117-2127, 1913.
- Tilley, H.: Aspergillosis of the maxillary antrum. Proc. Roy. Soc. Med., 8:14-23, 1914-1915.
- Harmer, D., and Jockes, T.: Specimens of Aspergillus fumigatus from nasal sinuses. Proc. Roy. Soc. Med., 12:187, 1918-1919.
- Skilern, R. H.: Aspergillus of the maxillary sinus. Laryngoscope, 31:946-949, 1921.
- Wright, R. E.: Two cases of granuloma invading the orbit due to an Aspergillus. Brit. J. Ophthalm., 11:545-559, 1927.
- Watjen, J.: Zur kenntnis der gewebsreaktionen bei schimmelpilzmykosen. Virchows Arch. (Path. Anat.), 268:665-685, 1928.
- Mollari, M.: Zur kenntnis der schimmelpilzkrankung der Highmorshöhle. Z. Hals- Nas- Ohrenheilk., 25:85, 1929.
- Just, E.: Aspergillusabszess des grosshirns. Mitt. Grenzgeb. Med. Chir., 42:540-549, 1931.
- Adams, N. F.: Infection involving the ethmoid, maxillary and sphenoid sinuses and the orbit due to Aspergillus fumigatus. Arch. Surg., 26:999-1009, 1933.
- Kelly, A. B.: Aspergillosis of the nose and maxillary antrum. J. Laryngol., 49:821-828, 1934.
- Nash, C. S.: Fulminating infection of the nose due to Monilia or Aspergillus. Arch. Otolaryngol., 28:234-240, 1938.
- Batt, F.: Aspergillosis and other mycoses in the sinuses of the nose. Acta Otolaryngol., 29:129-137, 1941.
- Schnyder, H. K.: Aspergillose der schadelbasis. Pract. Oto-rhino-laryngol., 10:402-421, 1948.
- McKee, E. E.: Mycotic infection of brain with arteritis and subarachnoid hemorrhage. Am. J. Clin. Path., 20:381-384, 1950.
- Rohrt, A. T.: Mykotisk maxillarsinusitt. Nord. Med., 52:1312-1313, 1954.
- Montreuil, F.: Fungus infection of the antrum. J. Laryngol. Otol., 69:559-566, 1955.
- Jackson, I. J., Earle, K., and Kuri, J.: Solitary Aspergillus granuloma of the brain. J. Neurosurg., 12:53-61, 1955.
- Andersen, H. C., and Stenderup, A.: Aspergillosis of the maxillary sinus. Acta Otolaryngol., 46:471-473, 1956.
- Liener, A.: Nach antibiotischer behandlung aufgetretene Aspergillose der siebbeinzellen mit sekundärer meningitis aspergillina und begleitendem mykotischem pyozephalus. Mschr. Ohrenheilk., 90:138-142, 1956.
- Arnaud, G., and Pesle, G. D.: L'aspergillose des sinus. Ann. Otol. (Paris), 74:796-801, 1957.
- Tikhomirov, P.: Mycosis of orbit simulating a tumor. Vestn. Oftalmol., 71:44-48, 1958.
- Grunberg, H.: Zur aspergillose der kieferhöhle. HNO, 8:41-42, 1959.
- Weller, W. A., Joseph, D. J., and Hora, J. F.: Deep mycotic involvement of the right maxillary and ethmoid sinuses, the orbit and adjacent structures. Laryngoscope, 70:999-1016, 1960.
- Savetsky, L., and Waltner, J.: Aspergillosis of the maxillary antrum. Arch. Otolaryngol., 74:107-110, 1961.
- Bailey, J. C., and Fulmer, J. M.: Aspergillosis of the orbit. Am. J. Ophthalmol., 51:670-674, 1961.
- Dijkstra, B. K. S., and Visser, S.: A fungus infection, probably aspergillosis of the maxillary sinus. Ned. Tijdschr. Geneesk., 105:473-475, 1962.
- Bennett, J. E., Kirby, E. J., and Blocker, T. G.: Unusual inflammatory lesions of the face. Plast. Reconstr. Surg., 29:684-691, 1962.
- Seabury, J. H., and Samuels, M.: The pathogenetic spectrum of aspergillosis. Am. J. Clin. Path., 40:21-33, 1963.
- Massetiol, R., and Thibaut, B.: Un cas d'aspergillose du sinus maxillaire. Ann. Otol. (Paris), 80:719-721, 1963.
- Mehrotra, M. C.: Aspergillosis of maxilla. Oral Surg., 20:33-37, 1965.
- Hora, J. F.: Primary aspergillosis of the paranasal sinuses and associated areas. Laryngoscope, 75:768-773, 1965.
- Arons, M. S., Lynch, J. B., Lewis, S. R., Larson, D. L., and Blocker, T. G.: Hemifacial resection for rare inflammatory diseases of the parotid gland. I. Aspergillosis. II. Pseudosarcomatus fasciitis. Am. Surg., 32:496-502, 1966.
- Kawamoto, K.: Aspergillosis of the sphenoid sinus. Otolaryngology (Tokyo), 40:35-38, 1968.
- Becker, M. H., Ngo, N., and Beranbaum, S. L.: Mycotic infection of the paranasal sinuses. Radiology, 90:49-51, 1968.
- Green, W. R., Font, R. L., and Zimmerman, L. E.: Aspergillosis of the orbit. Arch. Ophthalmol., 82:302-313, 1969.
- Young, R. C., Bennett, J. E., Vogel, C. L., Carbone, P. P., and DeVita, V. T.: Aspergillosis. Medicine, 49:147-173, 1970.
- Taillens, J. P., Grigoriu, D., and Font, N.: Observations à propos de deux cas d'infection sinusale fongique. Bull. Soc. Franc. Mycol., 18:39-40, 1970.
- Martinson, F. D., Alli, A. F., and Clark, B. M.: Aspergilloma of the ethmoid. J. Laryngol. Otol., 84:857-861, 1970.
- Piquet, J. J., Massol, P., and Pilliaert, J. M.: Un nouveau cas d'aspergillose du sinus maxillaire. J. Fr. Otorhinolaryngol., 20:2288, 1971.
- Kley, W., and Draf, W.: Die aspergillose der oberen luftwege. HNO, 19:356-360, 1971.
- Zinneman, H. H.: Sino-orbital aspergillosis. Minn. Med., 55:661-664, 1972.
- Iwamoto, H., Katsura, M., and Fujimaki, T.: Mycosis of the maxillary sinuses. Laryngoscope, 82:903-909, 1972.
- Finby, N., and Begg, C. F.: Aspergilloma of sinus. N.Y. J. Med., 72:493-495, 1972.
- Muler, H., Cotin, H., and Prache, H.: Mycosis de l'étage moyen de la face. Ann. Otolaryngol. Chir. Cervicofac., 89:449-454, 1972.

49. Sakai, M.: Two cases of mycosis of the maxillary sinus. *Otolaryngology* (Tokyo), 44:121-126, 1972.
50. Gregoriu, D., and Dutoit, M. L.: Un nouveau cas de sinusite maxillaire fongique. *Mycopathol. Mycol. Appl.*, 51:81-86, 1973.
51. Jirousek, Z., and Vortel, V.: Aspergillosis of the maxillary antrum. *Cesk. Stomatol.*, 73:371-374, 1973.
52. Vuori, E. J., and Koskinen, O.: Foreign bodies in the paranasal sinuses. *Duodecim*, 89:494-498, 1973.
53. Varga, S.: Aspergilom Highmoru. *Cesk. Stomatol.*, 74:444-445, 1974.
54. Segall, B. W.: The construction and implantation of a silicone rubber cranial prosthesis. *J. Prosthet. Dent.*, 31:194-197, 1974.
55. Warder, F. R., Chikes, P. G., and Hudson, W. R.: Aspergillosis of the paranasal sinuses. *Arch. Otolaryngol.*, 101:683-685, 1975.
56. Pena, C. E.: Aspergillus intranasal fungal ball. *Am. J. Clin. Path.*, 64:343-344, 1975.
57. Sood, V. P., Goyal, N. K., and Abrol, B. M.: Aspergillosis of sphenoid sinus. *E.E.N.T. Mon.*, 54:454-457, 1975.
58. Ruch, M., Komminoth, J., and Florange, W.: Deux nouveau cas d'aspergillose ethmoidomaxillaire. *J. Fr. Otorhinolaryngol.*, 24:239-241, 1975.
59. Mikaelsen, T.: Mycotic infection of the maxillary sinus. *Tidsskr. Nor. Laegeforen.*, 95:1520-1521, 1975.
60. Weidenbecher, M., and Brandt, G.: Letale aspergillose der Nasennebenhöhlen. *Laryngol. Rhinol. Otol. (Stuttg.)*, 54:722-727, 1975.
61. Weinstein, M., Theron, J., and Newton, T. H.: Aspergillosis involving the sphenoid sinus. *Neuroradiology*, 11:137-139, 1976.
62. Roser, S., Canalis, R. F., and Hanna, C. J.: Aspergillosis of the maxillary antrum. *J. Oral Med.*, 31:91-93, 1976.
63. Safirstein, B. H.: Allergic bronchopulmonary aspergillosis with obstruction of the upper respiratory tract. *Chest*, 70:788-790, 1976.
64. McGinnis, M. R., Buck, D. L., and Katz, B.: Paranasal aspergilloma caused by an albino variant of *Aspergillus fumigatus*. *South. Med. J.*, 70:886-888, 1977.
65. Gonty, A. A., and Page, L. R.: Aspergillosis of the maxillary sinus. *Oral Surg.*, 43:350-356, 1977.
66. Levine, P. A., and Yanagisawa, E.: Residents page, pathologic quiz, case 1. *Arch. Otolaryngol.*, 103:560-562, 1977.
67. Scully, R. E. (Editor): Case records of the Massachusetts General Hospital; case 36-1977. *New Eng. J. Med.*, 297:546-551, 1977.
68. Nielsen, K. O., and Fogstrup, J.: Aspergillosis sinus maxillaris. *Ugeskr. Laeger*, 139:1669-1670, 1977.
69. Betkowski, A., and Zmarz, K.: Aspergillosis of the nose and paranasal sinus. *Wiad. Lek.*, 30:1283-1285, 1977.
70. Dejonckere, P.: A propos d'un mycotome aspergillaire du sinus maxillaire. *Acta Otorhinolaryngol. Belg.*, 31:154-159, 1977.
71. Miglets, A. W., Saunders, W. H., and Ayers, L.: Aspergillosis of the sphenoid sinus. *Arch. Otolaryngol.*, 104:47-50, 1978.
72. Stevens, M. H.: Aspergillosis of the frontal sinus. *Arch. Otolaryngol.*, 104:153-156, 1978.
73. McGill, T. J. I.: Mycotic infection of the temporal bone. *Arch. Otolaryngol.*, 104:140-142, 1978.
74. Smolansky, S. J.: Aspergillosis of the paranasal sinuses. *Ear Nose Throat J.*, 57:320-323, 1978.
75. Titche, L. L.: Aspergillosis of the maxillary sinus. *Ear Nose Throat J.*, 57:398-401, 1978.
76. Emmons, C. W., Binford, C. H., Utz, J. P., and Kwon-Chung, K. J. (Editors): *Medical Mycology*. Ed. 3. Philadelphia, Lea & Febiger, 1977.
77. Murray, H. W.: Aspergillosis. *J.A.M.A.*, 238:1498, 1977.
78. Mahgoub, E. S.: Mycosis of the Sudan. *Trans. Roy. Soc. Trop. Med. Hyg.*, 71:184-188, 1977.
79. Milosev, B., Mahgoub, E. S., Aal, O. A., and El Hassen, A. M.: Primary aspergilloma of paranasal sinuses in the Sudan. *Brit. J. Surg.*, 56:132-137, 1969.
80. Horten, B. C., Abbott, G. F., and Porro, R. S.: Fungal aneurysm of intracranial vessels. *Arch. Neurol.*, 33:577-579, 1976.
81. Davidson, P., and Robertson, D.: A true mycotic aneurysm leading to fatal subarachnoid hemorrhage in a patient with hereditary hemorrhagic telangiectasia. *J. Neurosurg.*, 35:71-76, 1971.
82. Sandison, A. T., Gentles, J. C., Davidson, C. M., and Branko, M.: Aspergilloma of paranasal sinuses and orbit in northern Sudanese. *Sabouraudia*, 6:57-69, 1967.
83. Veress, B., Malik, O. A., El Tayeb, A. A., El Daoud, S., El Mahgoub, S., and El Hassan, A. M.: Further observations on the primary paranasal aspergillus granuloma in the Sudan. *Am. J. Trop. Med. Hyg.*, 22:765-772, 1973.

Department of Otolaryngology and
Maxillofacial Surgery
Box 430
University of Virginia Medical Center
Charlottesville, Virginia 22908 (Dr. Jahrsdoerfer)