

Fulminating Disseminated Aspergillosis Complicating Peritoneal Dialysis in Eclampsia

D. A. Ross, MB; D. C. Anderson, MB, MRCP;
M. C. Macnaughton, MB, FRCOG;
and W. K. Stewart, MB, MRCP, Dundee, Scotland

Disseminated aspergillosis was not reported before the advent of antibiotics. In a review of the world literature Tan et al¹ found 22 cases occurring since 1939, and described a further one. Almost all these cases, and others reported subsequently^{2,3} had received antibiotics or steroids, or both, and most had an underlying debilitating illness; one patient had Cushing's syndrome.⁴

The present case is unusual in that the portal of entry seems to have been a peritoneal infection resulting from peritoneal dialysis.

Submitted for publication Aug 10, 1967; accepted Oct 4.

From the departments of pathology (Dr. Ross), medicine (Drs. Anderson and Stewart), and midwifery and gynecology (Dr. Macnaughton), University of Dundee (Scotland).

Reprint requests to Department of Medicine, University of Dundee, Dundee, Scotland (Dr. Stewart).

Patient Summary

A primigravida, age 22, had a normal antenatal course, until Nov 8, 1965 (36th week), when her blood pressure (BP) was 130/80 mm Hg and the urine contained a trace of protein. The major clinical events, together with antibiotic, steroid, and dialysis treatment are summarized in Fig 1. On Nov 20 (38th week) at 4:30 PM nausea, vomiting, and intermittent epigastric pain developed. The pain persisted and at 7 PM she was admitted to hospital. When examined she had epigastric tenderness; the uterine size was consistent with the gestation period, and showed no abnormality. The fetal heart rate was normal. The BP was 120/75 mm Hg and the neurological examination was negative.

At 7:07 PM she had a generalized convulsion. Oxygen was given by face mask and 180 mg phenobarbital by intramuscular injection. A provisional diagnosis of an epileptic seizure precipitated by pregnancy was made. She

was transferred to the labor room and because of continued restlessness and epigastric pain, 50 mg meperidine hydrochloride was given by intravenous injection. The pain eased but at 8:10 PM a second seizure occurred. Her BP was now 170/100 mm Hg. Urine (200 ml) obtained by catheter contained large amounts of protein. A diagnosis of eclampsia was now made in view of the elevated BP and albuminuria. At 8:15 PM, 5.3 ml tribromoethanol (Avertin) was given rectally, this being an appropriate dose for her weight (59.5 kg [131 lb]). At 9:30 PM when the patient was well sedated, labor was induced by artificial rupture of the membranes. The BP rose to 150/100 mm Hg at 10:50 PM and because of the possibility of another convulsion a second dose of 5.3 ml tribromoethanol was prepared. Meanwhile a third convulsion occurred and the tribromoethanol was then given. Because of the unusual occurrence of fits after tribromoethanol it was thought desirable to accelerate delivery by a cesarean section. Approximately one hour later (11 PM) a lower uterine segment cesarean section was performed. Since the patient was already heavily sedated with tribromoethanol, only the addition of succinylcholine chloride and oxygen were required for anesthesia. A live male child, weight 2.54 kg (5 lb 9½ oz) was delivered and responded slowly to resuscitation. The placenta was circumvallate but otherwise normal, and there was no retroplacental clot.

During the immediate postoperative period her BP remained at about 100/

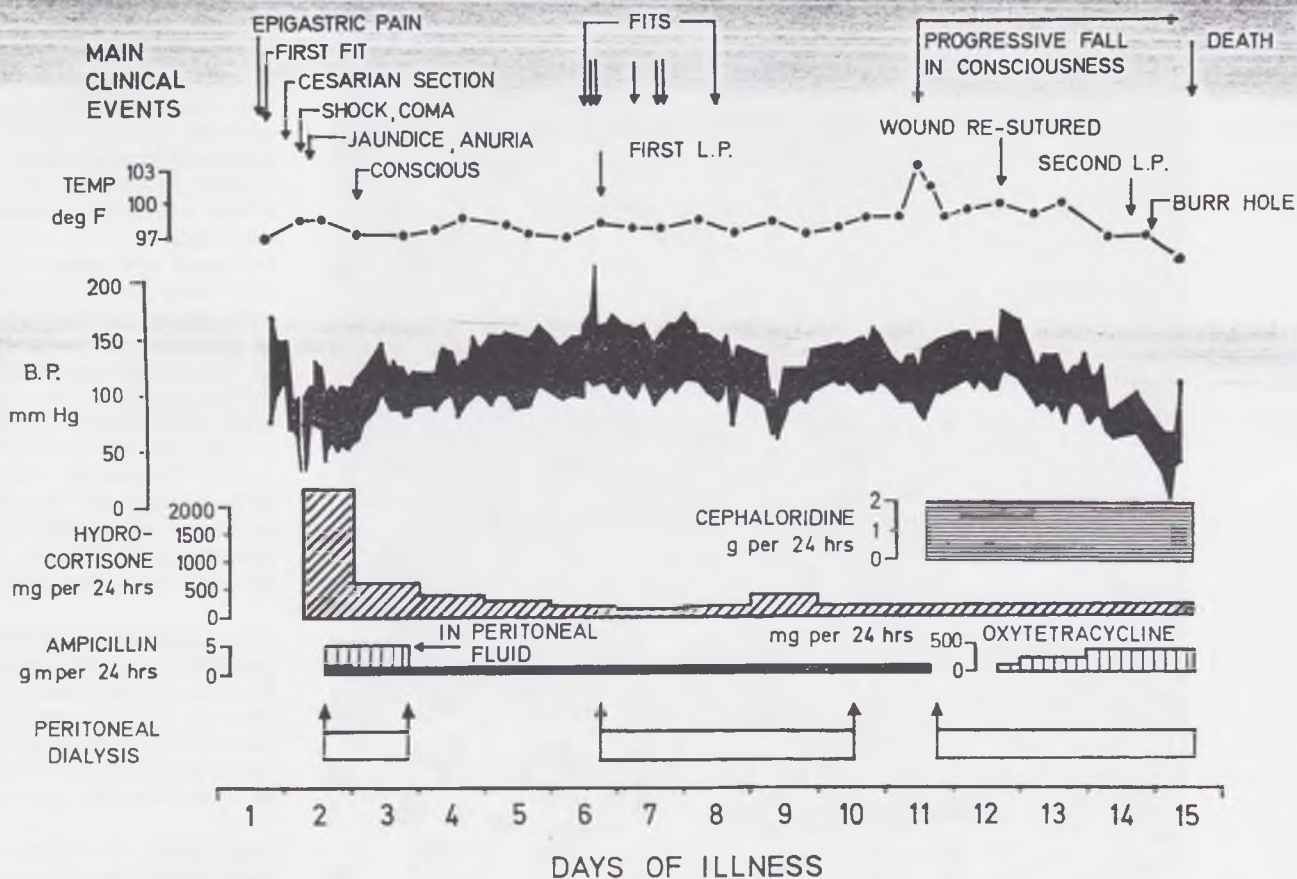
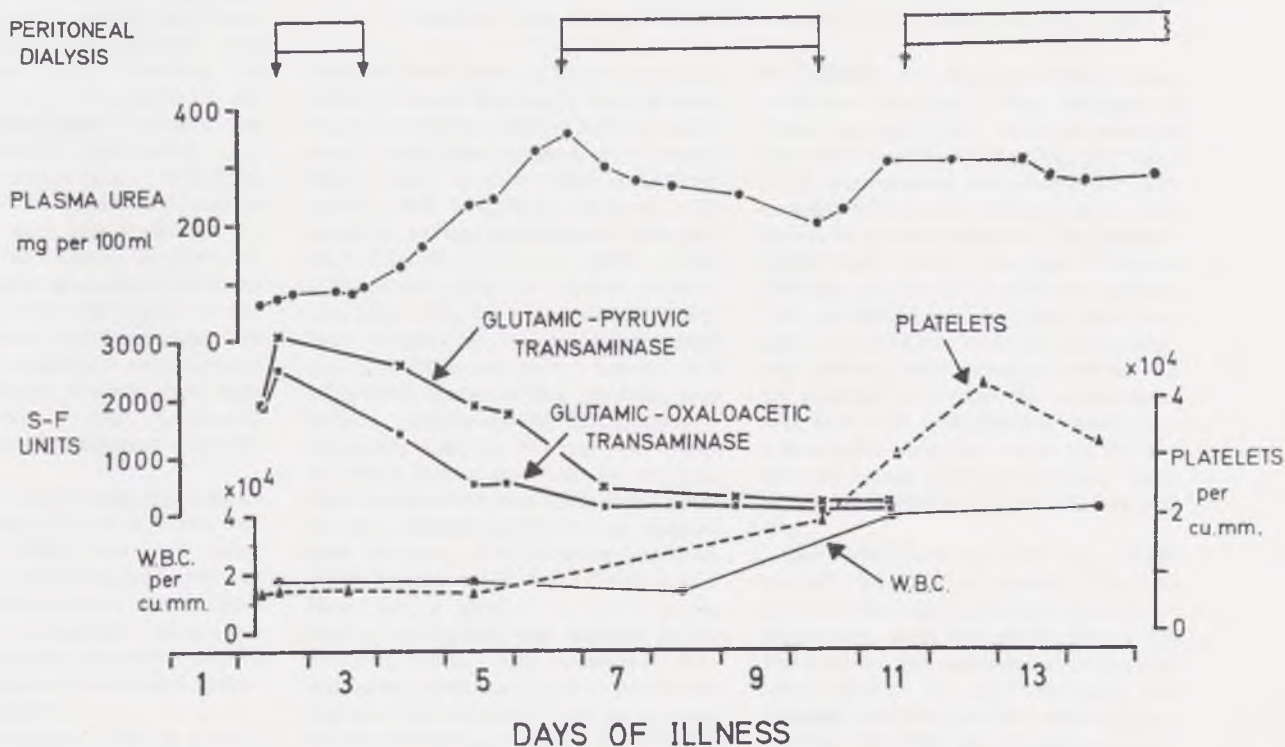


Fig 1.—Main clinical events during course of illness with temperature, blood pressure changes, and therapy.

Fig 2.—Serial changes in urea, transaminases, white blood cell counts, and platelets.



70 mm Hg, but six hours after operation at 5:20 AM it became too low to record. At this time her pulse rate was very rapid and a mild degree of jaundice was noticed. Oxygen was administered and an immediate intravenous infusion of plasma followed by saline and 2 pints of blood was given in rapid succession. Liver damage was suspected and hydrocortisone, 500 mg given once intravenously followed by smaller doses intramuscularly 6 hourly, was used in the hope of limiting extension of the damage. Within the next hour, the BP rose to 100/40 mm Hg and then more slowly to 130/70 mm Hg at 11:30 AM. Eight hours after operation 50 ml of urine was obtained by catheter. This showed protein 300 mg/100 ml but no bilirubin; red blood cells, granular casts, white blood cells were seen on microscopy.

A forced diuresis was attempted with 40 gm of mannitol given intravenously. This was unsuccessful and it appeared that acute tubular necrosis had developed. Oliguria persisted for the rest of her illness, only 20 to 60 ml of urine being obtained by catheter every 48 hours.

Laboratory results 12 hours after operation were as follows: plasma urea, 66 mg/100 ml; creatinine, 3.4 mg/100 ml; chloride, 103 mEq/liter; sodium, 138 mEq/liter; potassium, 7.1 mEq/liter; carbon dioxide, 12 mEq/liter; bilirubin, 5.1 mg/100 ml (2.5 mg/100 ml direct reacting); alkaline phosphatase, 22.6 King-Armstrong units; albumin, 3.9 gm/100 ml; globulin, 1.9 gm/100 ml; serum glutamic oxaloacetic transaminase, 1,900 Sigma-Frankel units; serum glutamic pyruvic transaminase, 1,900 Sigma Frankel units; fibrinogen, 585 mg/100 ml; fibrinogen titer, one sixteenth, lysing back to one eighth; amylase, 61 Street-Close units; hemoglobin, 9.5 gm/100 ml; white blood cell count, 18,600/cu mm; platelets, 64,000/cu mm; the blood film was consistent with normochromic normocytic anemia with burr cells, schistocytes, and neutrophil leukocytes. The Thrombotest was 25% of normal.

The patient was still deeply comatose. This was thought to be due to the tribromoethanol which was not being metabolized by the damaged liver or excreted by the damaged kidneys. Consequently, it was considered that some form of dialysis was necessary, and 16 hours after operation peritoneal dialysis (PD) was started.

Two-liter washes of 1.36%, or a mixture of 1.36% and 6.36% Dialaflex

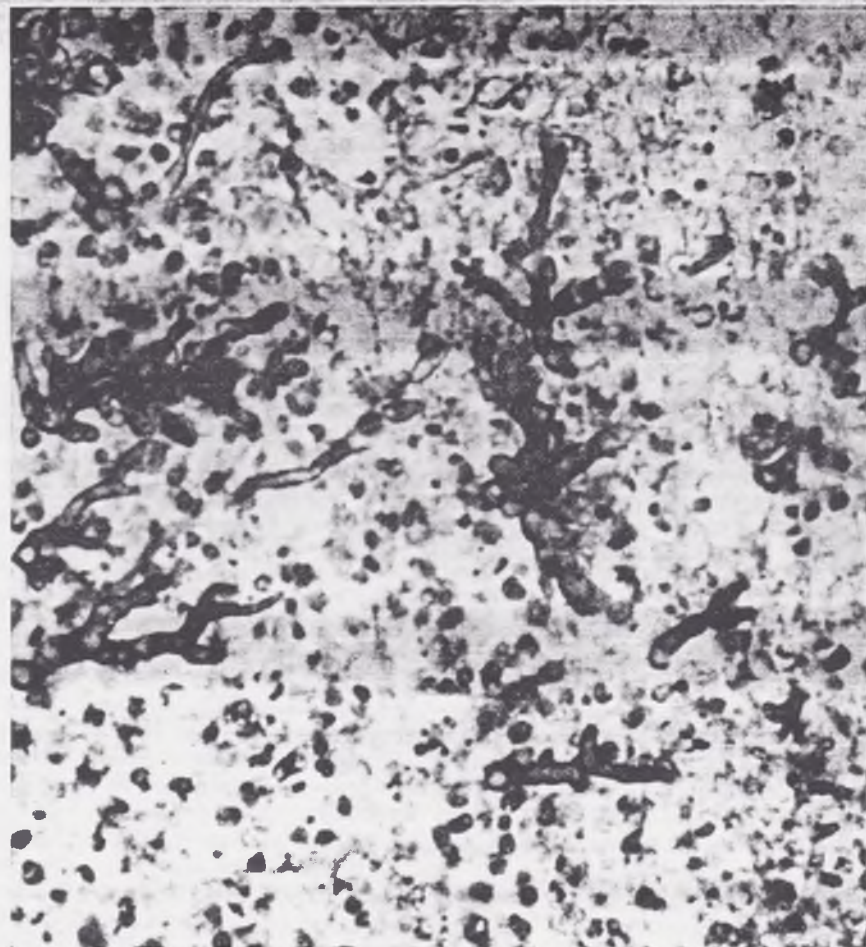


Fig 3.—Cerebral cortex showing PAS-positive mycelial mass in abscess cavity ($\times 800$).

solutions were used. (Dialaflex solution, 1.36% [Allen & Hanbury's Ltd.] is composed of sodium, 140.4 mEq/liter calcium, 3.6 mEq/liter; magnesium, 1.5 mEq/liter; total chloride, 100.8 mEq/liter; lactate, 44.6 mEq/liter; dextrose, 13.6 gm/liter; sodium metabisulfite, 0.05 gm/liter. Dialaflex solution, 6.36% [Allen & Hanbury's Ltd.] is a mixture of sodium, 140.4 mEq/liter; calcium 3.6 mEq/liter; magnesium, 1.5 mEq/liter; total chloride, 100.8 mEq/liter; lactate, 44.6 mEq/liter; dextrose, 63.6 gm/liter; and sodium metabisulphite, 0.12 gm/liter). Ampicillin sodium, 500 mg, was added to every 2-liter wash of the dialysis. She became conscious eight hours after the start of dialysis which was stopped after 30 hours. The dialysate was analyzed by the method of Kozelka and Hine⁸ and a total of 3.1 gm alcohol, mainly conjugated and thought to be tribromoethanol was recovered. Improvement continued and on the fourth day she was allowed to sit in a chair. Anuria, however, persisted. On the fifth postpartum day there was a rise of BP

to 150/100 mm Hg and further convulsions developed. The etiology of these was not clear. Between seizures she had coarse nystagmus, the eyes being permanently deviated to the right, a mild right facial weakness and a left extensor plantar response. The cerebrospinal fluid (CSF) was clear, pressure 150 mm, protein, 26 mg/100 ml, glucose 100 mg/100 ml, and no cells were present. Paraldehyde and diphenylhydantoin sodium were given at intervals in an attempt to control the convulsions, but this was unsuccessful, about ten generalized seizures occurring in the first 24 hours. Between seizures there was focal twitching of the left arm and face.

Her blood urea had now risen to 360 mg/100 ml and a second PD was started. This was continued for the next three days, until the eighth day of the puerperium, the catheter being changed once because of poor drainage and leakage from the catheter wound. During this time she was drowsy and confused, occasionally complaining of

abdominal pain. Twitching continued but seizures seemed to be controlled by paraldehyde and diphenylhydantoin sodium.

On the ninth day there was a transient fall in BP which responded to additional hydrocortisone and saline given intravenously.

On the tenth day her temperature rose to 103 F (39.4 C) and cephaloridine was substituted for ampicillin. Her blood urea was again rising and a third PD was begun at 5:30 PM. Routine culture from the abdominal wound grew no organisms but oxytetracycline was, nevertheless, added to the dialysis fluid. On the following day (11) the abdominal wound dehiscd and required resuturing. This was done with the patient under cyclopropane anesthesia. At operation the bowel looked slightly red but was otherwise normal. At this time the patient was tetraplegic and on the 12th day of the puerperium a left facial paralysis was present. The peritoneal wash now contained numerous polymorphs but no bacteria were grown aerobically or anaerobically. A repeat of the lumbar puncture showed an increase in CSF pressure to 425 mm and the fluid contained protein, 110 mg/100 ml, glucose 42, mg/100 ml, and 1,500 polymorphonuclear leukocytes per cubic millimeter, but no bacteria were grown. An echoencephalogram showed a shift of midline structures to the left which was confirmed on angiography, and a right cerebral abscess was suspected. A right temporal burr hole was made but no definite abscess cavity was found. The patient's condition continued to deteriorate and she died at 2:10 PM on the 13th day of the puerperium.

Investigation.—The bilirubin reading remained at about 5 mg/100 ml throughout. The serum transaminases showed a striking fall during the first few days (Fig 2). Azotemia was controlled by dialysis. The patient had an initial thrombocytopenia, impaired clot formation and increased fibrinolysis, which all reverted to normal. There was a neutrophil leukocytosis with a marked increase in white blood cell count during the terminal three days. Repeated blood films showed leukoerythroblastemia with schistocytes and burr cells, in keeping with a microangiopathic hemolytic anaemia. Candida was cultured on one occasion from the sputum six days after delivery. Blood glucose was normal between dialyses, but rose as high as 250 mg/100 ml during dialysis.

Postmortem Findings.—**Necropsy**

was performed 32 hours after death, and demonstrated the following positive features: There was moderate jaundice. The meningeal vessels were dilated and congested, and there was thick yellow pus in the subarachnoid space, filling the sulci and basal cisterns. The brain weighed 1,250 gm, and one abscess 0.75 cm in diameter was seen in the area of the left motor cortex near the midline. On coronal section numerous minute brown softened areas (up to 1 mm in diameter) were found in all areas of the cerebral cortex, adjacent to the sulci. Deeper in the white matter of the cerebrum, were many areas of softening, 1 to 2 mm in diameter, in the left frontal, parietal and temporal lobes. Small superficial abscesses (0.5 cm in diameter) were found on the posterior border of the left cerebellar hemisphere, and there was another small abscess medial to the dentate nucleus. On the dorsal surface of the spinal cord, among the posterior roots, were plaques of yellow gelatinous material; the largest, at the upper thoracic level, measured 1 × 2 cm. Sections at the upper thoracic level showed extensive softening in the region of the right anterior horn, extending over a length of 1.5 cm.

The frontal and ethmoidal air sinuses, and both middle and inner ears were exposed and showed no macroscopic abnormality. The lungs each weighed 475 gm, all lobes being firm, congested and edematous on section, especially at the bases. The heart (250 gm) seemed normal. The abdominal wound was intact and clean. The peritoneum throughout was covered with a soft yellow material and the loops of bowel were lightly adherent to one another. The liver (1,825 gm), apart from the surface exudate, appeared normal externally. The cut surface had a red and yellow mottled appearance and in the hilar region the parenchyma was very soft. There were no large areas of hemorrhage. The kidneys, both 230 gm, appeared large, with pale cortices and rather congested medullae; the capsules stripped easily. The uterus showed the expected involutional changes and the placental bed appeared normal.

Histologically the lesions in the brain and spinal cord were all similar, consisting of an acute pyogenic reaction containing branching gram-positive fungal mycelia (Fig 3). Gomori-silver-methenamine stain was used to screen sections from fungi and PAS stain was used for detailed study. The fungal elements could also be seen in sections stained with hematoxylin and eosin. The

microscopic appearance of the fungus was diagnostic of *Aspergillus*. The small lesions scattered throughout the hemispheres were similar micro-abscesses, containing fungal elements which in many cases had a perivascular arrangement suggesting growth along penetrating vessels. Spinal cord sections showed large "felt-works" of fungi around and invading the posterior roots. At the upper thoracic level there was destruction of the right anterior horn by fungi.

All lung sections examined showed considerable edema and congestion. Despite an extensive search using the special stains, no fungal elements were seen in either lung. Both kidneys showed intact glomeruli and acute tubular necrosis without evidence of regeneration of the tubular epithelium. The liver showed extensive periportal necrosis and fibrosis with proliferation of biliary canaliculi. There was evidence of previous hemorrhage related to the portal tracts as seen in eclampsia. The capsular surfaces showed fungal mycelia with an acute inflammatory response, but no deep invasion. The serosal surfaces of spleen, ovaries, fallopian tubes and uterus all showed overlying layers of fungal mycelium with superficial infiltration and an accompanying acute inflammatory response. Serial blocks taken from the placental bed showed no fungi. The myocardium appeared normal, except for one small area of microinfarction, which contained a single small *Medusa*-like formation of fungus.

A pure culture of *A. fumigatus* was grown from the base of the brain.

Comment

This patient's illness had two phases, both with prominent neurological features, separated by a period of improvement. The initial phase was probably atypical eclampsia and the postmortem findings of old periportal hemorrhage with necrosis and fibrosis supported the clinical evidence of eclamptic liver necrosis. Acute tubular necrosis may have been precipitated by severe hypotension in the early postpartum period. In retrospect she probably received too much sedation, particularly of tribromoethanol. This drug is valuable in controlling eclamptic seizures, and is normally rapidly

conjugated in the liver and then excreted by the kidneys. In excessive dosage it can cause liver damage and this is particularly liable to happen if there is already impaired liver function. It can also cause proteinuria and frank renal damage especially if renal function is already impaired.⁶ At the time, the need to control the convulsions was paramount, and for this reason the 5.3-ml dose was repeated once. Dialysis played an important part in her rapid early improvement, and approximately one third of the tribromoethanol she had received was recovered from the dialysate. Hemodialysis was not used because of the risk of hemorrhage due to the low platelet count, and because it was considered undesirable to move this critically ill patient to the hemodialysis unit which is in another hospital.

The second phase of the patient's illness, beginning on the fifth postpartum day was puzzling. In the light of the postmortem findings, we presume now that she was developing a fulminating *Aspergillus* meningoencephalomyelitis. The route of entry appears to have been across the peritoneum, which was found to be extensively involved at postmortem. In most of the reported cases of disseminated aspergillosis, the route of entry was through the lungs, the nasal sinuses or the ears; in this case the postmortem findings excluded these.

The cause of the convulsions which started on the fifth postpartum day is conjectural. If infection and dissemination to the central nervous system had already occurred by that time it is curious that she was afebrile until the ninth day. The finding of normal CSF on day 5 does not exclude a small localized cortical abscess as a cause of these convulsions, and if this is true the onset of pyrexia on day 9 probably marked the spread of a rapidly fatal meningoencepha-

lomyelitis from a localized focus.

Zimmermann⁷ attributed the dissemination of fungus in the body to a combination of three factors, all of which obtained in this case. These are a general lowering of resistance by a debilitating disease (usually a leukemia or malignant lymphoma), a local point of entry for the fungus, and the use of antibiotics causing suppression of the normal bacterial flora. Subsequent studies,^{1,2,8-11} have supported this and emphasized the role of steroids in the suppression of inflammatory response. On the other hand, the recent description¹² of rapidly fatal pulmonary aspergillosis in two young sisters, occurring almost simultaneously, shows that even in the absence of steroids, antibiotics or an underlying illness, *Aspergillus* may cause a rapidly fatal infection.

A case with interesting similarities to our own is described by Finegold et al.⁹ Their case 9 was a 33-year-old woman in whom acute renal failure developed following a septic abortion. She showed transient improvement after hemodialysis and two peritoneal dialyses but was intermittently febrile, and died after seven weeks of illness. Postmortem examination revealed disseminated aspergillosis with involvement of heart, lungs, spleen, brain, and uterus. The route of entry was not established with certainty, and the possibility that it entered during peritoneal dialysis was not discussed.

In our case it was a striking finding at postmortem that, apart from the peritoneal surfaces and a very small focus in the myocardium, the brain and spinal cord were the only areas where the *Aspergillus* had grown. Aspergillosis of the brain, spinal cord, or meninges may occur as a result of direct spread from adjacent structures; following intrathecal injections¹³; in the drug addict who injects himself¹⁴; or without evident portal of entry or primary focus.¹⁵⁻¹⁷ It may also be

part of a generalized disseminated aspergillosis often involving many organs and usually with a primary focus in the lung.^{1,2,9,10,18} The lesions may vary from a slowly growing localized granuloma or abscess,¹⁵ to the fulminating meningoencephalomyelitis seen in our case. In a review of 23 cases of disseminated aspergillosis, Tan et al¹ found that the brain was involved in 15 cases and was second in frequency only to the lungs (19 cases) which were often the portal of entry and therefore involved primarily. The postmortem findings in our case suggest that, in the event of a hematogenous infection, the surfaces of the brain and spinal cord are more suitable than other organs for the proliferation of *Aspergillus*.

The causative organism, *A. fumigatus* is a common air contaminant and was isolated from two out of ten plates exposed to the air, and from three of eight swabs taken from various points, in the labor suite in which the patient was nursed. Access may have been direct from the air, through the peritoneal dialysis puncture wound. However, recent investigation of our stocks of peritoneal dialysis fluid (Dialaflex) which is supplied in plastic containers has shown an incidence of leakage and organismal contamination in 2%, and in many the growth was fungal.¹⁹ *Aspergillus fumigatus* was not one of the organisms isolated from this fluid but the organism cultured at postmortem from our patient grew well at room temperature in fluid of both high (6.36 gm/100 ml) and low (1.36 gm/100 ml) glucose concentrations. When this patient was dialysed we were not aware of the hazard associated with these bags, and leakage without gross contamination could easily have been missed. We have no direct evidence for implicating the dialysis fluid in this case, although it must have provided a favorable cul-

ture medium for the organism once inoculated.

This experience demonstrates that peritoneal dialysis must now be considered an additional predisposing cause for mycotic infection, in this instance by *A fumigatus*. We now believe that the prophylactic addition of broad-spectrum antibiotics to peritoneal dialysis fluid is wrong. First, bacterial peritonitis may still occur due to resistant organisms, and second, when peritonitis does complicate peritoneal dialysis it is usually readily controlled subsequent to diagnosis by adding the appropriate antibiotic to the peritoneal dialysis fluid. The use of a broad-spectrum antibiotic, as in this case, is no safeguard against fungal infection. We suggest that routine culture of peritoneal dialysis fluid

should be done at least twice daily, and should include the use of Sabouraud's medium.

Summary

Rapidly fatal *Aspergillus fumigatus* meningoencephalomyelitis complicated peritoneal dialysis in a 22-year-old woman with eclamptic liver necrosis and acute renal tubular necrosis. Important factors were (1) the underlying illness, antibiotic therapy, and use of high doses of hydrocortisone, all of which encourage the growth and dissemination of fungi; and (2) the florid growth of the *Aspergillus* on all the peritoneal surfaces, bathed as they were in a strong glucose fluid.

Professor Sir Ian Hill, Prof A. C. Len-drum, Prof James Walker, and Mr. J. Block, FRCS, gave help and constructive

criticism. Miss Margaret I. Wilson, MSc, did the mycological investigation; Mr. R. S. Nicolson, FRIC, public analyst, did the tribromoethanol estimations. Mr. J. W. Corkhill, Department of Pathology, provided the photomicrograph.

Generic and Trade Names of Drugs

Phenobarbital—*Luminal*.
Meperidine hydrochloride—*Demerol Hydrochloride*, *Pro-Meperdan*.
Tribromoethanol—*Avertin*.
Succinylcholine chloride—*Anectine Chloride*, *Quelicin Chloride*, *Sucostrin Chloride*.
Mannitol—*Osmitrol*.
Ampicillin sodium—*Penbritin-S*, *Poly-cillin*.
Diphenylhydantoin sodium—*Denyl Sodium*, *Dilantin Sodium*, *Diphentoin*.
Hydrocortisone—*Cortef*, *Cortril*, *Hycortole*, *Cortijan*, *Hydrocortone*.
Oxytetracycline hydrochloride—*Terramycin Hydrochloride*.
Cyclopropane—*Trimethylene*.

References

1. Tan, K.K.; Sugai, K.; and Tan, K.L.: Disseminated Aspergillosis: Case Report and Review of the World Literature, *Amer J Clin Path* 45: 697-703, 1966.
2. Spens, N., and Tattersall, W.H.: Fungal Infection of Central Nervous System Supervening During Routine Chemotherapy for Pulmonary Tuberculosis, *Brit Med J* 2:862, 1965.
3. Fisher, A.M., et al: Generalized Tuberculosis With Pancytopenia: Report of a Case With Aspergillosis as a Terminal Event, *Bull Hopkins Hosp* 119:355-362, 1966.
4. Sayle, B.A., et al: Cushing's Syndrome Due to Islet Cell Carcinoma of the Pancreas: Report of Two Cases. One With Elevated 5-hydroxyindole Acetic Acid and Complicated by Aspergillosis, *Ann Intern Med* 63:58-68, 1965.
5. Kozelka, F.L., and Hine, C.H.: Method for Determination of Ethyl Alcohol for Medicolegal Purposes, *Industr Eng Chem (Analytical)* 13:905-907, 1941.
6. Goodman, L.S., and Gilman, A.: *The Pharmacological Basis of Therapeutics*, ed 2, New York: The Macmillan Co., Publishers, pp 95-97, 1960.
7. Zimmerman, L.E.: Candida and Aspergillus Endocarditis, With Comments on Role of Antibiotics in Dissemination of Fungus Disease, *Arch Path* 50:591-605, 1950.
8. Keye, J.D., Jr., and Magee, W.E.: Fungal Diseases in a General Hospital: A Study of 88 Patients, *Amer J Clin Path* 26:1235-1253, 1956.
9. Finegold, S.M.; Will, D.; and Murray, J.F.: Aspergillosis: A Review and Report of 12 Cases, *Amer J Med* 27:463-482, 1959.
10. Grcevic, N., and Matthews, W.F.: Pathologic Changes in Acute Disseminated Aspergillosis: Particularly Involvement of the Central Nervous System, *Amer J Clin Path* 32:536-551, 1959.
11. Gowing, N.F.C., and Hamlin, I.M.E.: Tissue Reactions to Aspergillus in Cases of Hodgkin's Disease and Leukemia, *J Clin Path* 13:396-413, 1960.
12. Strelling, M.K., et al: Fatal Acute Pulmonary Aspergillosis in Two Children of One Family, *Arch Dis Child* 41:34-43, 1966.
13. Wybel, R.E.: Mycosis of the Cervical Spinal Cord Following Intrathecal Penicillin Therapy: Report of Case Simulating Cord Tumor, *Arch Path* 53:167-173, 1952.
14. Burston, J., and Blackwood, W.: A Case of Aspergillus Infection of the Brain, *J Path Bact* 86: 225-229, 1963.
15. Iyer, S.; Dodge, P.R.; and Adams, R.D.: Two Cases of Aspergillus Infection of the Central Nervous System, *J Neurol Neurosurg Psychiat* 15: 152-163, 1952.
16. Jackson, I.J.; Earle, K.M.; and Kuri, J.: Solitary Aspergillus Granuloma of the Brain, *J Neurosurg* 12:53-61, 1955.
17. Ziskind, J.; Pizzolato, P.; and Buff, E.E.: Aspergillosis of the Brain: Report of a Case, *Amer J Clin Path* 29:554-559, 1958.
18. Cawley, E.P.: Aspergillosis and Aspergilli: Report of Unique Case of the Disease, *Arch Intern Med* 80:423-434, 1947.
19. Stewart, W.K.; Anderson, D.C.; and Wilson, M.I.: Hazard of Peritoneal Dialysis: Contaminated Fluid, *Brit Med J* 1:606-607, 1967.