

Neurologic Complications Following Pediatric Orthotopic Liver Transplantation

B. Gridelli, A. Lucianetti, G. Rodriguez, S. Gatti, L.R. Fassati, D. Galmarini, and L.N. Rossi

NEUROLOGIC complications represent an important source of morbidity and mortality after orthotopic liver transplantation (OLT). Metabolic and hemodynamic alterations, occurring during or early after the transplant operation, and drugs and infections can produce functional modifications of cerebral activity or lesions of cerebral parenchyma. Children have been reported to be more exposed than adults to cerebrovascular accidents in the postoperative period of liver transplantation.¹ In this article, we report the course of our pediatric patients who presented serious neurologic complications after OLT.

PATIENTS AND METHODS

Between February 1988 and March 1993, 33 pediatric patients (pts) (age range 7 months to 15 years) underwent OLT at our institution. The indications to OLT were: biliary atresia (12 pts), metabolic disease (6 pts), Byler's disease (5 pts), fulminant hepatitis (5 pts), cryptogenic cirrhosis (2 pts), hepatocellular carcinoma (2 pts), and sclerosing cholangitis (1 patient). All pts were immunosuppressed with low dose steroids and cyclosporine (CyA); steroid-resistant episodes of acute rejection were treated with monoclonal anti-T-cell antibodies (OKT3). CyA whole blood level was determined with RIA or TDX polyclonal methods. To study the occurrence of neurologic complications in our pediatric population, the clinical records of the children were reviewed including the EEGs, head CT scans, and autopsy reports of patients whose main cause of death was neurologic.

RESULTS

The overall 3-year survival rate of our pediatric pts is 70%. Four pts (12.1%) had neurologic complications: 2 children had cerebral lesions that were responsible for coma and death, and 2 had seizure episodes.

Case 1 (OLT 50): A 1-year-old male child with biliary atresia was in the intensive care unit (ICU) because of bleeding from esophageal varices, sepsis, and ascites when a donor became available. He underwent a reduced-size OLT; the operation was long and complicated by the presence of abscess cavities at the hylum of the liver. Intraoperatively, and within the first 48 hours after the transplant operation, the serum sodium fluctuated between 123 and 166 mEq/L and blood glucose between 25 and 1000 mg/dL. On postoperative day 3, the child developed coma which persisted until post-OLT day 30 when he died of multiple-system organ failure. This child was treated with OKT3 for a severe episode of acute rejection which occurred on postoperative day 8.

The postmortem examination revealed severe diffuse hypoxic neuronal damage, affecting mainly the cerebral

cortex, and systemic cytomegalovirus (CMV) infection, involving the brain, lungs, heart, liver, and intestine.

Case 2 (OLT 131): A 2-year-old female child with biliary atresia was admitted to our ICU for severe gastrointestinal hemorrhage, disseminated intravascular coagulopathy, renal and respiratory failure, and ascites. An EEG showed mild slowing of electric cerebral activity and CT scan showed a small left supraorbital hyperdense area which was interpreted as a hemorrhagic lesion. Two weeks after admission to the ICU, during which she continued to have severe episodes of bleeding from mucosal gastric erosions, she was transplanted with a full-size liver graft. The early graft function was good and the clinical situation of the patient improved. Eleven days after OLT, OKT3 therapy was started because of steroid-resistant acute rejection and on postoperative day 20 she had to be reoperated on because of massive gastrointestinal bleeding. During surgery she was found to have a perforation of the gastric wall and an abscess eroding the inferior face of the left liver lobe from which *Aspergillus fumigatus* was isolated. Intravenous amphotericin administration was immediately started, but 2 days later the patient became lethargic and CT scan showed the presence of intracerebral abscesses (Fig 1). The child died on the following day and at autopsy two cerebral abscesses containing *Aspergillus* were found. *Aspergillus* was also demonstrated in the gastric mucosa.

Case 3 (OLT 111): A 10-year-old boy underwent OLT because of biliary cirrhosis secondary to cystic fibrosis with minimal lung involvement. His early postoperative course was uneventful, but 45 days after OLT he had seizures. Hematology and biochemical (kidney and liver function, serum electrolytes) tests were all normal except for serum magnesium level which was 1.6 mEq/L; the CyA blood level was 640 ng/mL. EEG showed slow electric activity in the right parieto-occipital region and CT scan showed a small laminar ischemic lesion in the left external capsule. Treatment with carbamazepine was immediately started and maintained for 18 months. At 3-year follow-up he had no seizure recurrence.

From the Liver Transplantation Center of the Ospedale Maggiore-IRCCS (B.G., A.L., S.G., L.R.F., D.G.), and The First Pediatric Clinic (G.R., L.N.R.), of the University of Milan, Milan, Italy.

Supported in part by the Grant "Health Ministry: 1990 Target Biennial Research: Pediatric Liver Transplantation."

Address reprint requests to Bruno Gridelli, MD, Liver Transplantation Center, Ospedale Maggiore, via F. Sforza 35, 20122 Milan, Italy.

© 1994 by Appleton & Lange
0041-1345/94/\$3.00/+0

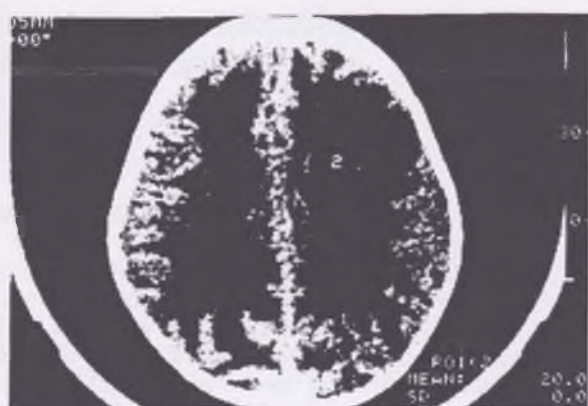


Fig 1. Case 2 (OLT 131). The CT scan shows small gas collections in the posterior parietal region (1); anteriorly (2), a round hypodense area surrounded by hyperdense pad is evident.

Case 4 (OLT 145): A 2-year-old girl with portal hypertension and cirrhosis secondary to cholesterol ester storage disease underwent OLT. The immediate graft function was excellent and she recovered quickly from surgery. Four days after the transplant operation the patient had seizures; the EEG showed diffuse epileptic activity and the CT scan was normal. The serum magnesium level was 1.4 mEq/L and CyA blood level was 1197 ng/mL. Phenobarbital therapy was immediately started but the patient had recurrence of seizures 4 days later. The dose of phenobarbital was increased and maintained for 18 months, and then slowly discontinued. At the follow-up of over 2 years after OLT, the patient is free from seizure recurrence.

DISCUSSION

Neurologic complications occurring after liver transplantation range from minor alterations of mental status to lesions of the brain that can represent cause of death. Pediatric patients have been reported to have more cerebrovascular complications than adults, such as global cerebral ischemia, hemorrhages, and infarcts.¹ Severe neurologic complications occur mainly in patients transplanted under very poor clinical conditions and/or have a stormy intraoperative and early postoperative course. This combination of events was evident in both our patients who developed lethal neurologic complications. In case 1 the onset of coma was concomitant with significant fluctuations of serum sodium which occurred during and early

after the operation. Rapid modifications of natremia have been implicated in the pathogenesis of central pontine and extrapontine myelinolysis (CPM),² and although in our patient the typical CPM lesions were not found at autopsy it is possible that serum sodium fluctuations played an important role in the occurrence of cerebral lesions to which CMV also participated.

Aspergillosis is a well-recognized complication in immunosuppressed transplant patients and the lower respiratory tract is probably the main port of entry for *Aspergillus* spp that can then reach other organs by hematogenous spread.^{1,3,4} We believe that, in case 2, the port of entry of the *A fumigatus* that was found in the brain abscesses might have been the stomach since the fungus was also found in the gastric mucosa. Following this case, whenever one of our patients before or after the OLT presents gastric bleeding, a search for *Aspergillus* spp in the gastric aspirate and mucosa is performed.

Seizures are one of the most common neurologic complications after OLT and have been reported in as many as 25% of pts and half of the time the onset was in the first postoperative week.⁵ Electrolytes and metabolic abnormalities, drug-induced effects (particularly from CyA), and cerebral lesions have been described as causes of seizures in OLT patients. Posttransplant seizures have also been reported with higher frequency in children than adults. In our two patients no clear etiologic factor of epileptic activity could be identified although both had mild hypomagnesemia, one of them also having a small cerebral ischemic lesion and the other a CyA blood level above 1000 ng/mL. It has been suggested that CyA is in itself epileptogenic, particularly during intravenous administration.⁶ Discontinuation of anticonvulsant therapy did not cause recurrence of seizure in any of our patients confirming that posttransplant epileptic activity is frequently secondary to self-limited causes.

REFERENCES

1. Martinez AJ, Barmada MA: *Modern Pathol* 6:25, 1993
2. Estol CJ, Faris AA, Martinez AJ, et al: *Neurology* 39:493, 1989
3. Rubin RH, Hooper DC: *Med Clin N Am* 69:281, 1985
4. Boon AP, Adams DH, Buckels J, et al: *J Clin Pathol* 43:114, 1990
5. Adams DH, Ponsford S, Gunson B, et al: *Lancet* i:949, 1987
6. Grigg MM, Costanzo-Nordin MR, Celesia GG, et al: *Transplant Proc* 20:937, 1988