

# Intracerebral infections OPAT challenges

Eoghan de Barra

Infectious Diseases Consultant ICHNT

## Outpatient Parenteral Antimicrobial Therapy for Central Nervous System Infections

Alan D. Tice, Kevin Strait, Rob Ramey,  
and Pamela A. Hoaglund

*From Infections Limited, P.S., Tacoma, Washington*

- “serious, difficult, and potentially debilitating”  
“potential for complications, patients with these infections are almost always hospitalized.”

## Data concerning patients receiving outpatient parenteral antimicrobial therapy (OPAT) for CNS infections.

Variable	CNS infection				Total
	Meningitis	Brain abscess	Encephalitis	Other <sup>a</sup>	
No. of patients	29	19	5	15	68
Age in years, mean (range)	34.2 (1–70)	43.5 (15–81)	30.0 (8–60)	41.5 (4–71)	37.3 (1–81)
Duration of OPAT, days	232	744	31	279	1286
Mean (range)	8 (3–21)	39.2 (8–89)	6.2 (3–9)	18.6 (2–47)	18 (2–89)
Site of OPAT, no. of patients					
Home	19	15	5	9	48 (71%)
Office	9	3	0	5	17 (25%)
Skilled nursing facility	1	1	0	1	3 (3%)
Duration of hospitalization, days	168	242	38	179	627
Mean (range)	5.8 (2–14)	12.2 (4–53)	7.6 (6–9)	11.9 (2–33)	9.5 (2–53)

<sup>a</sup> Includes shunt infections (6), epidural abscess (5), neurosyphilis (1), intraspinal C-7 abscess (1), subdural abscess (1), and infected hematoma (1).

Tice A D et al. Clin Infect Dis. 1999;29:1394-1399

## Complications of outpatient parenteral antimicrobial therapy (OPAT) for CNS infections.

Complication	Infection				Total
	Meningitis	Brain abscess	Encephalitis	Other <sup>a</sup>	
Seizures	1 (1.5)	1 (1.5)	0	0	2 (3)
Hospitalization <sup>b</sup>					
Surgical	1 (1.5)	1 (1.5)	0	3 (4.4)	5 (7.4)
Medical	2 (3)	3 (4.4)	1 (1.5)	0	6 (8.8)
Total	3 (4.4)	4 (5.9)	1 (1.5)	3 (4.4)	11 (16)
Change of antimicrobial	2 (3)	10 (15)	0	0	12 (18)

NOTE. Data are no. (%) of patients.

<sup>a</sup> Includes shunt infections (6), epidural abscess (5), neurosyphilis (1), intra-spinal C-7 abscess (1), subdural abscess (1), and infected hematoma (1).

<sup>b</sup> Hospitalization that occurred after OPAT was started.

Tice A D et al. Clin Infect Dis. 1999;29:1394-1399

# Outline

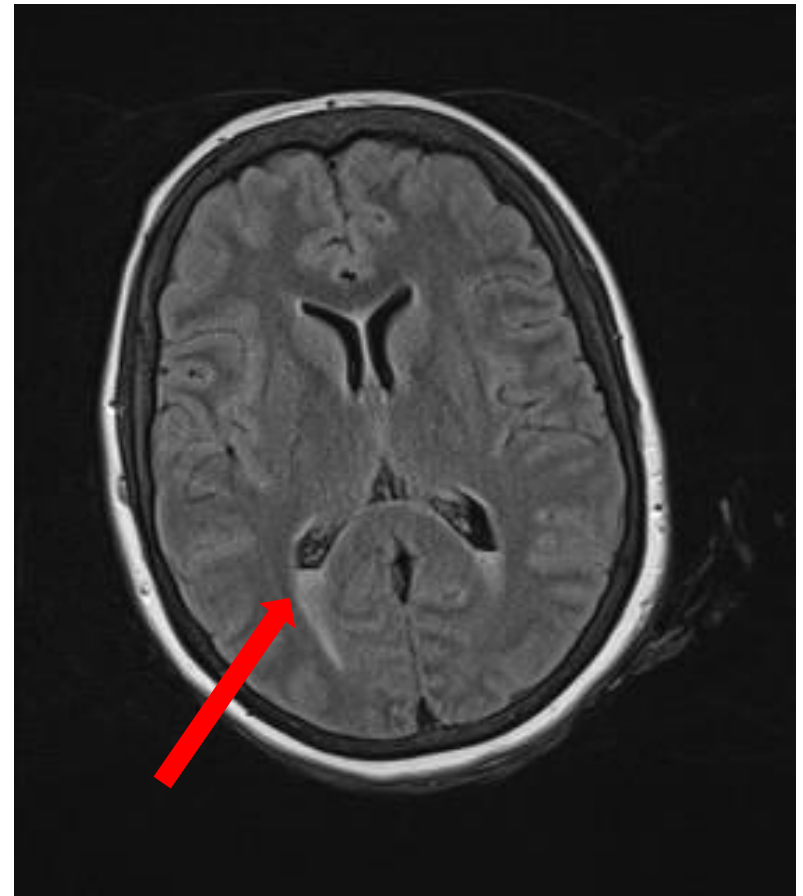
- Cases
  - Meningitis
  - Brain abscess
  - Malignant Otitis Externa
  - Post operative
- Imperial OPAT
- Summary

# Case A

- 35 somalian female transferred from DGH Post partum with drowsiness +neck stiffness + collapse.
- 2 days earlier had vaginal delivery by ventouse +forceps under Epidural and since then she has been encephalopathic was on Co-amoxiclav for prolonged labour.
- New born grew beta haemolytic Strep from skin.

# Case A

- CSF WCC 5600, no organisms, no growth.
- MRI brain 14/11/14 : pus in the ventricles
- MRI spine : No epidural abscess or collections.
- Ceftriaxone 2g BD and Amoxicillin 2g QDS, 10 days in hospital
- OPAT Ceftriaxone completing 21 days



- Intrapartum ventriculitis
  - Breast feeding
  - Early discharge
  - Monitoring for complications



# Risk of hydrocephalus in meningitis

- Hydrocephalus was diagnosed in 26 of 577 episodes (5%)
- The majority of patients (69%) presented with hydrocephalus on admission

*Neurology September 7, 2010 vol. 75 no. 10 918-923. Hydrocephalus in adults with community-acquired bacterial meningitis E. Soemirien Kasanmoentalib, Diederik van de Beek.*

## **PATIENT SELECTION**

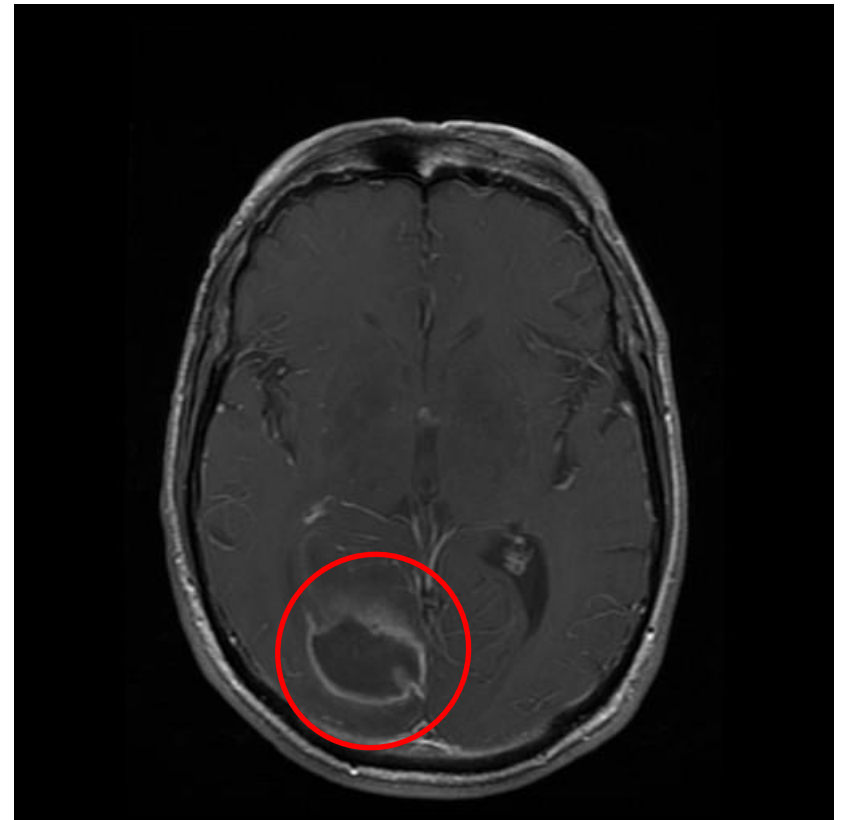
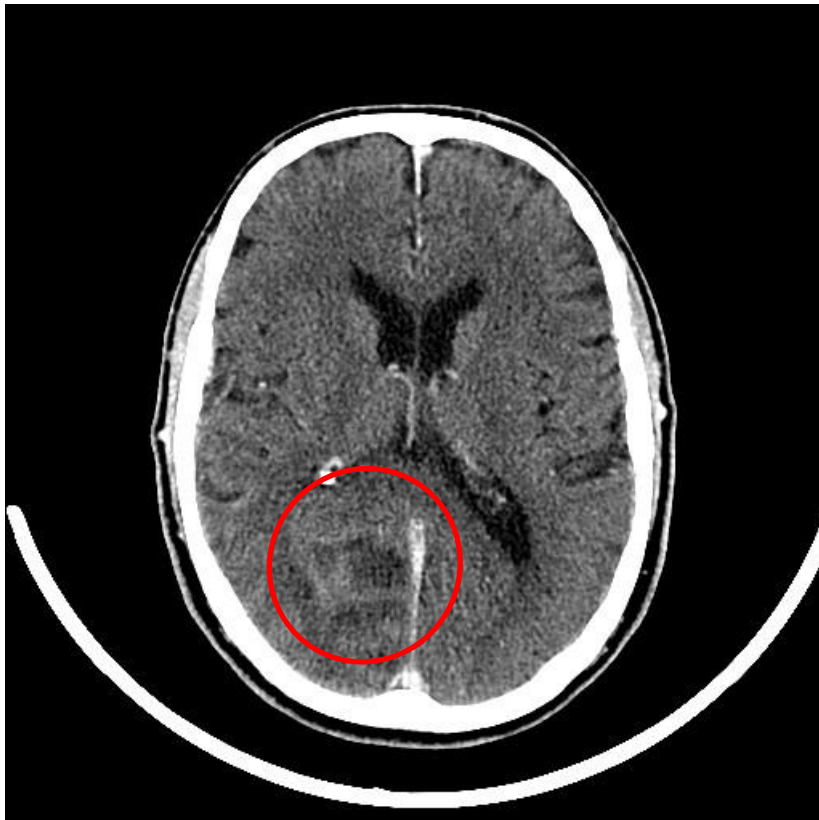## **Criteria for outpatient antimicrobial therapy in patients with bacterial meningitis (A-III).**

---

- Inpatient antimicrobial therapy for  $\geq 6$  days
- Absence of fever for at least 24–48 h prior to initiation of outpatient therapy
- No significant neurologic dysfunction, focal findings, or seizure activity
- Clinical stability or improving condition
- Ability to take fluids by mouth
- Access to home health nursing for antimicrobial administration
- Reliable intravenous line and infusion device (if needed)
- Daily availability of a physician
- Established plan for physician visits, nurse visits, laboratory monitoring, and emergencies
- Patient and/or family compliance with the program
- Safe environment with access to a telephone, utilities, food, and refrigerator

## Case B

- 70 year old male
- Stroke thrombolysis call, acute visual loss



# Case B

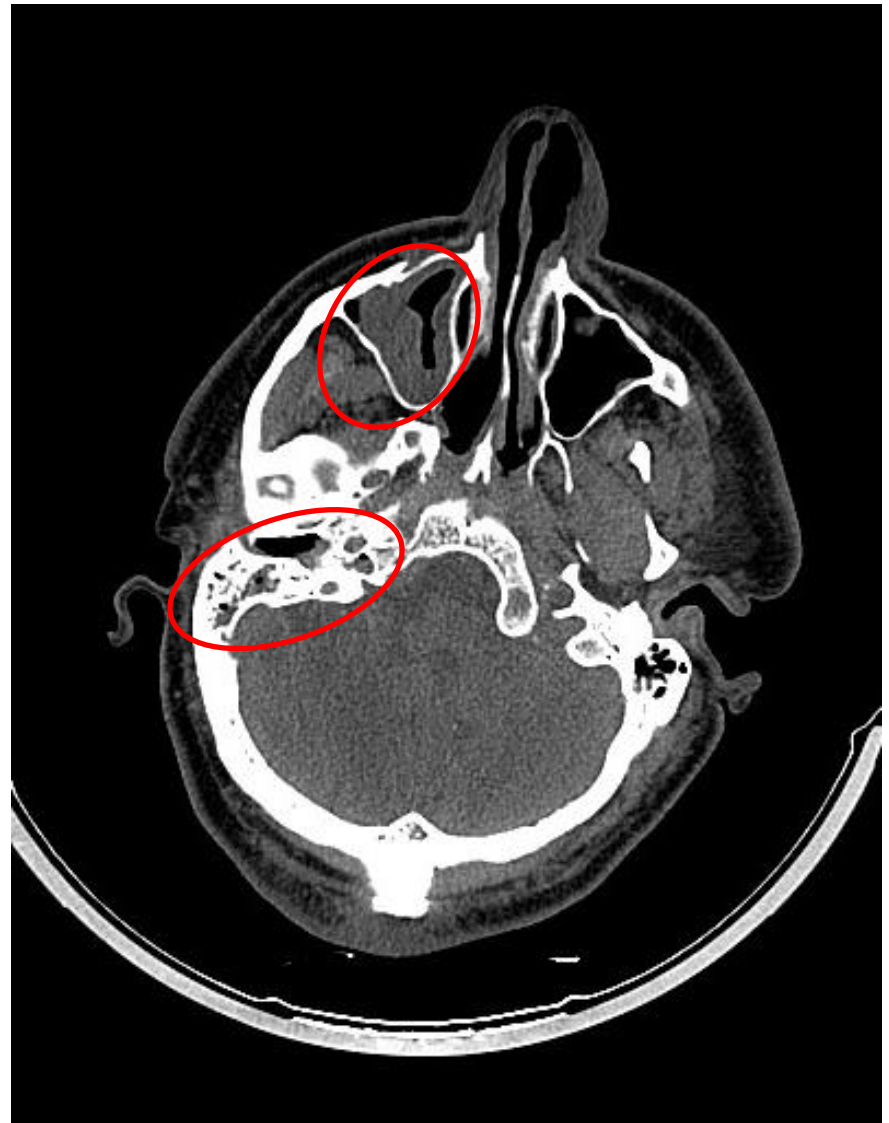
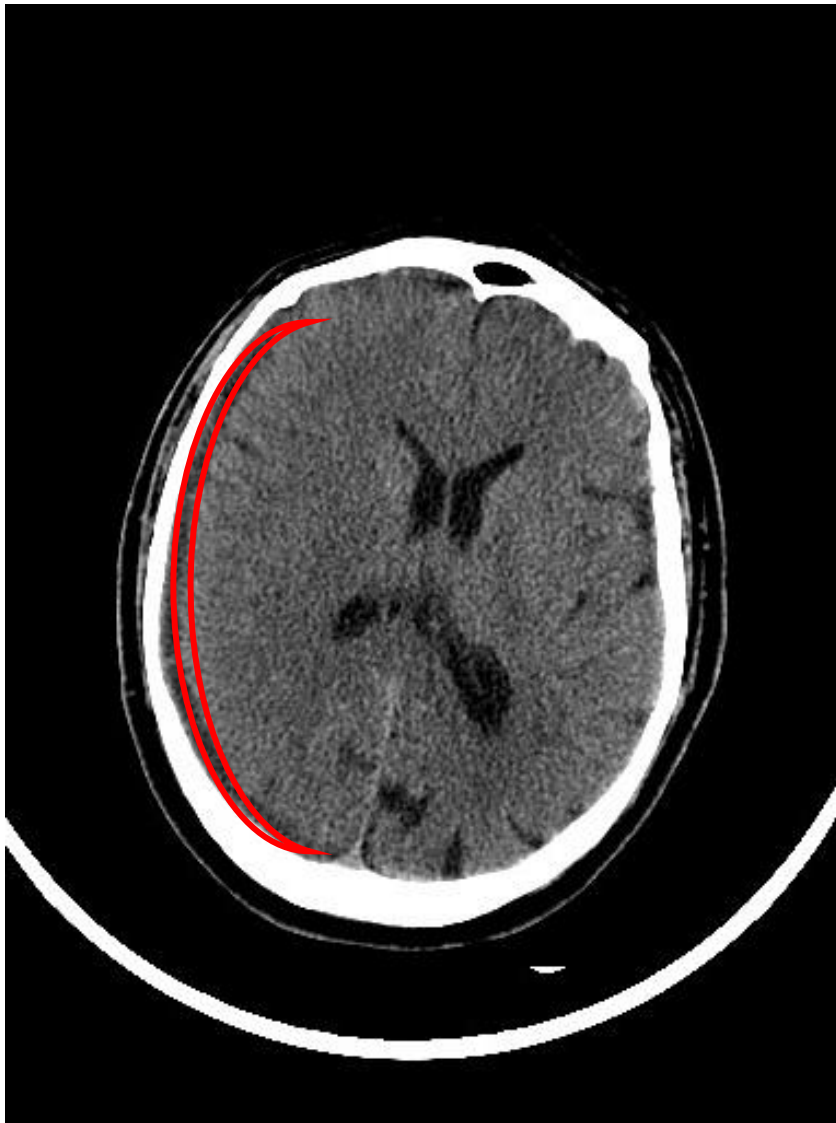
- Surgical aspiration
- Viridans Strep.
- Visiting London, S-OPAT training
- Homonymous hemianopia
- **Diagnosis: Right Occipital Intracranial Abscess**
- Planned 6 week:

Ceftriaxone	2g/IV/BD
Metronidazole	400mg/PO/TDS

**NEUROLOGICAL FUNCTION**

# Case C

- 60 year old copywriter
- Admitted with confusion
- Unable to give a history
- Febrile



# Case C

*Streptococcus pneumoniae* **right sided brain empyema**

<b>Day 1:</b>	Amoxicillin	1g IV TDS
<b>Day 2-5:</b>	Benzyl penicillin	1.2g IV 4hourly
Day 5:	Tonic clonic seizure	
	Levetriacetam	
	Ceftriaxone	2g IV BD
	Burr hole drainage	

**SEIZURES**

# Neurotoxic effects associated with antibiotic use: management considerations

Marie F. Grill<sup>1</sup> & Rama K. Maganti<sup>2</sup>

<sup>1</sup>University of California San Francisco, San Francisco General Hospital, 1001 Potrero Avenue, 4M62, San Francisco, CA 94110 and <sup>2</sup>Barrow Neurology Clinics, 500W Thomas Road, Suite 300, Phoenix, AZ 85013, USA

Grill MF, Maganti RK. Neurotoxic effects associated with antibiotic use: management considerations. *British Journal of Clinical Pharmacology*. 2011;72(3):381-393.

Antibiotic class	Number of publications	Neurotoxic effects	Mechanism of neurotoxicity	Risk factors
<b>Aminoglycosides:</b> 1. Gentamicin 2. Streptomycin 3. Amikacin 4. Tobramycin 5. Neomicin 6. Kanamycin	5: retrospective case reviews; case series; case reports	Ototoxicity-class effect Peripheral neuropathy; encephalopathy (gentamicin) Neuromuscular blockade-class effect	Activation of NMDA receptors Lysosomal abnormality; Axonal loss; Inflammatory response Inhibition of pre-synaptic quantal release of acetylcholine and binding of drug to postsynaptic receptors	Increased CNS permeability Intrathecal administration
<b>Beta lactams- Cephalosporins:</b> <b>High risk agents:</b> 1. Cefazolin 2. Cefesolis 3. Cefazidime 4. Cefoperazone 5. Cefepime <b>Low risk agents:</b> 1. Cephalexin 2. Cefatoxime 3. Ceftriaxone	24- Case reports; retrospective reviews; review articles	Encephalopathy with Triphasic waves on EEG Tardive seizures Seizures NCSE Myoclonus Asterix	Inhibition of GABA-A release; Increased glutamate; Induction of endotoxins; Cytokine release	Renal failure Prior CNS disease Older age Excess dosage
<b>Beta-lactams- Penicillins:</b> 1. Benzylpenicillin 2. Penicillin G 3. Piperacillin 4. Ticarcillin 5. Ampicillin 6. Amoxicillin 7. Oxacillin	4: Case reports; case series	Seizures Tardive seizures Encephalopa Tremors	Inhibition of GABA-A receptors	Renal failure; low birth weight-neonates
<b>Beta-lactams Carbapenems</b> 1. Imepenenem 2. Meropenem 3. Paripenem 4. Ertapenem 5. Doripenem 6. Ceftaroline	4: Case reports	Encephalopathy Seizures Myoclonus Headache	Inhibition of GABA-A receptors; Possibly binding of glutamate	Renal failure



# Seizures

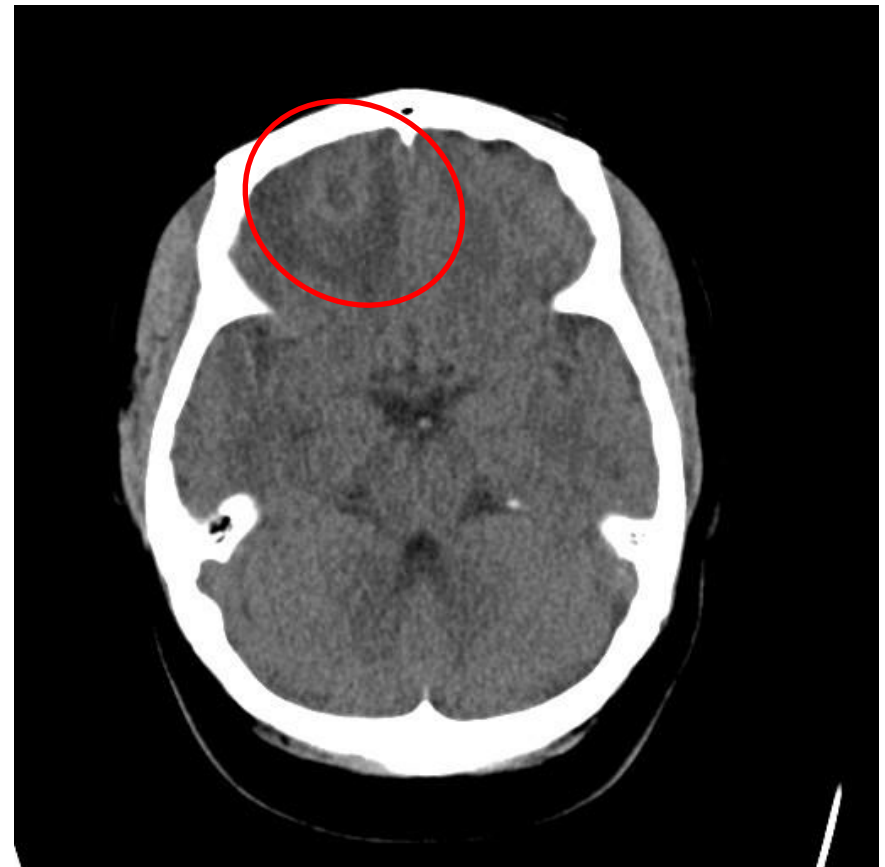- occur in 20%—30% of patients with meningitis, usually at the time of diagnosis or within the first few days of hospitalization
- a late complication in up to 90% of patients with brain abscesses.

*Tice A D et al. Clin Infect Dis. 1999;29:1394-1399*

*Brown RB. Selection and training of patients for outpatient intravenous antibiotic therapy. Rev Infect Dis 1991;13:S147-51.*

# Case D

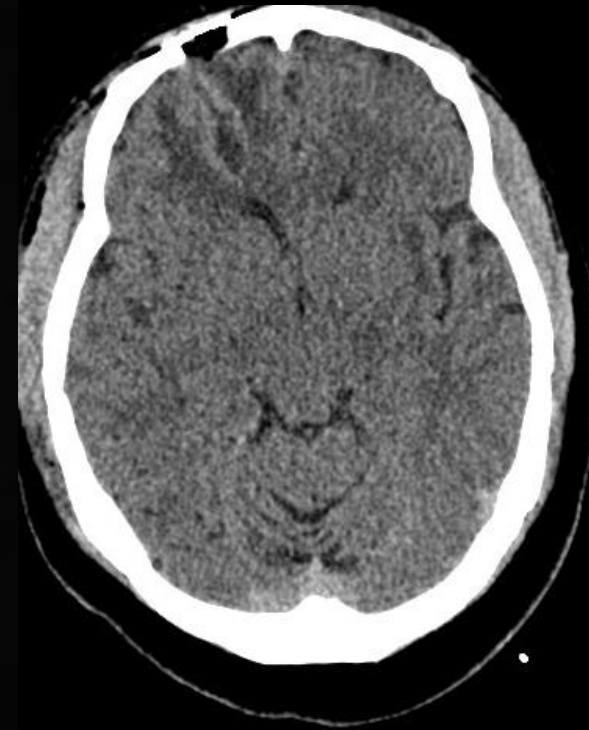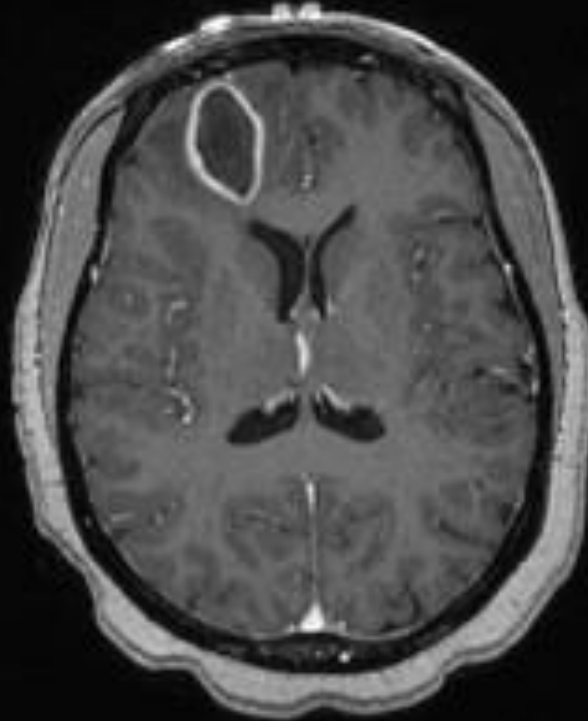
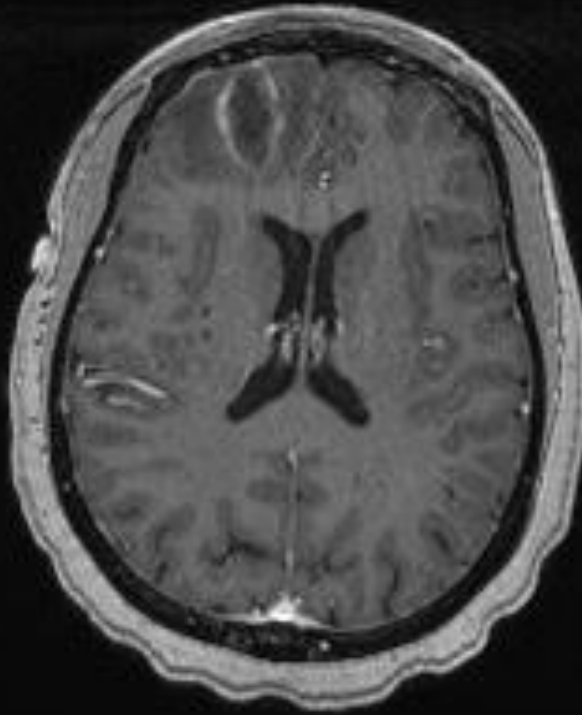
- Collapse GCS 3



Day 2

8

10



# Case D

- Diagnosis: Cerebral Abscess (culture negative)
- Antimicrobials:
  - 8 weeks Metronidazole                      400mg, PO, TDS
  - 5 weeks Ceftriaxone                      2g, IV, BD
  - 3 weeks Cefuroxime                      500mg PO BD
- Drainage optimal
  - Diagnostic, therapeutic

**SOURCE CONTROL**

# Cerebral abscess, Guidance

- 4-6 weeks of therapy if the abscess has been excised or aspirated or 6-8 weeks, and possibly longer, if the patient has been treated conservatively.
- proposed that, based on a correlation between follow-up CT findings and clinical observations,
  - 3-4 weeks of parenteral therapy are adequate for patients whose abscesses have been excised
  - 4-6 weeks for those treated by aspiration, with a minimum of 4 weeks for those given antibiotics alone, assuming the absence of ring enhancing lesions on CT performed at the time of discharge.

*British Journal of Neurosurgery 2000; 14(6): 525±530 The rational use of antibiotics in the treatment of brain abscess REPORT BY THE 'INFECTION IN NEUROSURGERY' WORKING PARTY OF THE BRITISH SOCIETY FOR ANTIMICROBIAL CHEMOTHERAPY*

# Pyogenic brain abscess, a 15 year survey

Jannik Helweg-Larsen<sup>1\*</sup>, Arnar Astradsson<sup>2</sup>, Humeira Richhall<sup>2</sup>, Jesper Erdal<sup>3</sup>, Alex Laursen<sup>4</sup> and Jannick Brennum<sup>2</sup>

**Table 2 Laboratory findings**

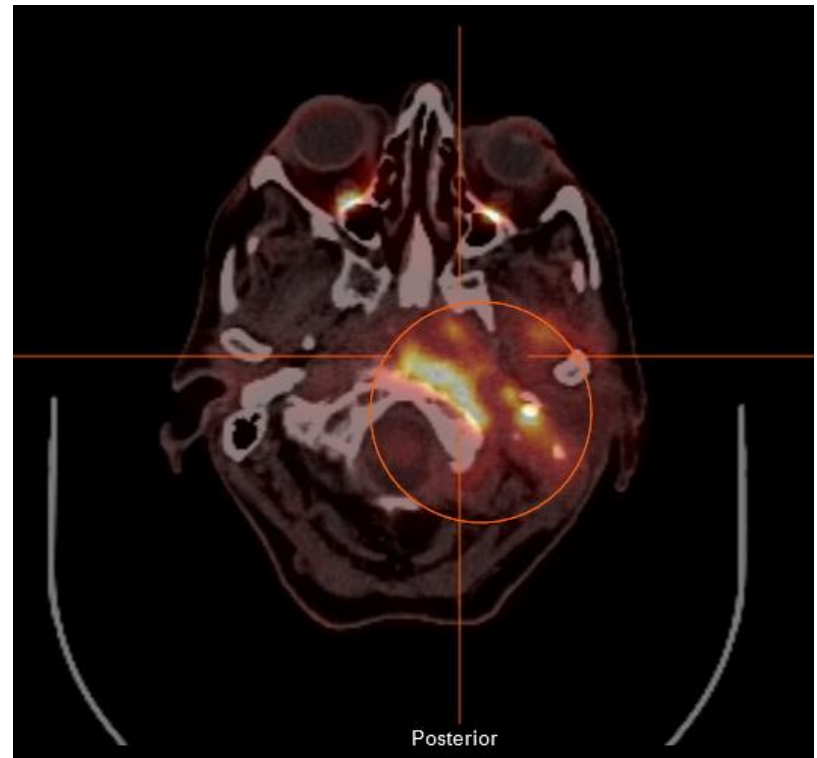
Laboratory findings	Number of patients (%)
CRP, mg/l	
0-20	28 (27%)
20-100	22 (22%)
>100	33 (32%)
Missing admission CRP	19 (19%)
Leukocytosis (>11.000 cells/ $\mu$ l)	49 (48%)
Missing leucocyte count	15 (15%)

**Table 5 Treatments**

Treatments	Range	
Median antibiotic treatment, overall	62 days	0-261 days
Median time of intravenous treatment	41 days	0-111 days
Median antibiotic time postsurgery	59 days	1-245 days
No. of patients receiving antibiotics before surgery	48 (54%)	
No. of patients receiving oral antibiotics after intravenous	36	
Duration of po treatment after iv, median	44 days, range 10-405	

# Malignant Otitis Externa

- Progressive cranial neuropathies
- Pseudomonas / Staph
- Prolonged therapy

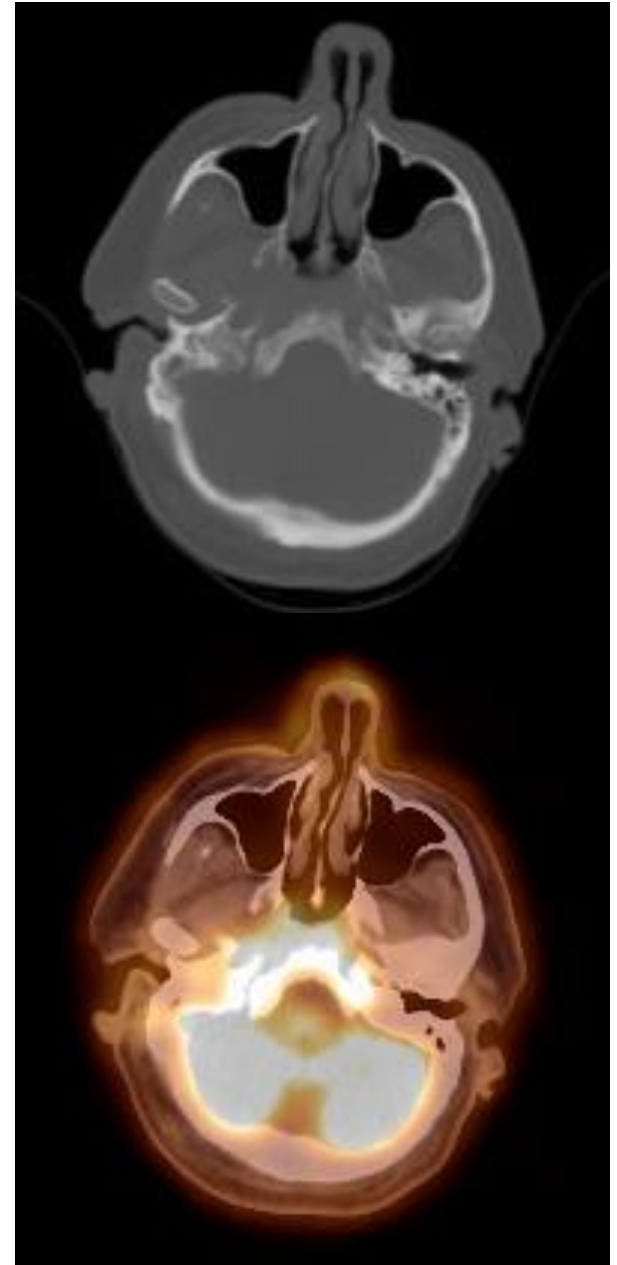


- 24 Episodes 20 Patients

MOE OPAT DAYS: 1714 since 2008

# Case E

- 64 year old
- T2DM, Ca larynx- radical neck dissection and RTx 2007
- Admitted August '14- 6/12  
“heavy feeling” in his head and  
diplopia + dizziness
- Right VI palsy
- Micro- R ear swab- scanty yeasts



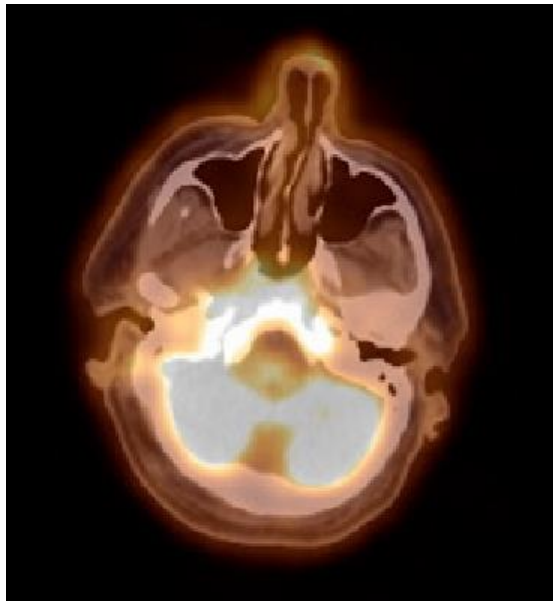


# Case E

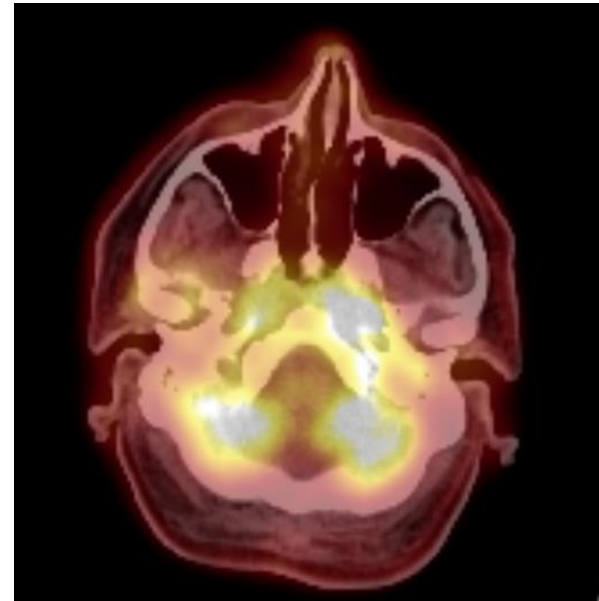
- Ceftazidime under OPAT
- Day 13- developing left VII palsy + some hearing loss left side
- Ophthalmology who noted papilloedema
- MR venogram- no Cavernous Venous Sinus Thrombosis but osteitis now involving contralateral side

# Case E

- Cranial neuropathies progressed
- CSF analysis - NAD
- Day 47- Bilat VI, dense L VII. Changed to Meropenem 2g TDS.
- Day 68- diplopia and dizziness improving



08/04/14



05/11/14

# Case E

- Completed 10/52 meropenem- changed to po ciprofloxacin + doxycycline
- Somnolent, more dizzy. Back to meropenem. Biopsy planned.
- Continued deterioration. Beta-D-glucan >500. Voriconazole commenced.
- 159- Much improved, normalised CRP, ESR, WCC.
- Voriconazole + ciprofloxacin

**REASSESS DIAGNOSIS**

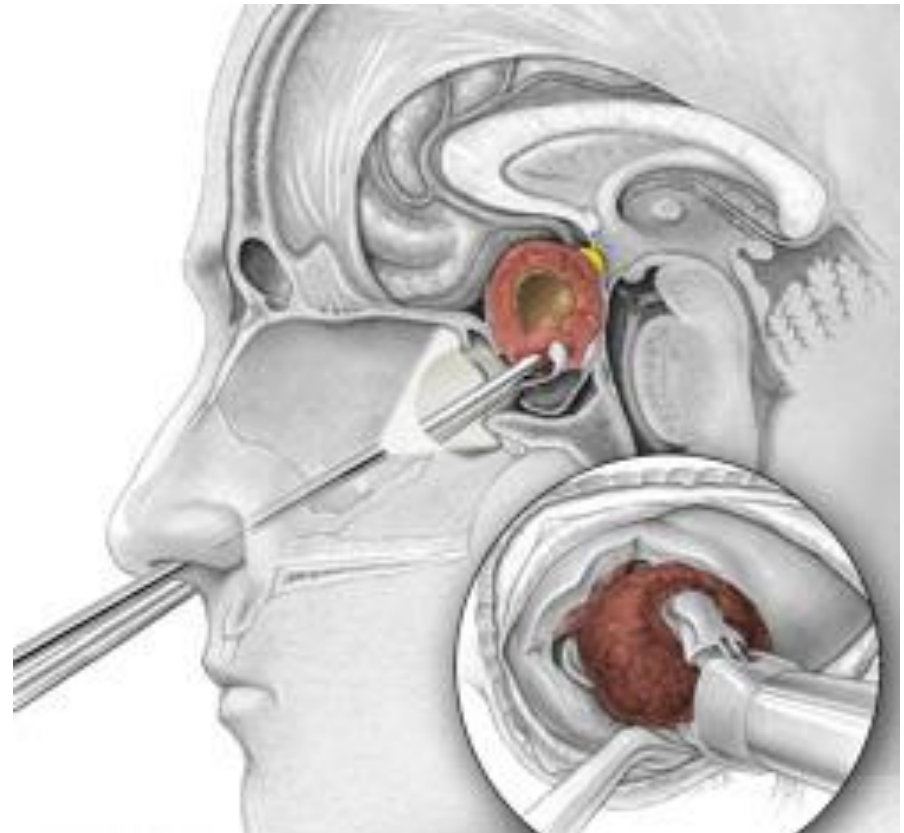
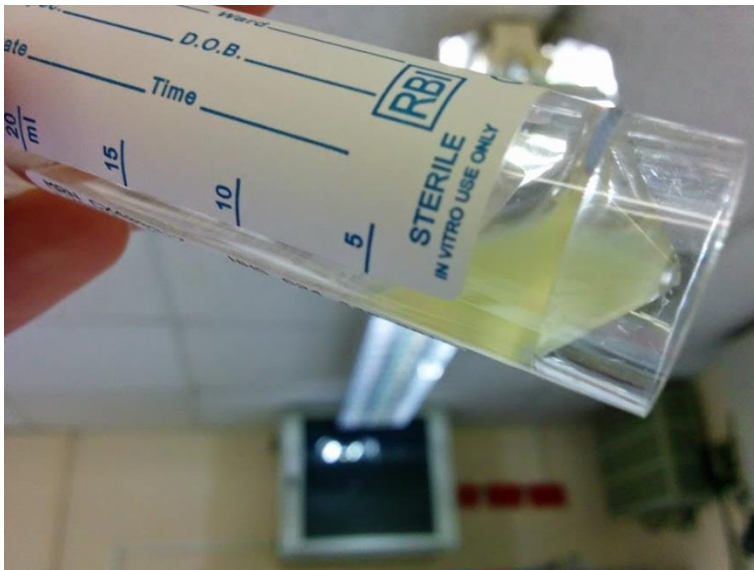# Iatrogenic CNS infections

- Craniotomy Bacterial meningitis is a serious complication of craniotomy; it occurs in 0.8 to 1.5% of patients who undergo craniotomy.
- Staph aureus meningitis
- Craniotomy infections
- Cranial plate infections

# Case F

- 24 yr old male
- Rathke's cleft cyst

Sensitive *Staph. aureus*

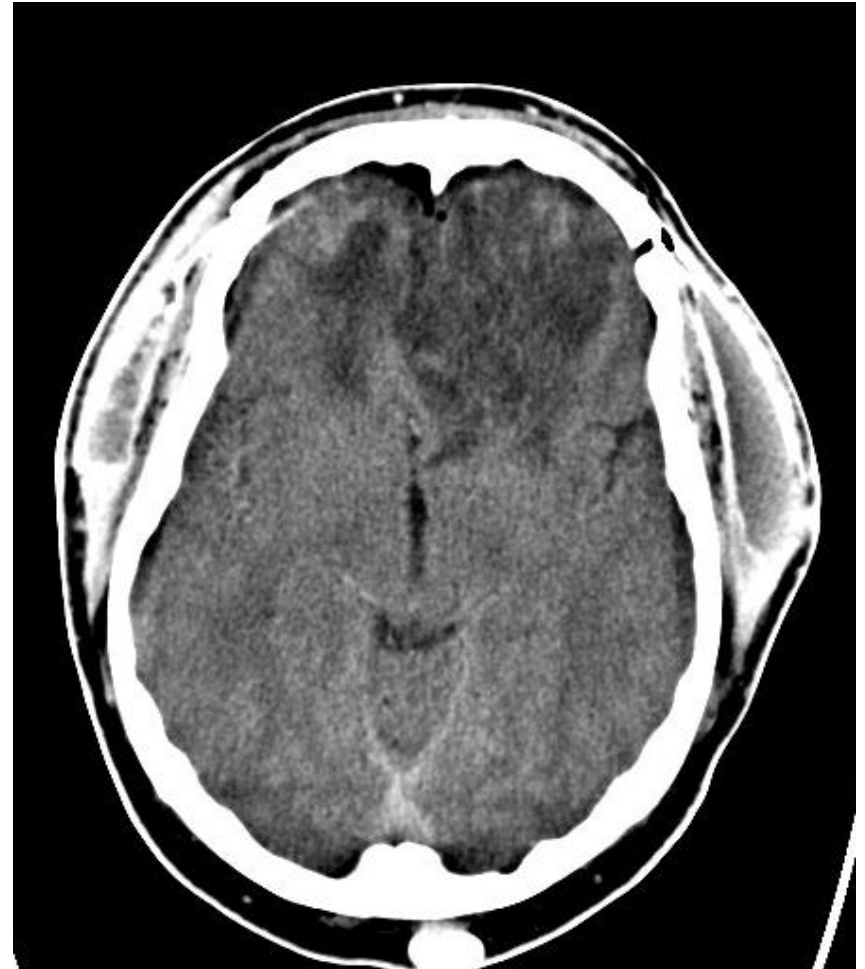
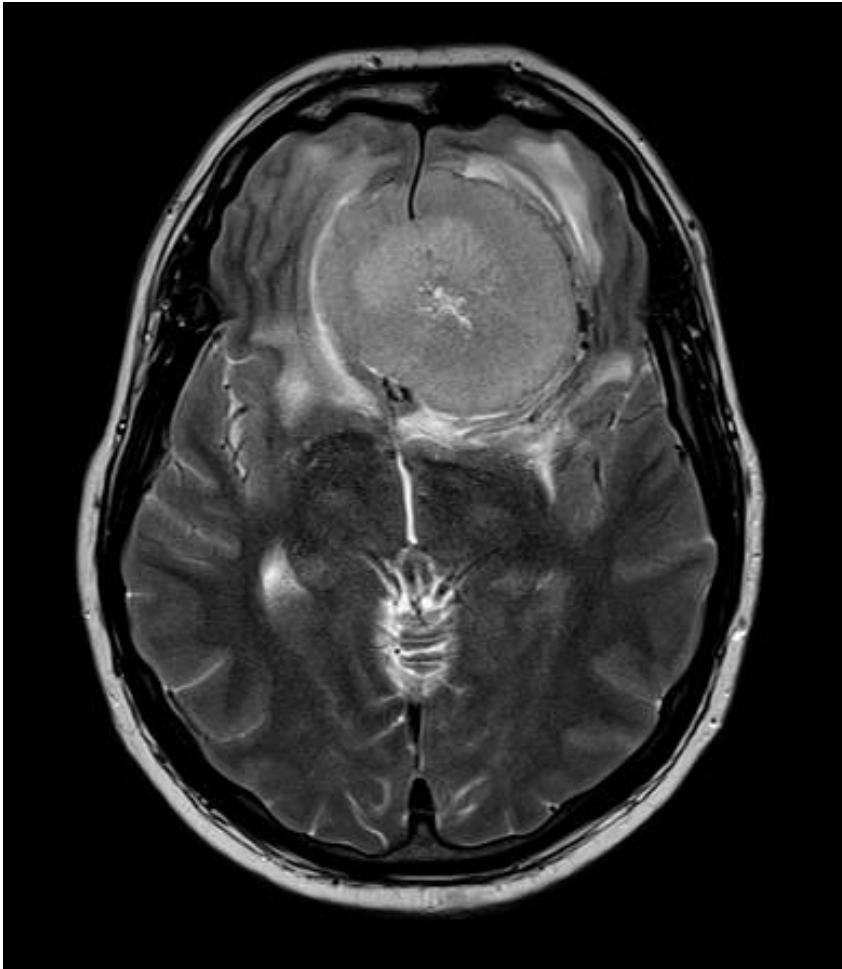
- Table 5. Recommendations for specific antimicrobial therapy in bacterial meningitis based on isolated pathogen and susceptibility testing

Microorganism	susceptibility Standard therapy	Alternative therapies
<i>Staphylococcus aureus</i>		
Methicillin susceptible	Nafcillin or oxacillin	Vancomycin, meropenem (B-III)
Methicillin resistant	Vancomycin	Trimethoprim- sulfamethoxazole, linezolid (B-III)

- Deep-seated MSSA CNS infection, following suprasellar cyst surgery (with right thigh fat pad closure).
- Antimicrobials:
- Initially Meropenem and Vancomycin
- Flucloxacillin 2g QDS IV S-OPAT 4 weeks
- Line related DVT - Tinzaparin 175mg/kg 14,000 units OD
- Ceftriaxone 2g bd 1 week
- Flucloxacillin 1g QDS PO 1 week.

# Case G





- Diagnosis: Cranial Wound Infection
- No microbiology
- Spectrum of pathogens :
  - Staphylococcus aureus
  - Coagulase-negative staphylococci (especially *S. epidermidis*)
  - Gram negatives
- Initially Meropenem and Vancomycin
- Switched to Ceftriaxone and Teicoplanin for OPAT.
- Readmitted after one week with headache and fever. Also leucopenia attributed to Teicoplanin.
- Craniotomy and washout, copious pus. No growth. 16s PCR negative.
- Retarted Ceftriaxone
- after a week as inpatient restarted OPAT – 4 weeks followed by 2 weeks oral Co-Amoxiclav.

## **SOURCE CONTROL**

# Case H

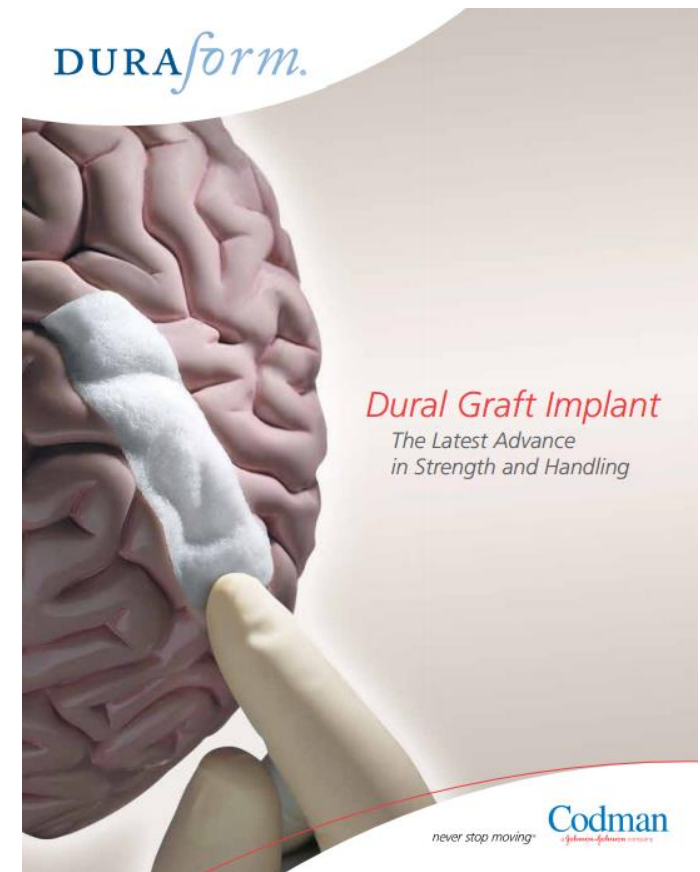
Chiari Malformation I and underwent Foramen Magnum Decompression.

Post op meningitis

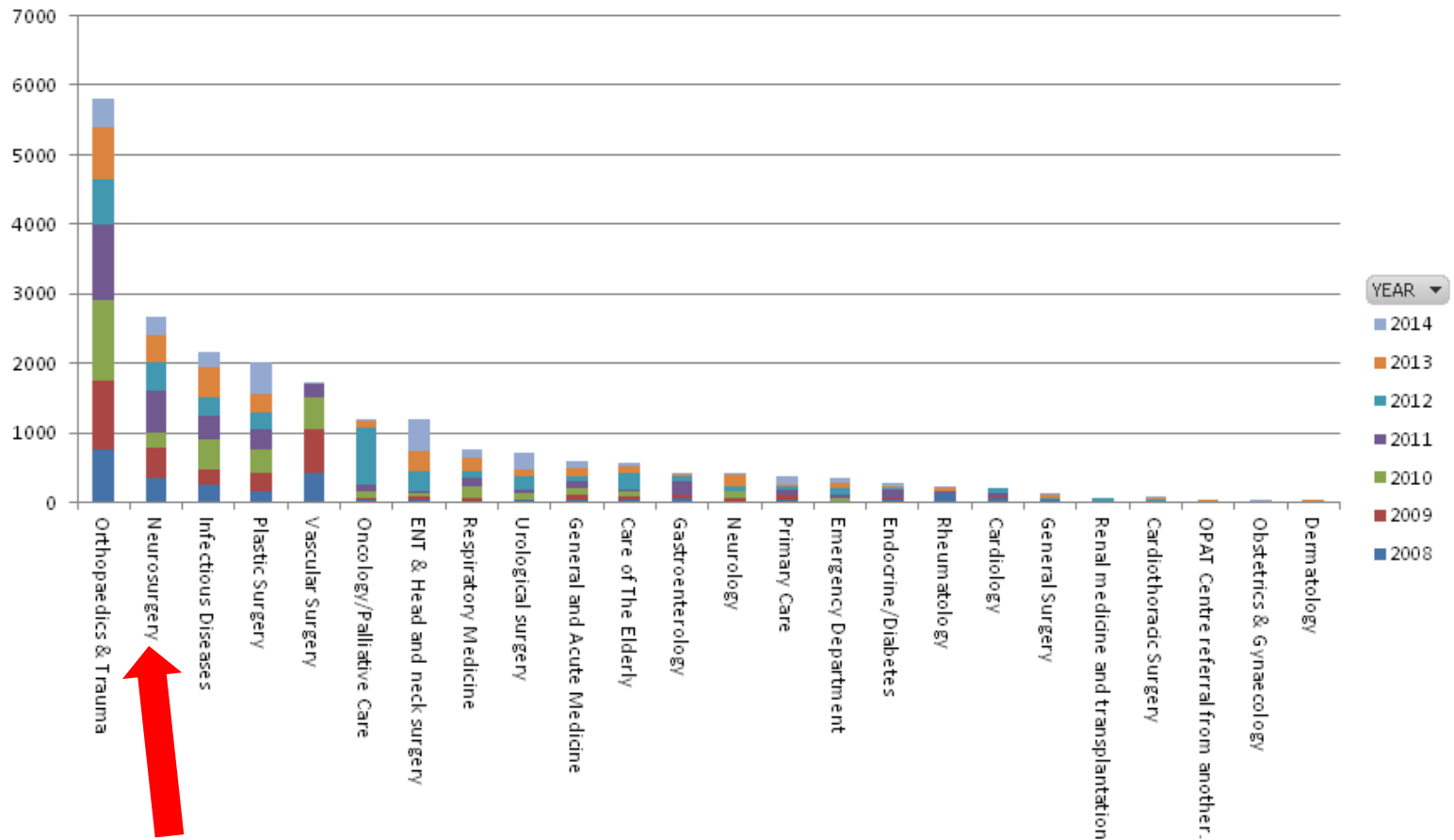
Clinical response to Ceftriaxone.

‘Prosthetic’ material

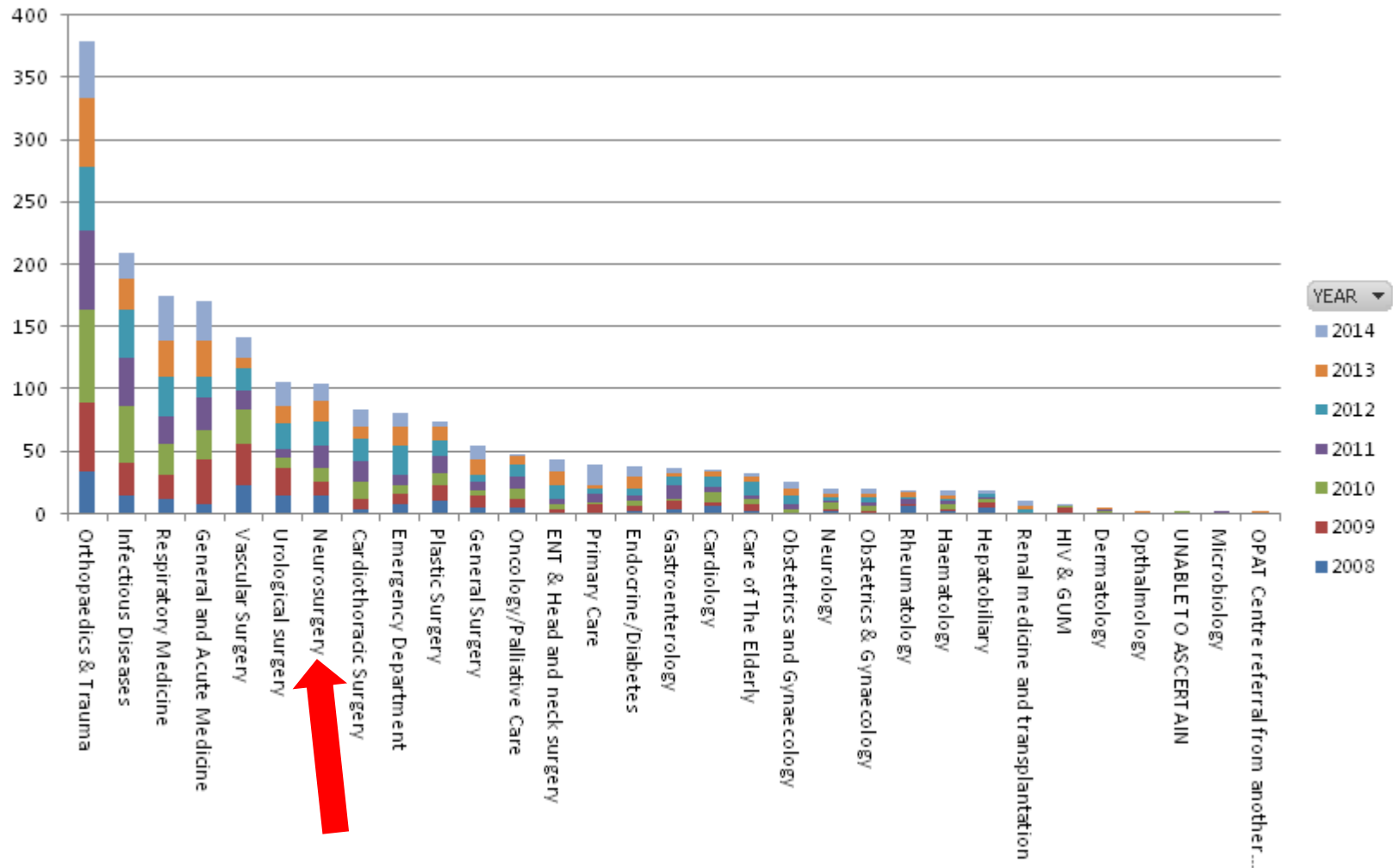
Addition of Rifampicin



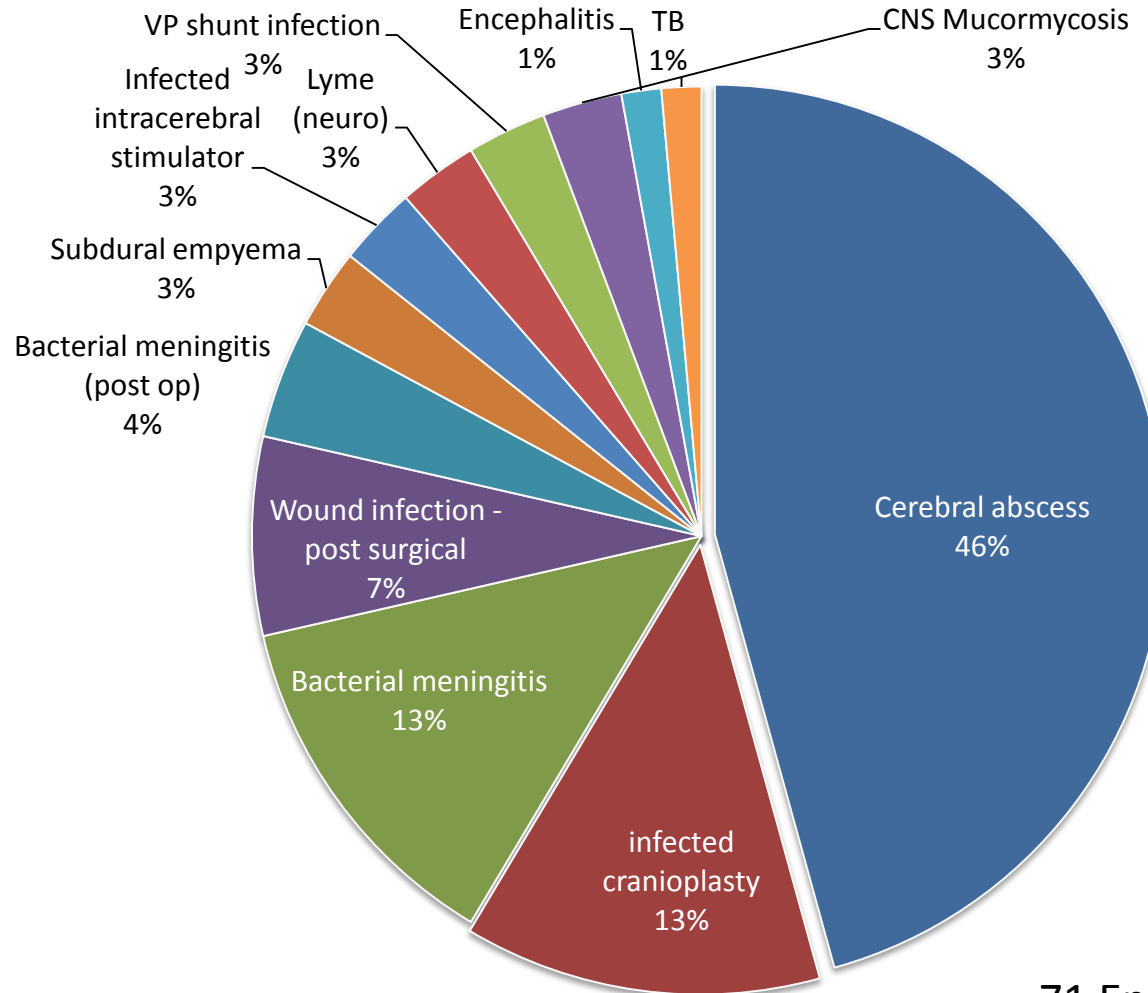
## 2008-2014: Referring Specialities by bed days saved Charing Cross Site



# 2008-2014 Patients referred by speciality All sites

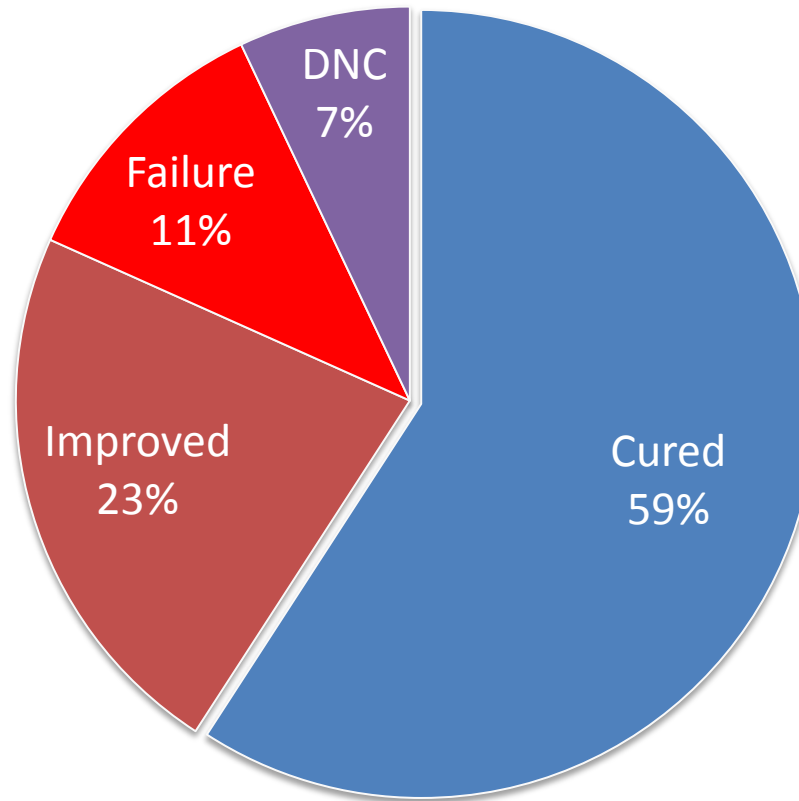


# Intracranial infections treated on OPAT at Imperial



71 Episodes 68 Patients  
OPAT DAYS: 1859 since 2008

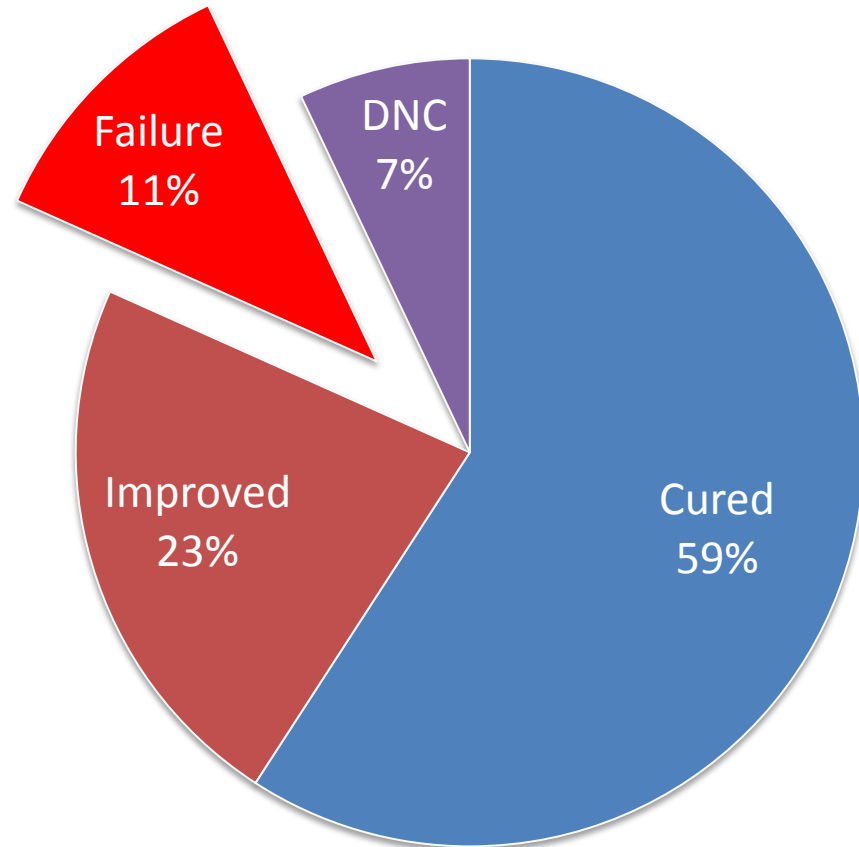
# Outcomes



71 Episodes 68 Patients  
OPAT DAYS: 1859 since 2008

# Failures

Surgical / source	38% (5)
Line	23% (3)
Adverse Drug Reaction	15% (2)
Early Oral switch	15% (2)
Neuro	7.5% (1)



71 Episodes 68 Patients  
OPAT DAYS: 1859 since 2008

## Factors to consider in evaluating a patient with a CNS infection for outpatient parenteral antimicrobial therapy (OPAT).

Factor	Requirements and considerations
Infection	Establish pathogen if possible; patient afebrile with clinically stable or improving condition
Antimicrobial	First dose given under medical supervision and without reaction; selection of antimicrobial and dosing to avoid seizure
Other disease(s)	Stable, improving, or not significant; need for nursing care
Vascular access	Reliable intravenous line and infusion device, if needed
Neurological state	Risk of seizures; need for medications; neurological dysfunction
Follow-up	Plan for physician visits, nurse visits, laboratory monitoring, and emergencies
Patient's abilities	Cooperative and willing to participate in OPAT; able to mentally and physically comply with OPAT program; no active drug or alcohol abuse
Family support	Able to assist in care, infusions, transportation, and emergencies; domestic problems
Home environment	Safe environment; telephone, utilities, food, refrigerator

Tice A D et al. Clin Infect Dis. 1999;29:1394-1399



# Key elements

- Interdisciplinary
- Safety
  - patient issues, seizures, altered neurological function
- Antimicrobial
  - Dosing, route, frequency, duration
- Review
  - Clinical, laboratory, radiological, surgical, neurology

# References

- British Journal of Neurosurgery 2000; 14(6): 525±530 The rational use of antibiotics in the treatment of brain abscess REPORT BY THE 'INFECTION IN NEUROSURGERY' WORKING PARTY OF THE BRITISH SOCIETY FOR ANTIMICROBIAL CHEMOTHERAPY
- Eur J Clin Microbiol Infect Dis. 2007 Jan;26(1):1-11. Retrospective analysis of 49 cases of brain abscess and review of the literature. Carpenter J, Stapleton S, Holliman R.
- British Journal of Clinical Pharmacology. 2011;72(3):381-393. Grill MF, Maganti RK. Neurotoxic effects associated with antibiotic use: management considerations.
- BMC Infectious Diseases 2012, **12**:332. Pyogenic brain abscess, a 15 year survey. Jannik Helweg-Larsen, Arnar Astradsson, Humeira Richhall, Jesper Erdal, Alex Laursen and Jannick Brennum.
- N Engl J Med 2010;362:146-54. Nosocomial Bacterial Meningitis. Diederik van de Beek, M.D., Ph.D., James M. Drake, M.B., B.Ch., and Allan R. Tunkel, M.D., Ph.D.
- Clin Infect Dis. (2004) 39 (9):1267-1284. Practice Guidelines for the Management of Bacterial Meningitis. Allan R. Tunkel, Barry J. Hartman, Sheldon L. Kaplan, Bruce A. Kaufman, Karen L. Roos, W. Michael Scheld, and Richard J. Whitley.