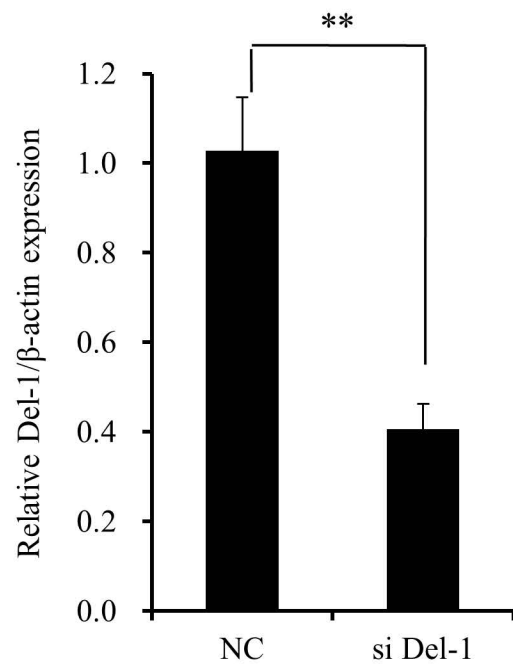

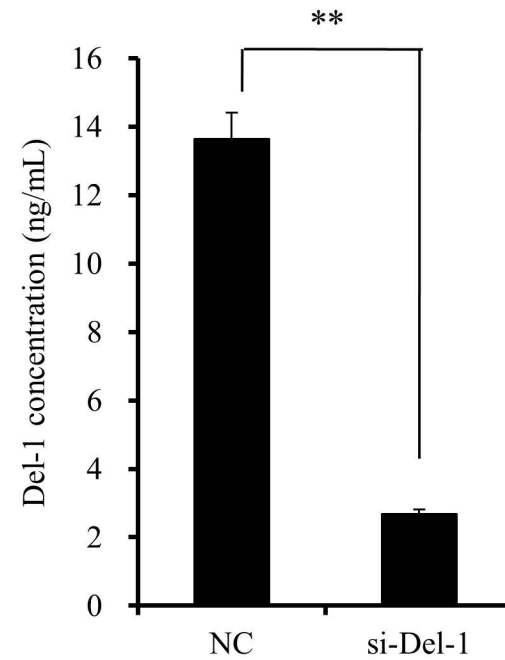


**Supplementary Table 1.** Clinical history and characteristics of tamoxifen-resistant primary breast cancer in two patients who received only endocrine treatment with tamoxifen

Case no.	Period of tamoxifen medication	Clinical history	Initial tumor type	Final tumor type after progression during tamoxifen treatment	Immunohistochemistry
F/65	39 months	The patient was diagnosed with bilateral breast cancer. The cancer on both sides was ductal carcinoma <i>in situ</i> and showed hormone receptor positivity. Because the patient refused surgery, hormone treatment with tamoxifen was initiated in October 2013. Both breast tumors shrank during the course of treatment. However, in January 2017, the cancer in the left breast increased from 2.8 to 3.8 cm, as determined by ultrasound. The patient underwent surgery on both breasts with sentinel lymph node biopsies.	Ductal carcinoma <i>in situ</i>	Invasive ductal carcinoma (left)	ER+/PR+/HER2-
F/77	65 months	A patient visited our hospital due to a 0.8-cm microlobulated mass on her right breast. The mass was diagnosed as ductal carcinoma <i>in situ</i> and showed hormone receptor positivity. Due to her severe comorbidities, she and her family refused surgery. Hormone treatment with tamoxifen was initiated in May 2012. After 65 months, the breast cancer had increased from 0.8 to 1.4 cm, as determined by ultrasound. The patient underwent conservative breast surgery under local anesthesia without sentinel lymph nodes biopsy.	Ductal carcinoma <i>in situ</i>	Invasive ductal carcinoma	ER+/PR+/HER2-

**A****B****C**

Supplementary Figure 1. Del-1 knockdown reduces Del-1 mRNA and protein levels in TAM-R cells. (A, B) The efficacy of Del-1 mRNA and protein knockdown was evaluated by RT-PCR (A) and western blotting (B), respectively. (C) Effect of Del-1 knockdown in TAM-R MCF-7 cells on secretion of Del-1 protein was evaluated by ELISA (\* $p < 0.05$ , \*\* $p < 0.01$ ).