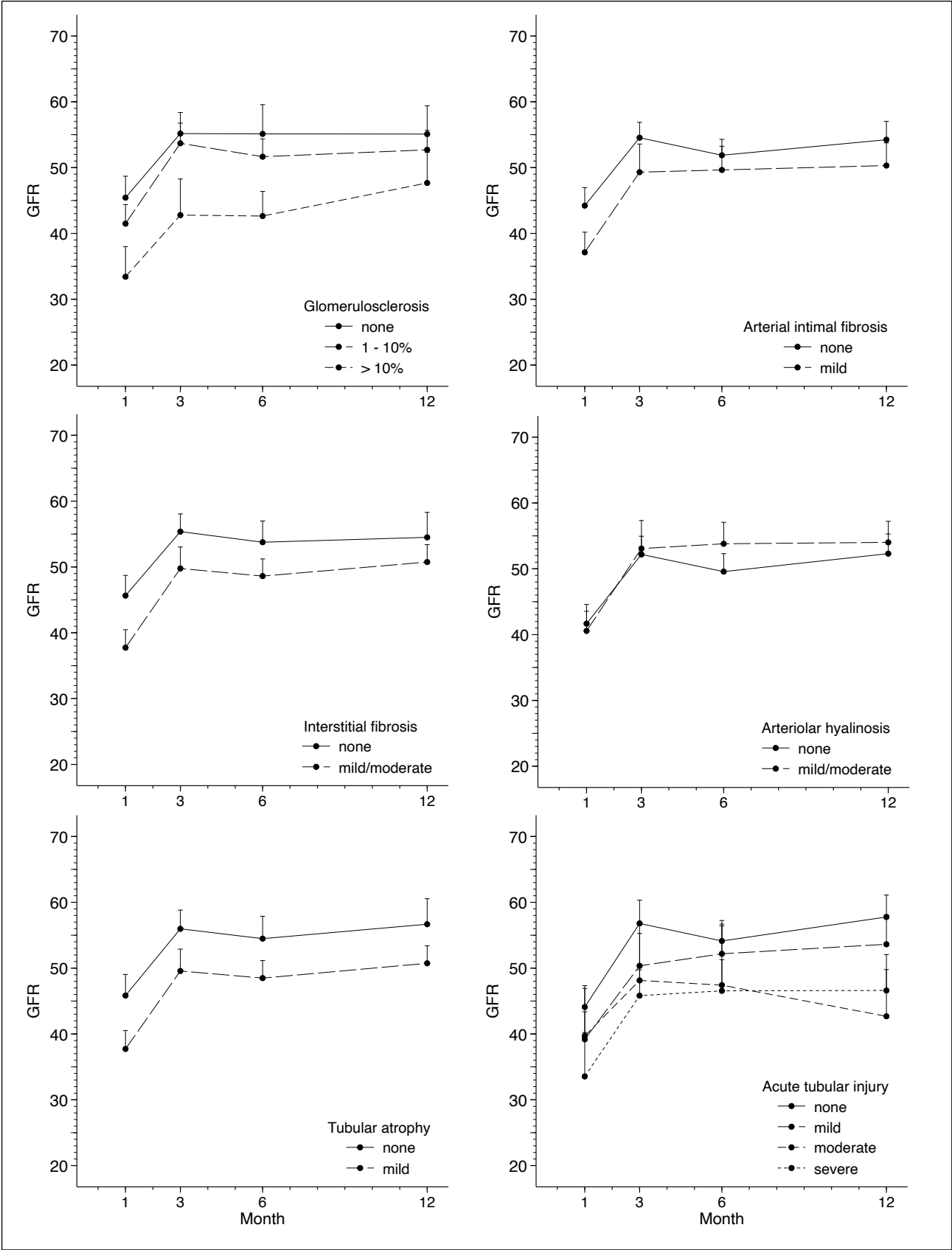


Supplementary Figure 1. Procurement biopsy characteristics mean and standard error.



Note: One case of moderate interstitial fibrosis and one case of moderate arteriolar hyalinosis was merged in a mild/moderate category.