

An Effective Way to Solve Equivocal Mammography Findings: The Rolled Views

Alimoglu, E.; Ceken, K.; Kabaalioglu, A. (Antalya); Cassano, E. (Milan); Sindel, T. (Antalya)

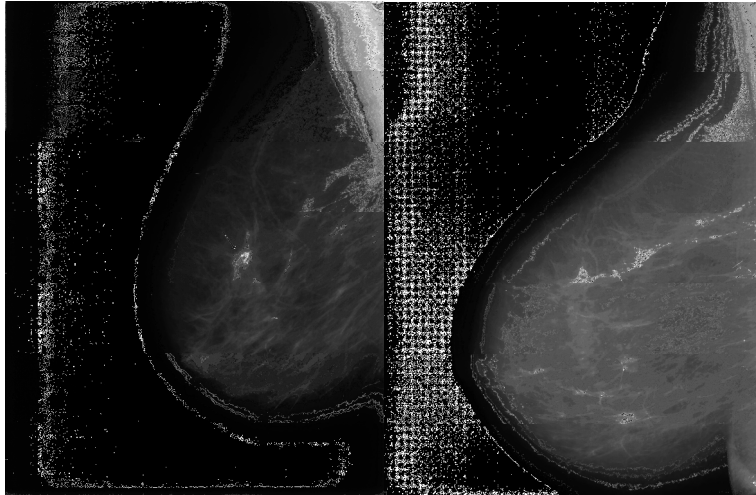


Fig. 2. **a** In the MLO view of right breast, focal asymmetry is seen in a 49-year-old woman (arrow). **b** In RMLRS+, the outer part is rolled from superiorly, and the equivocal finding disappeared completely on rolled view. This lesion was accepted as a summation artifact, and annual screenings were recommended for this patient assessed as BI-RADS 2 after rolled view.

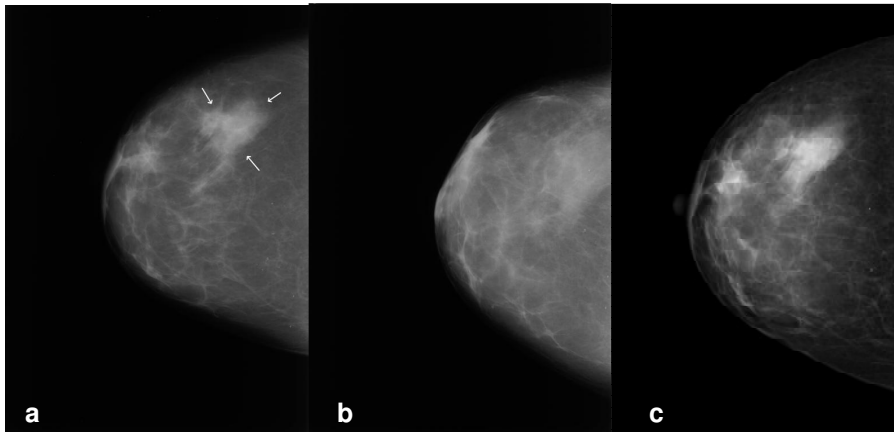


Fig. 5. Right CC rolled view in a 44-year-old woman. **a** Focal asymmetry seen on right CC view taken in 2002. **b** RCCRL+ view (right CC rolled from medial to lateral) revealed summation artifact. The patient was diagnosed as BI-RADS 2. **c** Focal asymmetry unchanged by 2005 and thereafter.