
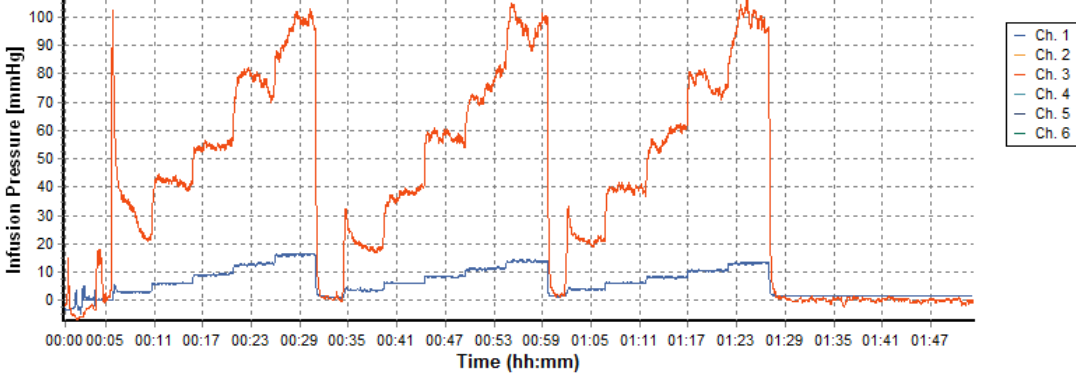


SFN345270 Supplementary Material


Supplement 1



Supplement 2



Supplement 3



Supplement 1. Picture of infusion gels and apparatus. (left) advancement method, (right) retraction method. The VT catheter appears on the left and the SF catheter appears on the right of each picture.

Supplement 2. Pressure monitoring traces during ramped infusions. Higher pressures were associated with the SF catheter due to a smaller inner diameter of 0.20 mm versus the VT catheter with a 0.25 mm inner diameter at the tip and larger inner diameter to accept the silica stylet.

Supplement 3. Left to right: A: deep infusion, B: shallow infusion only after retraction and lastly C: deep infusion followed by shallow infusion.