

Table 1. Characteristics of the 9 studies included in the meta-analysis regarding the association between VEGF-C expression and tumor staging

Study (first author)	Country	Year of publication	Number of patient	Age(year)	Source for VEGF-C analysis	VEGF-C analysis method	Antibody used/ RNA extraction	Criteria for VEGF-C expression positive	VEGF-C expression positive (%)	Staging	Matching	Newcastle Ottawa quality score	long term survival (%)
Wang X.	China	2007	174	56.7(38-78)	Surgical specimen	Immunohistochemistry	Anti-human VEGF-C antibody (1:100;Zhongshan biotech,China)	Staining >10% of tumor cell	42.5%	I-III	a,b,c,d,e,f,g,i,j	7	18.9% in VEGF-C positive, 45% in VEGF-C negative
Matsumoto M.	Japan	2006	87	65.7(39-81)	Surgical specimen	Immunohistochemistry	Anti VEGF-C monoclonal antibody (1:100;Santa Cruz Biotechnology ,USA)	Staining >30% of tumor cell	50.6%	I-III	a,b,c,e,f,g,h	7	-
Byeon JS.	South Korea	2004	34	63(45-84)	13 from ESD specimen, 21 from surgical specimens	Immunohistochemistry	VEGF-C monoclonal antibody (1:400;Santa Cruz Biotechnology ,USA)	Staining >25% of tumor cell	76.5%	0-III	a,b,c,d,e,f,g,h	6	-
Han U.	Turkey	2007	40	-	Surgical specimen	Immunohistochemistry	Indirect immunoperoxidase method(Clone : PAD-Z-CVC7,Zymed, sitrat retrieval)	Staining >10% of tumor cell	80%	I-III	b,c,d,f	7	-
Lui P.	China	2009	73	61(33-78)	Surgical specimen	Immunohistochemistry	VEGF-C monoclonal antibody (1:50;Santa Cruz Biotechnology ,USA)	Staining >30% of tumor cell	53.4%	0-IV	a,b,c,d,e,f,g,h,i,j	8	15.4% in VEGF-C positive, 20.6% in VEGF-C negative
Matsumoto S.	Japan	2007	53	-	Surgical specimen	Immunohistochemistry	VEGF-C antibody (Dako Cytomatin Inc,USA)	Staining >30% of tumor cell	71.7%	0-IV	b,c,d,e,f,g,h	7	-
Sun ZG.	China	2012	92	45-72	Surgical specimen	mRNA	Trizol (Invitrogen,Ca risbad,USA)	Detection by Polymerase chainreaction	60.9%	I-III	a,b,c,d,e,f,g,h,i,j	7	14% in VEGF-C positive, 18% in VEGF-C negative
Kitadai Y.	Japan	2001	60	-	12 biopsy specimen 48 surgical specimen	Immunohistochemistry	VEGF-C polyclonal antibody (1:100;Santa Cruz Biotechnology ,USA)	Staining >30% of tumor cell	56.3%	I-IV	c,d,e,f,g,h	6	-
Ding MX.	China	2006	43	62.5(47-78)	Surgical specimen	mRNA	VEGF-C oligonuclei probe (Beijing Dinguo Co.Ltd,China)	Diffuse or focal stain on tumor cell	41.9%	I-IV	a,b,c,e,d,e,f	7	-

Abbreviation : ESD = endoscopic submucosal dissection , mRNA = messenger ribonucleic acid , a=age,b=sex,c= tumor differentiation,d=TNM staging,e=depth of tumor invasion,f= lymph node metastasis,g= lymphatic invasion,h= vascular invasion,i=tumor size,j= 5 years survival

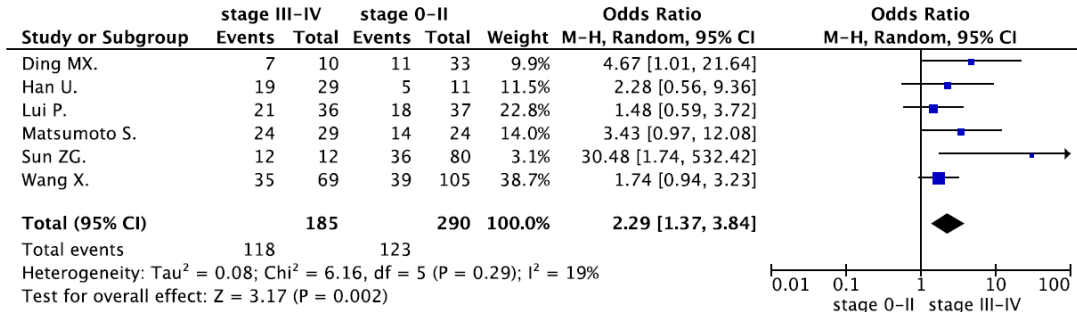


Fig. 2. Forest plots of the association between VEGF-C expression and tumor staging.

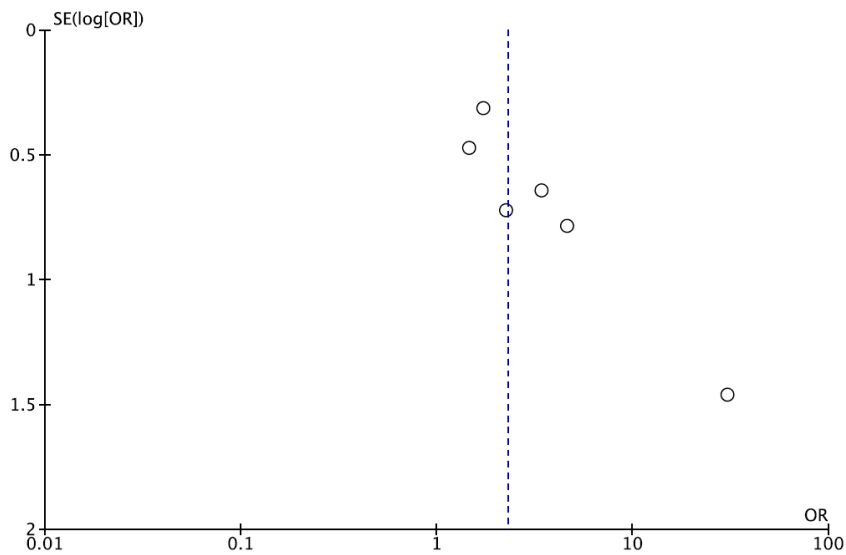


Fig. 3. Funnel plot of the association between VEGF-C expression and tumor staging.

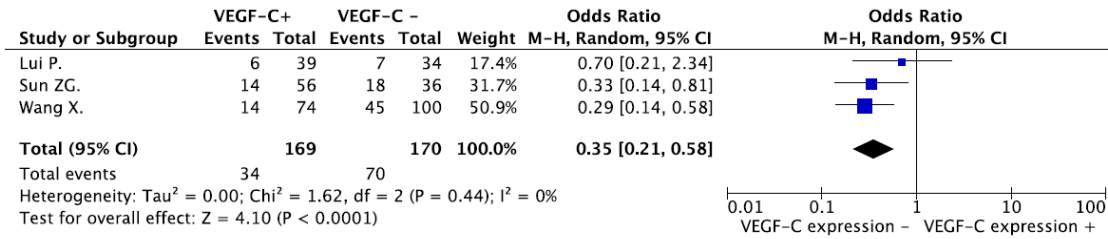


Fig. 4. Forest plots of the association between VEGF-C expression and 5-years survival.