

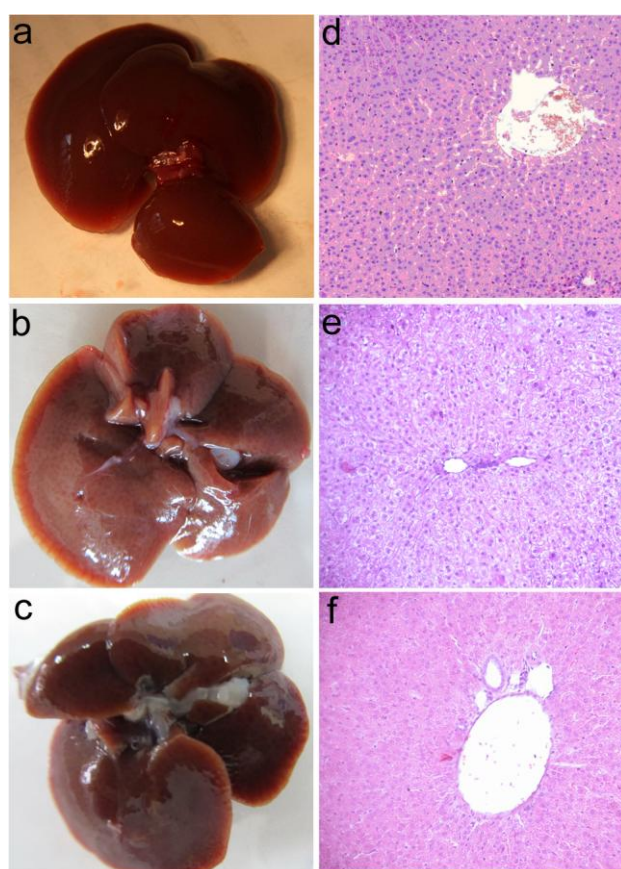
Supplementary material

Hemozoin “knobs” in *Opisthorchis felineus* infected liver

Alexandra G. Pershina#, Irina V. Saltykova, Vladimir V. Ivanov, Ekaterina A. Perina, Alexander M. Demin, Oleg B. Shevelev, Irina I. Buzueva, Anton K. Gutakovskii, Sergey V. Vtorushin, Ilya N. Ganebnykh, Victor P. Krasnov, Alexey E. Sazonov, Ludmila M. Ogorodova

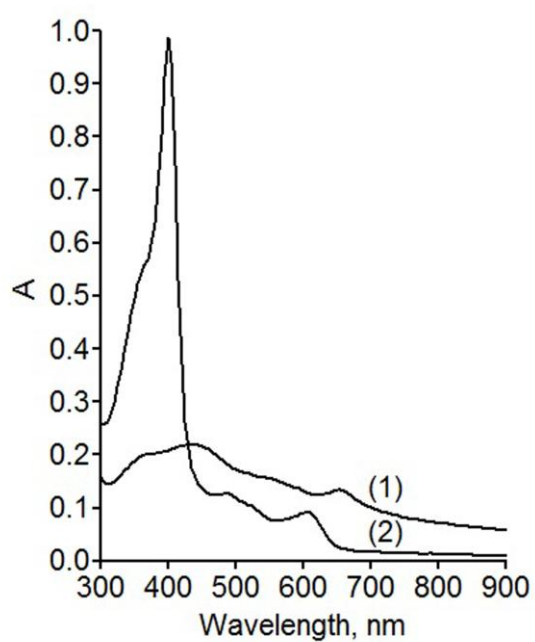
#Address correspondence to A.G. Pershina, allysyz@mail.ru

Pershina AG *et al.*

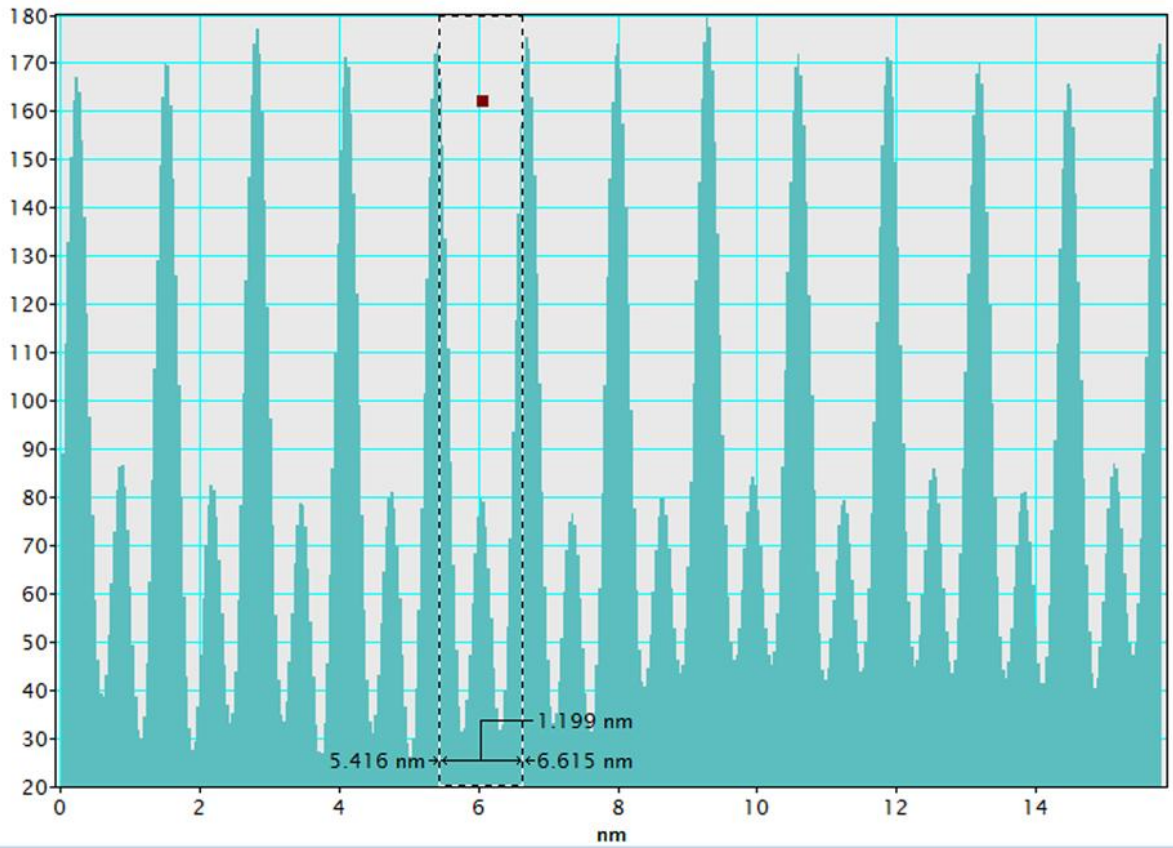


Supplementary Figure 1. Histological analysis of the liver of uninfected hamster (control).

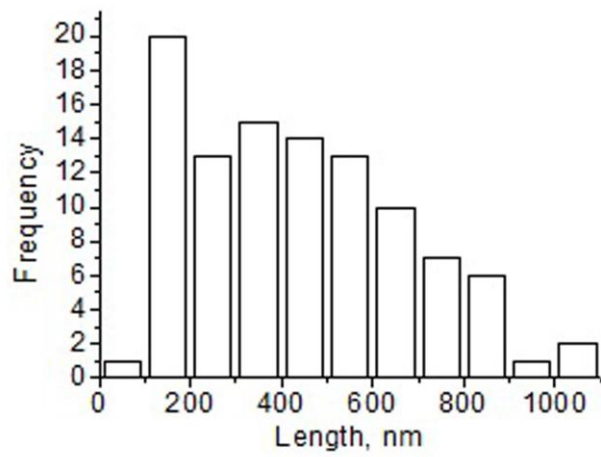
Macrophotograph of the liver of uninfected hamster (control) at (a) 5, (b) 24 and (c) 48 weeks after the start of the experiment. Histological analysis of the liver of uninfected hamster (control) at (d) 5, (e) 24 and (f) 48 weeks after the start of the experiment, hematoxylin and eosin staining ($\times 200$).



Supplementary Figure 2. UV-visible spectra of hemozoin (in water) extracted from *Opisthorchis felineus* (1) and the same amount of hemozoin dissolved in NaOH, SDS, EDTA buffer.



Supplementary Figure 3. The intensity profile of the designated area in Figure 2e in article.



Supplementary Figure 4. The histogram of hemozoin crystals length in *Opisthorchis felineus* gut.