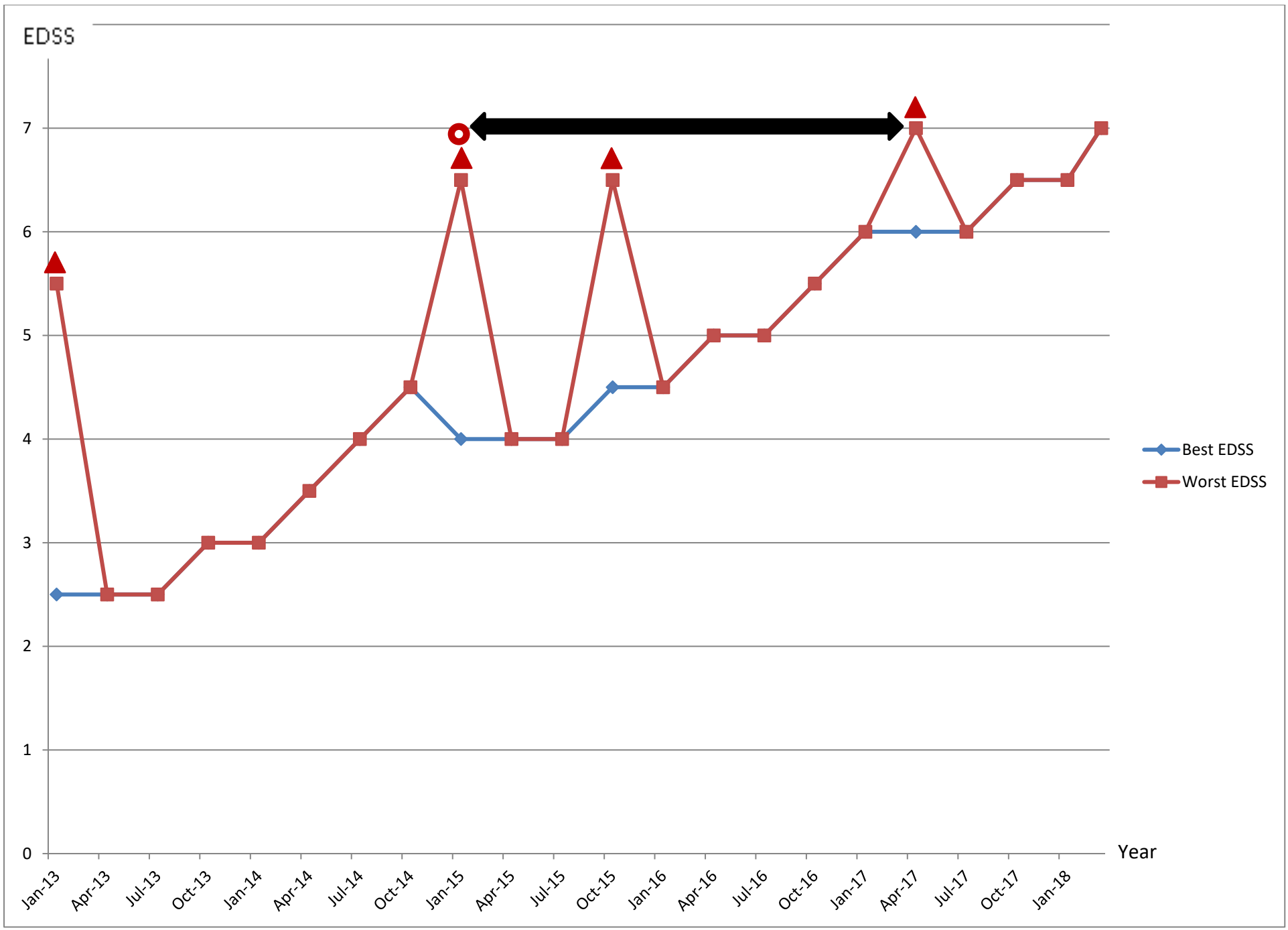



Best EDSS = best recorded EDSS for the particular quarter

Worst EDSS = worst recorded EDSS for the particular quarter

 Attack / relapse with each red triangle represents one attack

 Presence of new or enlarging MRI T2 / enhancing lesion(s)

 On DMT i.e. interferon (IFN)

**Supplemental Figure 3** showing the trend of EDSS, relapses, presence of new MRI lesions and DMT duration of Patient 3 throughout the longitudinal follow-up. Best EDSS = worst EDSS for most of the time throughout her progressive course when there was no attack. DMT (interferon) was started after the attack in December 2014. However, she was not compliant to the interferon, hence resulted in the relapse in year 2015 on top of the progressively worsening EDSS. Interferon was eventually stopped in March 2017 due to injection-related side effects and financial constraint. She relapsed again after stopping the interferon. However she was not keen to restart interferon. No other DMT was initiated due to financial constraint. Patient 3 seemed to demonstrate a progressive disease course throughout her longitudinal follow-up with progressively worsening EDSS and intermittent attacks/relapses. As she was not compliant to her interferon due to injection-related side effects, response to DMT could not be assessed adequately in her.