

Veterinary Pathology: Supplemental Materials.  
De Biase and Paciello. Response to Letter to the Editor on  
“*Coxiella burnetii* in Infertile Dairy Cattle With Chronic Endometritis”.

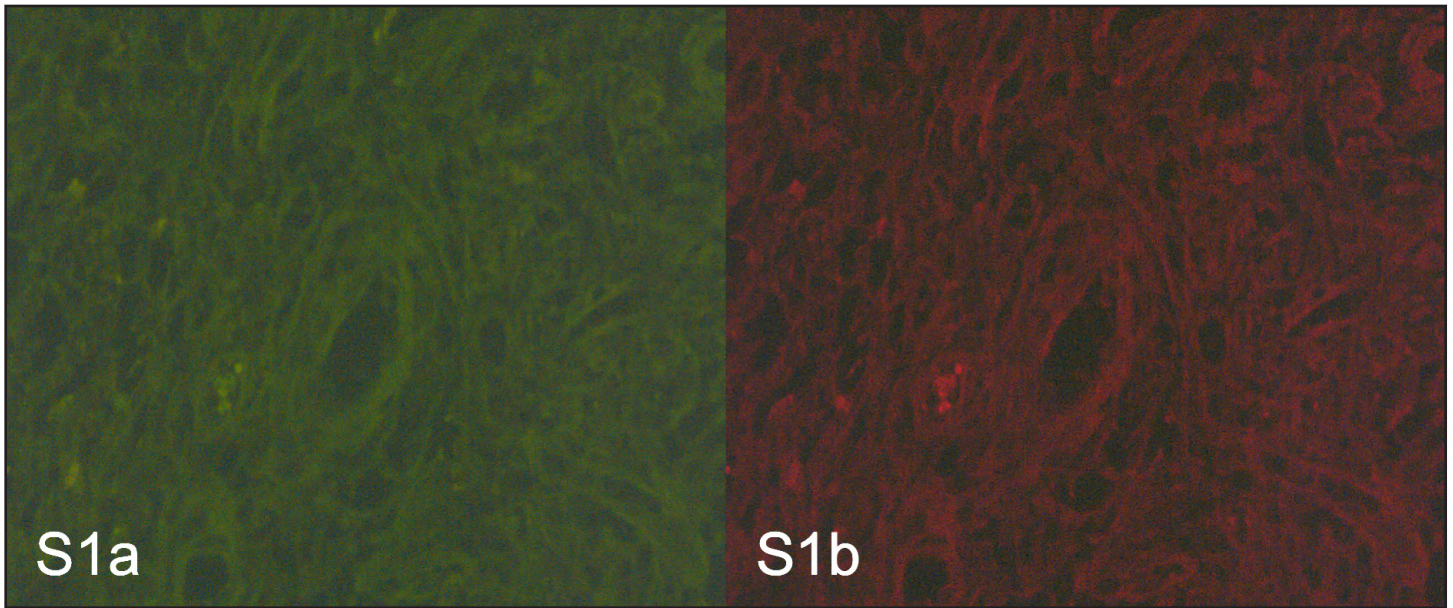


Figure S1. Double labeling immunofluorescence in endometrial biopsy, endometrium, cow. (a) Green FITC immunofluorescence of a control section incubated with PBS only and (b) Red TRITC immunofluorescence of a control section incubated with PBS only. Sections didn't show immunoreactivity or autofluorescence.