

Supplementary information:

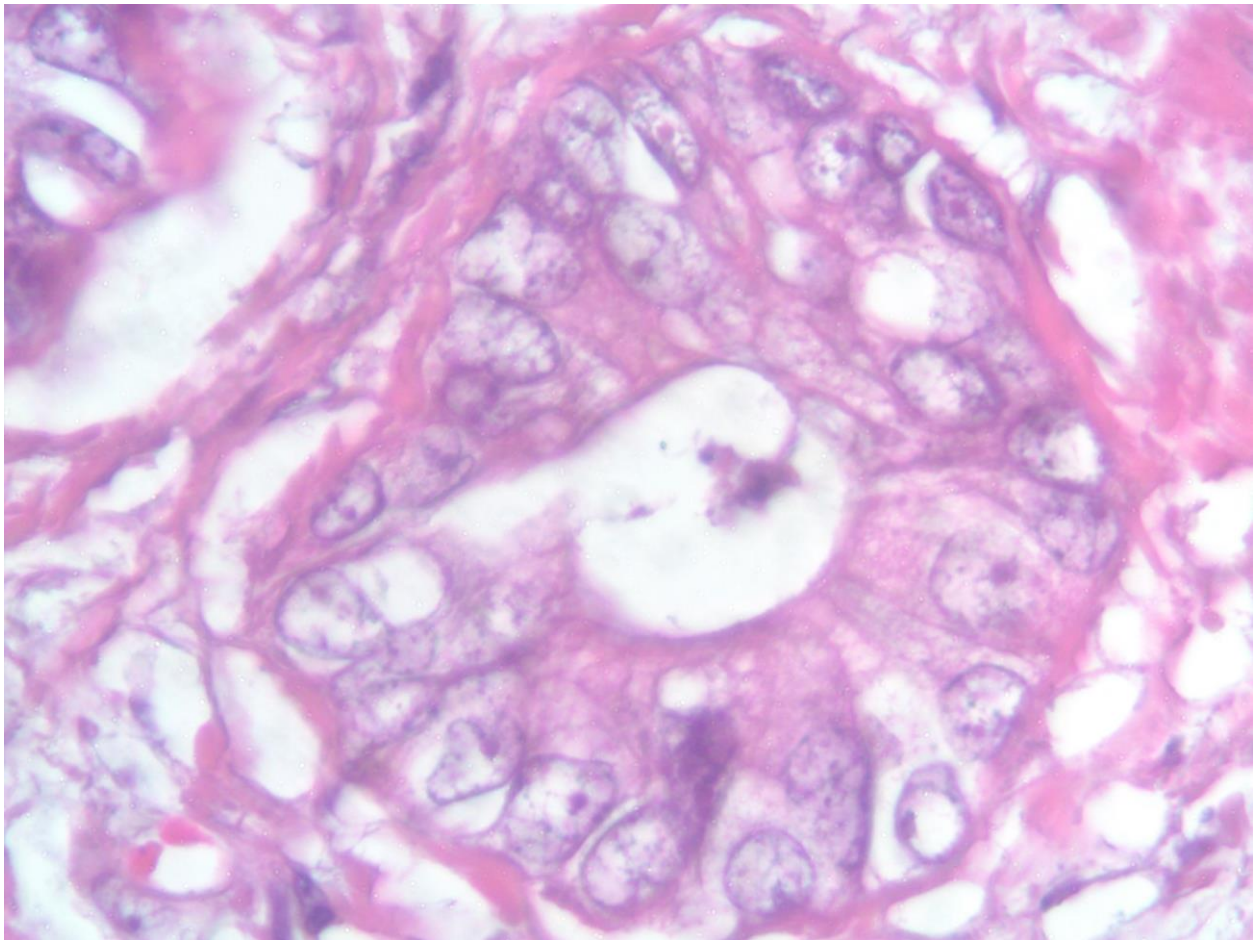


Figure 1: High Power field showing urethra diverticular adenocarcinoma comprised of cells with prominent nucleoli

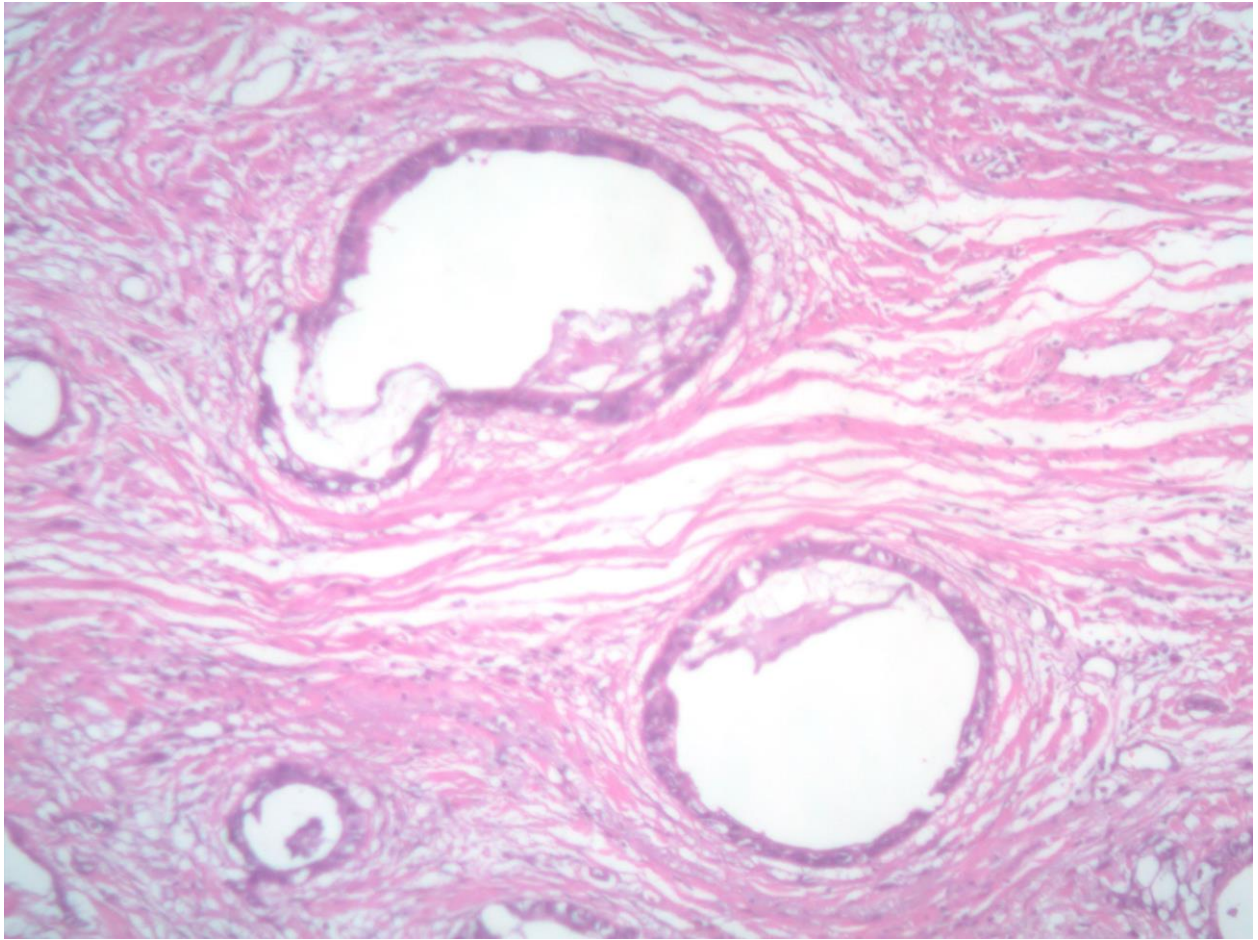


Figure 2: Image showing closer view of mucin in Lumen

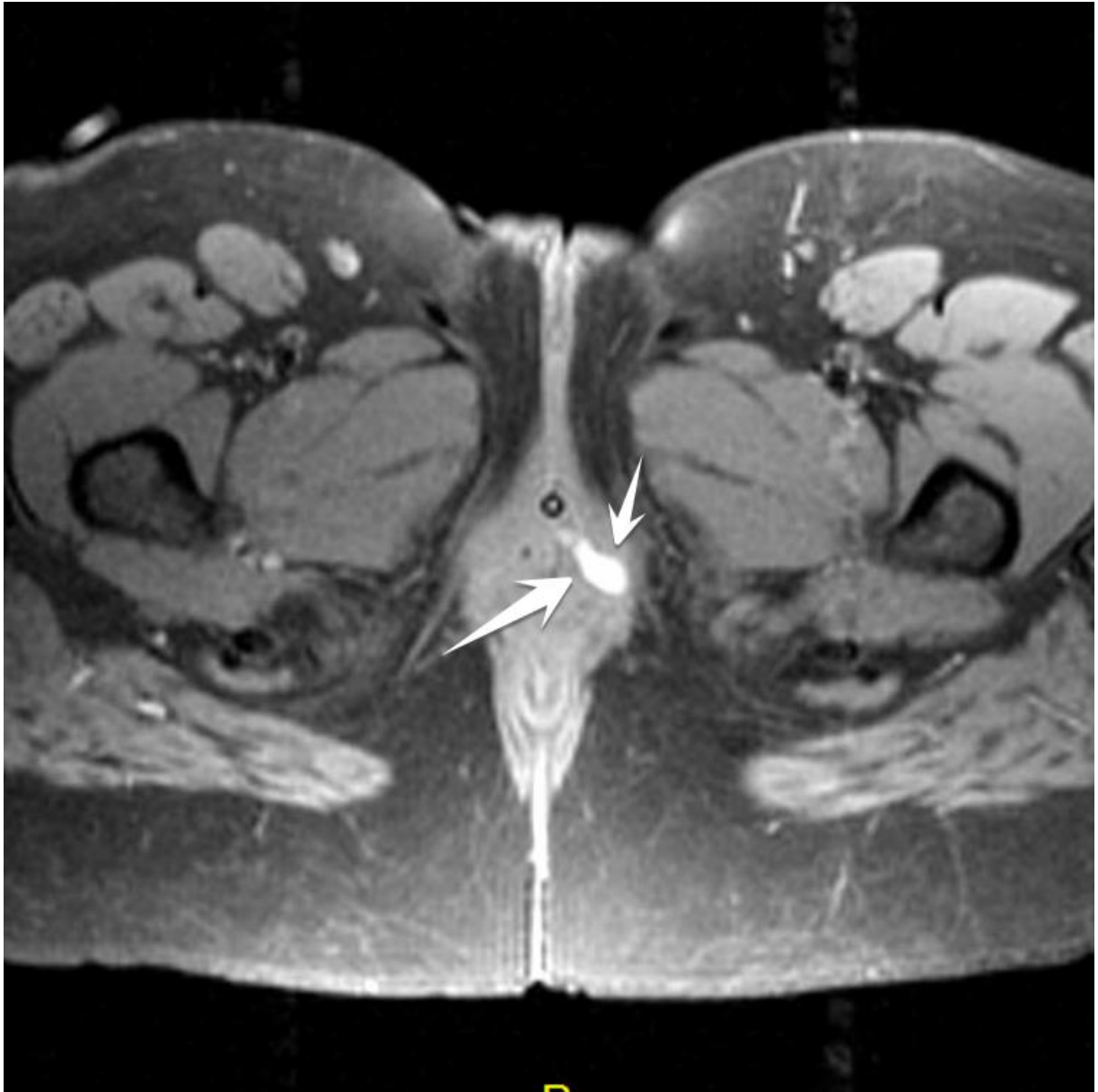


Figure 3: (Transverse View) MRI pelvis with contrast showing peri-urethral diverticula (White arrows)

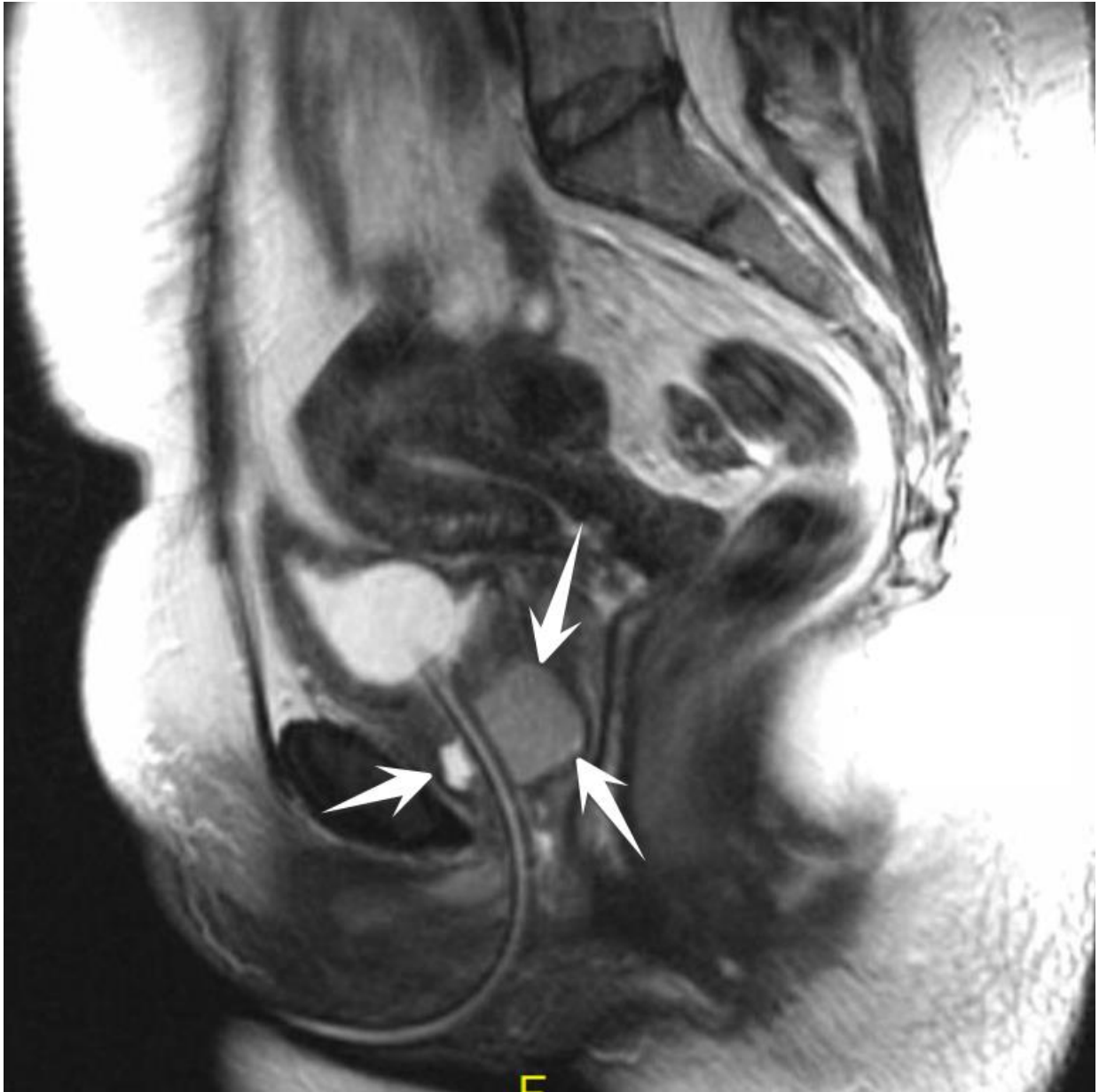

Figure 4: (Sagittal view) MRI pelvis with contrast showing peri-urethral diverticula (White arrows)

Genomic Findings	FDA-Approved	FDA-Approved	Potential Clinical
Detected	Therapies (in patient's tumor type)	Therapies (in another tumor type)	Trials

CDKN2A/B (Loss)	None	None	None
Microsatellite status: MS-Stable	None	None	None
Tumor Mutation Burden: TMB-Low; 5Muts/Mb	None	None	None

Table 1: Next Generation Sequencing Results; Note the CDKN loss which indicates the tumor is unlikely to be treated with Palbociclib. Ipilimumab and Nivolumab combinations have shown benefits in cases with high tumor mutation burden (TMB) however in this case the TMB is low.