

Supplementary Tables and Figures

Supplementary Table 1. Risk of Bias and Applicability Concerns for the 23 papers with meta-analysable data based on the Quality Assessment of Diagnostic Accuracy Studies 2 (QUADAS-2) criteria (<https://www.ncbi.nlm.nih.gov/pubmed/22007046>). Low risk: - High Risk: + Unclear: ?.

Study	Risk of Bias				Applicability Concerns		
	Patient Selection	Index Test	Reference Standard	Flow timing	Patient Selection	Index Test	Reference Standard
1 (Arba et. al. 2016) ¹	-	-	-	-	-	-	-
2 (Bae et. al., 2016) ²	-	-	-	-	-	-	-
3 (Charidirimou et. al., 2013) ³	-	-	-	-	-	-	-
4 (Charidimou et. al., 2014) ⁴	?	?	?	?	+	+	+
5 (Doubal et. al., 2010) ⁵	-	-	-	-	-	-	-
6 (Gutierrez et. al. 2015) ⁶	-	-	-	-	-	-	-
7 (Hurford et. al. 2014) ⁷	-	-	-	-	-	-	-
8 (Klarenbeek et. al. 2013) ⁸	-	-	-	-	-	-	-
9 (Loos et. al. 2015) ⁹	-	-	-	-	-	-	-
10 (Martinez-Ramirez et. al. 2013) ¹⁰	-	-	-	-	-	-	-
11 (Ohba et. al., 2012) ¹¹	-	-	-	?	-	+	+
12 (Potter et. al. 2015) ¹²	-	-	-	-	-	-	-
13 (Ribal-lena et. al. 2016) ¹³	-	-	-	-	-	-	-
14 (Rouhl et. al. 2008) ¹⁴	-	-	-	-	-	-	-
15 (Shams et. al. 2016) ¹⁵	-	-	-	-	-	-	-
16 (Uiterwijk et. al. 2014) ¹⁶	-	-	-	-	-	-	-
17 (Wu et. al. 2015) ¹⁷	?	?	?	?	+	+	+
18 (Yakushiji et al 2014) ¹⁸	-	-	-	-	-	-	-
19 (Yang et al 2016) ¹⁹	-	-	-	-	-	-	-
20 (Yao et al 2014) ²⁰	-	-	-	-	-	-	-
21 (Zhang et al 2014) ²¹	-	-	-	-	-	-	-
22 (Zhang et. al. 2016) ²²	-	-	-	-	-	-	-
23 (Zhu et al 2010) ²³	-	-	-	-	-	-	-

Supplementary Table 2: Shows results of 93/116 studies reporting associations between PVS and clinical outcomes, which could not be included in the meta-analysis. BG: Basal Ganglia, CS: centrum semiovale, T1: T1-weighted image, T2: T2-weighted image, FLAIR: fluid-attenuated inversion recovery, CAA: cerebral amyloid-angiopathy, MPS: Mucopolysaccharide Disease. *=one study given two rows (for different outcomes) for display purposes.

Reference	Number of Subjects	Age (mean)	Subject Characteristics	Disease Associated	Association test result?	Brain Region	Geographic Region	Rating Scale	Type of scanner and MRI sequence
Achiron and Faibel, 2002 ²⁴	71	26.8	Multiple Sclerosis	PVS	55% of patients have visible PVS	Corpus collosum and upper brain area	Israel	Heier et al 1989 ²⁵	2T, T1 and T2
Adachi et al 2000 ²⁶	43	NA	Large vessel disease	Lacunar infarct	Higher grade PVS are detected	BG	Japan	3 points	1.5 T T2
Adachi et al 2002 ²⁷	171	69	Stroke	Lacunar Infarction Atherothrombotic	63.5% have high grade PVS 24.5% have high grade PVS	BG	Japan	3 points	1.5T T2
Aigner et al 2005 ²⁸	84	38	OCD		14% have dilated PVS	Most parts of the brain	Austria	“normal or abnormal”	0.5 T to 1.5 T, T1 and T2
Akiguchi et al 2014 ²⁹	503	75	The Vienna Trans-Danube Aging study	Idiopathic normal pressure hydrocephalus	PVS narrowing	CS	Austria & Japan	NA	NA
Al-Saeed et al 2012 ³⁰	80	15-49 range	Multiple Sclerosis		32% of patient have dilated PVS	supraventricular region	Kuwait	Heier et al 1989 ²⁵	1.5T, T1, T2 and FLAIR
Alqahtani et al 2014 ³¹	12	10.1	MPS type I and II		PVS are highly detected in these patients	cerebellum	US	4 points	NA T1 & T2
Anlar et al 2015 ³²	20	Less than 18	Tuberous Sclerosis		60% have enlarged PVS	NA	Turkey	NA	NA

Aribisala et al 2014 ³³	634	73	Lothian Birth Cohort 1936	Inflammation WMH	Adjusted $\beta=0.12$ ($P=0.048$) Adjusted $\beta=0.47$ ($P<0.0001$)	Hippocampus, BG and CS	UK	NA	1.5 T, T1, T2 and FLAIR
Azevedo et al 2013 ³⁴	25	10.6 \pm 4.52	MPS		90.5%	NA	Brazil	Mild and severe	1.5T FLAIR
Beak et al 2015 ³⁵	No cognitive disorders (NCD): 73 Dementia: 387 Mild cognitive impairment (MCI): 290	70.8	Memory clinic patients	Dementia and MCI	NCD of 2.7%; dementia of 11.7% & MCI: 7.9% have visible PVS NCD of 5.5%; dementia of 12.9% & MCI: 11.4% have visible PVS	BG CS	Korea	NA	NA
Berezuk et al 2015 ³⁶	26	NA	Sunnybrook Stroke Prevention Clinic	Wake after sleep onset	Rho: 0.52 ($p = 0.02$).	BG	Canada	Patankar et al. 2005 ³⁷ and Doubal et al 2010 ³⁸	3T, T1
Biedron et al 2014 ³⁹	53	11.58	Neurological Disorders		3.98%	NA	Poland	NA	1.5T
Boddaert et al 2009 ⁴⁰	77	7.4	Autism		12 subjects have dilated PVS	Heier et. al. 1989	France	Heier et. al. 1989 ²⁵	1.5T, T1, T2 and FLAIR
Bouvy et al 2016 ⁴¹	50	63	Utrecht Diabetic Encephalopathy Study (UDES2)	Microbleeds	Standardised: $\beta=0.32$ (95% CI, -0.10-0.77)	BG	Netherlands	Adams et. al. 2013 ⁴²	7T, 3D T2

			and PREDICT-MR study	WMH	$\beta=0.56$ (95% CI, 0.12-0.99) Standardised: $\beta= 0.46$ (95 CI, -0.25-0.94) $\beta= 0.39$ (95% CI, -0.9-0.87)	CS BG CS			
Boxerman et al 2007 ⁴³	50		Rolandic Epilepsy	Inflammation	6 cases	NA	US	NA	
Calleja Gero et al 2012 ⁴⁴	19	NA	MPS		73% of patients have PVS	NA	Spain	NA	T1 and T2
Chadirimou et al 2014 ⁴	14	NA	CAA		85.7% patients have PVS	CS	UK	4 points	1.5T T2
Charidimou et al 2015 ⁴⁵	11	NA	CAA	Pittsburgh compound B binding (measure of amyloid β deposition)	Continuous: Coefficient= 0.11 (95% CI, 0.01–0.22) Dichotomous: Coefficient= 0.27 (95% CI, 0.11–0.44)	CS	UK	4 points	3T, T1 and T2
Charidimou et al 2016 ⁴⁶	105	72.7	ICH with and without	CAA	24% 54.8%	BG CS	UK	4 points	T2, FLAIR and SWI
Chen et al 2011 ⁴⁷	158	74.97	MCI	Mild cognitive impairment	$r = -0.21, P = .009$	BG	Canada	4 points	T1
Cheng et al 2003 ⁴⁸	26	49.7	Immunocompromised patients: Systemic Lupus Erythematosus	cryptococcal infection	7 patients have dilated PVS	BG	Taipei	NA	NA

Conforti et al 2014 ⁴⁹	40	42.7	Multiple Sclerosis		There is a significant PVS count in MS patients	NA	Italy	NA	3T, T2 and FLAIR
Conforti et al 2016 ⁵⁰	82	18-15	Multiple Sclerosis	Fatigue	$r = 0.208$ ($p = 0.05$)	Basal Ganglia and Midbrain	Italy	NA	3T, T1, T2&FLAIR
Cumurciuc et al 2006 ⁵¹	50	55.3	CADASIL		78% with dilated PVS	Subcortical white matter and temporal lobe, CS and lentiform nucleus	France	Heier et. al. 1989 ²⁵	1.5T, T2 and FLAIR
Davila et al 2010 ⁵²	23	28.1	Tourette's syndrome		26% have enlarged PVS	Midbrain nuclei	Spain	NA	1.5T & 3T, T2
Di Costanzo et al 2001 ⁵³	41	39	Myotonic Dystrophy		Multiple regression, $r_s = -0.37$ ($p = 0.019$)	Anterior Commissure	Italy	3 points	0.5T, T1, Proton Density and T2
Di Costanzo et al 2002 ⁵⁴	66	38.4	Myotonic Dystrophy Type 1		$\chi^2 = 20.1$ ($p < 0.001$)	Anterior Commissure	Italy	3 points	0.5T, T1, T2 and photon density weighted image
Field et al 2016 ⁵⁵	1137	NA	Lacunar Stroke		55% of patients have visible PVS	NA	UK	4 points	various FLAIR/T1
Foo et al 2016 ⁵⁶	With small vessel disease progression: n: 59	68.4	Parkinson's		There was significant increase in the PVS volume between baseline and follow-up	Thalamus, caudate, putamen, pallidum,	UK	NA	3T T1

	Without small vessel disease progression: 14	66.16				hippocampus, amygdala and accumbens			
Groeschel et al 2007 ⁵⁷	35	7.5	adrenoleukodystrophy		87% patients have PVS	supratentorial white matter and basal ganglia	Germany	NA	1.5T, T1, T2 and FLAIR
Guo et al 2016 ⁵⁸	34	5.6	HIV	Infection-cryptococcal meningitis	44.4%	NA	China	NA	NA
Gutierrez et al 2013 ⁵⁹	706	71.6	Northern Manhattan Study	Age Hypertension carotid plaque	Adjusted multivariable analysis: $\beta = 0.01$ ($p = .02$) $\beta = 0.24$ ($p < .001$) $\beta = 0.22$ ($p < .001$)	White matter, BG, brain stem, cerebellum	US	2 points	1.5T, T1 and FLAIR
Gutierrez et al 2017 ⁶⁰	1228	71	Northern Manhattan Study	Death Vascular death Stroke Vascular event	HR: 1.35 (95% CI, 1.00-1.78) HR 1.55 (95% CI, 0.96-2.51) HR 1.53 (95% CI, 0.91-2.57)	NA	US	NA	NA, absence of FLAIR rim

					HR 1.50 (1.07-2.11)				
Hansen et al 2015 ⁶¹	151	76.33	Elderly Patients	Healthy vs Dementia Healthy vs Alzheimer's Healthy vs Vascular Dementia	Z score/ β coefficient: -3.0741/-1.094 -3.161/-1.002 -2.623/-1.956	BG	UK	Patankar et. al. 2005 ³⁷ & Doubal et. al. 2010 ³⁸	1.5T, FLAIR and T1
Hasiloglu et al 2011 ⁶²	21	42.9	boxers		90%, $\chi^2 = 4.434$, $df = 1$, $P = .0176$)	NA	Turkey	NA	1.5T, T1 and T2
Hayashi 2002 ⁶³	71	8.7	Polymicrogyria		27% patients have dilated PVS	frontal lobe, parietal lobe, temporal, occipital and Sylvian	Japan	NA	NA, T1 and T2
Heier et al 1989 ²⁵	314	61-80	Outpatients		Age, white matter lesion, dementia, hypertension and atrophy patients have high grade PVS	BG & CS	US	Heier et al 1989 ²⁵	1.5T
Huijts et al 2013 ⁶⁴	189	63	Lacunar stroke and hypertension	cognition	($\beta = -0.099$; 95% CI = -0.183 to -0.016 , $p = 0.019$)	BG	Netherlands	Doubal. et. al. 2010 ³⁸	1.5T or 3T, T2 and FLAIR
Husøy et al 2016 ⁶⁵	1006	NA	Nord-Trøndelag Health Survey	Headache	OR= 0.84, (95% CI = 0.76-0.94)	BG	Norway	NA	1.5T,

					OR=0.97 (95% CI = 0.95-1.00)	BG & Hemispheric white matter			T1, T2 and FLAIR
Inglese et al 2006 ⁶⁶	38	35	Mild traumatic brain Injury (TBI)	MRI appearance Quick writing test Processing speed	Mean(SD): 6.9 (± 4.3) $r = 0.4 (p = 0.017)$ $r = -0.84 (p = 0.006)$	NA	US	NA	1.5T, T1, T2 and FLAIR
Kilsdonk et al 2015 ⁶⁷	34	43	Multiple Sclerosis	PVS	More PVS appearance of patients compared to control (median: 11 vs 4)	handknob, including VRS in the vertex, crus anterior, anterior commissure, the transition between third ventricle and aqueduct, including VRS in the basal ganglia, peduncles and midbrain	Netherlands	NA	7T, T1, T2 & FLAIR
Koo et al 2016 ⁶⁸	85	NA	CAA	CAA & CMB	Both have high association with PVS	CS	Korea	2 points	3T T2

Lauer et al 2016 ⁶⁹	49	NA	Microinfarcts		Median: 3 (2.0-4.0)	CS	US	4 points	1.5T or 3T, T1, T2 and FLAIR
Lee et al 2015 ⁷⁰	11	NA	Parkinson's	K-MMSE MoCA-K FAB	r= - 0.675 r= -0.847 r= -0.868	BG	Korea	3 points	1.5T, T1 and T2
Loyse et al 2015 ⁷¹	87	NA	HIV	cryptococcal meningoencephalitis	63% of patients have dilated PVS	NA	South Africa	NA	NA
MacLulich et al 2004 ⁷²	97	67.8	Elderly men	Reading Test (NART)	Spearman's ρ = -0.21 p=0.038	BG CS	UK	Doual et. al. 2010 ³⁸	1.9T T2
Manara et al 2011 ⁷³	36	10.4	MPS		89%	NA	Italy	NA	1.5T or 3T T2
Matheus et al 2004 ⁷⁴	18	12.8	MPS		88.89%	NA	US	NA	1.5T, T1 and T2
Mendes et al 2015 ⁷⁵	11	NA	MPS type I, II and IV	hydrocephalus	63.6% of patients have PVS	NA	Brazil	NA	Phase-contrast MRI
Mercieca et al 2016 ⁷⁶	9	NA	Glaucoma		Z score: -2.27 (p<0.05)	BG	UK	Doual et. al. 2010 ³⁸	1.5T T1,
Miszkiel et al 1996 ⁷⁷	25	NA	AIDS	CNS cryptococcosis	10/25 patients have dilated PVS	Temporal lobes	UK	NA	1.5T, T1 and T2
Muir et al 2016 ⁷⁸	346	NA	Sunnybrook Dementia Study	Enlarged PVS associated with WMH	β =0.25 (p<0.0001)	Global white matter	Canada	NA	NA
Mutlu et al 2016 ⁷⁹	704	66	Rotterdam study	Retinal Microvascular	arterioles RR: 1.07 (1.01-1.14)	CS	Netherlands	Adams et. al. 2013 ⁴²	NA

				Calibers	RR: 1.13 (1.04–1.22)	Hippocampus			
					Veins RR: 1.08 (1.01–1.16)	CS			
					RR: 1.09 (1.00–1.18)	Hippocampus			
Park et al 2011 ⁸⁰	78	68	internal carotid artery stenocclusive disease (ICA)	ICA age	P<0.05 P<0.05 P<0.001	Ipsilateral hemisphere Ipsilateral hemisphere Contralateral hemisphere	Korea	3 points	3T T2
Parker et al 2011 ⁸¹	21	29.2 years (8.62)	Asthma		24%	NA	US	NA	NA, T1, T2 and FLAIR
Patankar et al 2005 ³⁷	75	63.4	Elderly patients	Ischemic vascular dementia Frontotemporal Dementia	$R^2 = 0.24, P < .05$ $R^2 = 0.43, P < .01$	CS	UK	Patankar et al 2005 ³⁷	1.5T, T1, T2 and FLAIR
Prayer et al 2004 ⁸²	163	0.4-47 range	Intracranial disease	Langerhans cell histiocytosis	70% of patients have visible PVS	Whole brain	Austria	NA	NA, T1 and T2

Ramirez et al 2015 ⁸³	203	NA	Sunnybrook Dementia Study	Lacunae WMH	$r = 0.3 (p < 0.01)$ $r = 0.3 (p < 0.01)$	BG and CS	Canada	Patankar et al 2005 ³⁷ and Doubal et al 2010 ³⁸	1.5T, T1 and T2
Rouhl et al 2008 ¹⁴	165	NA	Maastricht Stroke Registry	Periventricular WML asymptomatic lacunar infarcts age silent ischemic lesion	$\beta: 0.19 (p < 0.001)$ $\beta: 0.26 (p < 0.05)$ $\beta: 0.02 (p < 0.001)$	BG	Netherlands	3 points	1.5T, T2 and FLAIR
Sahin et al 2015 ⁸⁴	18	68.62	unilateral severe carotid artery stenosis	White Matter Lesion	Mean (SD) 4.07 (1.00) 1.93(0.26) 3.69 (1.04) 1.90 (0.31)	Unilateral hemisphere: BG CS Contralateral hemisphere: BG CS	Turkey	Patankar et al 2005 ³⁷	1.5T, T1, T2, FLAIR & DWI
Schick et al 1999 ⁸⁵	58	10.8	Patients with recurrent headache	Headache	61% of migraine patients have prominent PVS	Brain stem and Anterior commissure	Vienna	NA	0.5T, 1.0T and 1.5T, T1, T2 and FLAIR
Schwedt et al 2006 ⁸⁶	241	children		headache	4/22 have PVS	NA	US	NA	NA

Selvarajah et al 2009 ⁸⁷	32	61.75	Patient from diabetes, vascular disease, cardiology, renovascular and hypertension clinics.	WMH	β : 4.63 (95%CI, 1.18-8.08)	BG	UK	5 points	3T, T1, FLAIR and IR
Song et al 2015 ⁸⁸	220	64	Acute ischemic stroke	EPA DHA \sum n-3-PUFAs	OR= 0.62 OR= 0.74 OR= 0.77	BG	Korea	Doubal et. al. 2010 ³⁸	1.5T, T2
Song et al 2017 ⁸⁹	170 170	58 NA	Sleep Apnea	NA	Spearman's ρ = 0.338 (p=0.004) OR: 3.64 (95% CI 1.02–13.01)	BG & CS NA	South Korea	4 points NA	NA NA
Song et al 2016 ⁹⁰	737	63	Acute ischemic stroke	complex aortic plaques simple aortic plaques	5.70 (3.19-10.19) 2.74 (1.75-4.31)	BG&CS	South Korea	4 points	3T T2
Sun et al 2014 ⁹¹	461	NA	Lacunar Infarcts	E-selectin Adiponectin	OR=3.83 (95% CI, 2.62–5.95) OR=2.80 (95% CI, 2.00–3.90) OR=0.31 (95% CI, 0.22–0.43) OR=0.53	CS BG CS BG	China	NA	3T, T1, T2 and FLAIR

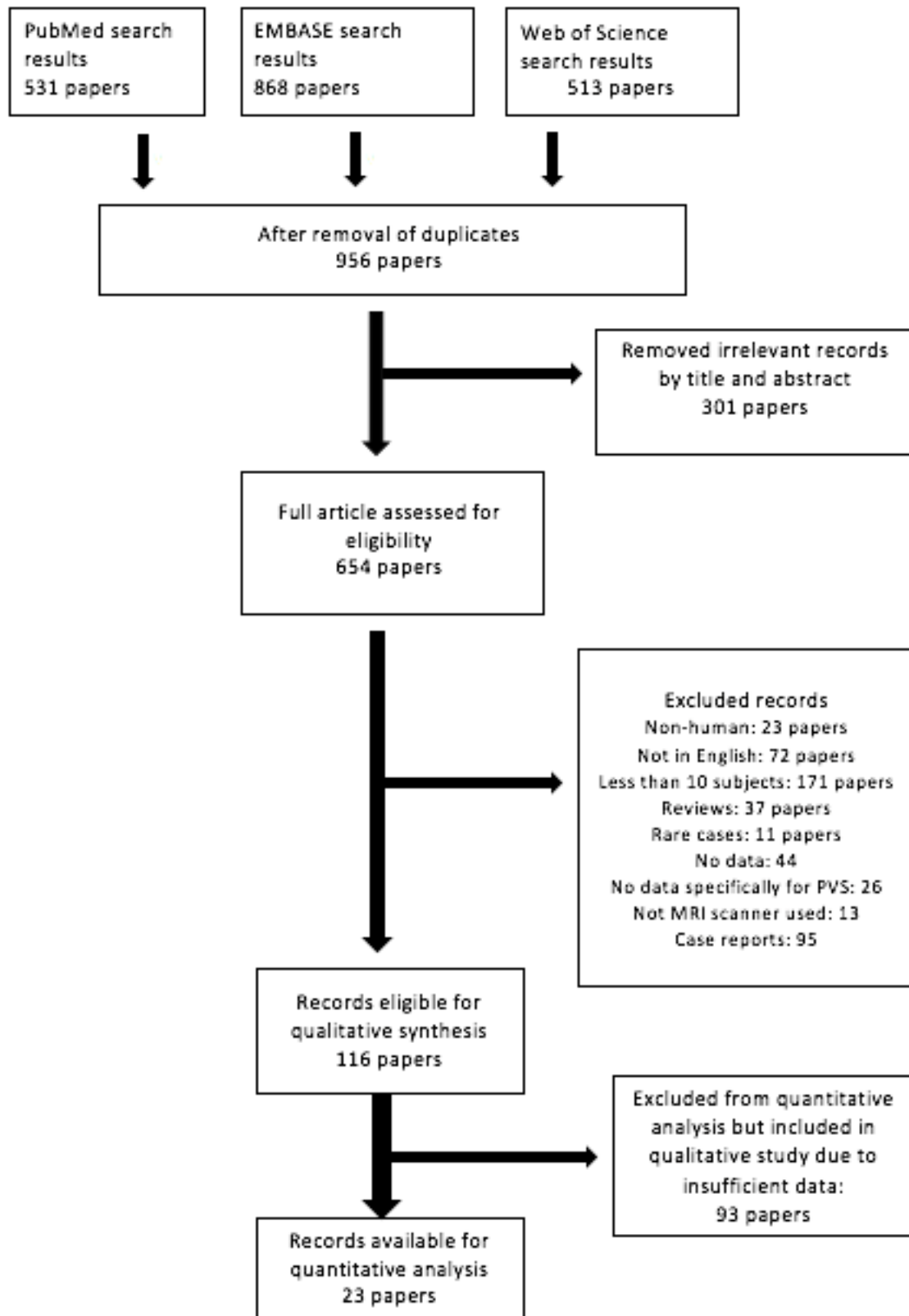
					(95% CI, 0.40–0.70)				
Taber et al 2004 ⁹²	16	143.5 months	autism		44%	NA	US	NA	1.5T, T1 and T2
Tarnaris et al 2011 ⁹³	12	70	Adult hydrocephalus		All patients have VRS in CS 11/12 have VRS in BG	CS BG	UK	Patankar et al 2005 ³⁷	1.5T, T1, T2 and FLAIR
Tan et al 2016 ⁹⁴	18	Median: 45.5	cryptococcal meningitis		27.8 % of patients have multiple PVS	BG and periventricular white matter	China	NA	1.5T, T1, T2 and FLAIR
Thanprasertsuk et al 2014 ⁹⁵	85		CAA	Correlation between WMH and PVS	β (95% CI) = -5.61 (-8.94 to -2.28)	BG	US	4 points	1.5 T, T2
Tien et al 1991 ⁹⁶	29		immunocompromised patients		3 patients have dilated PVS	NA	US	NA	1.5T
Tokola et al 2015 ⁹⁷	20	15.6, SD 7.3	AGU-rare disease	Aspartylglucosaminuria(AGU)	60%	NA	Finland	NA	1.5T and 3T, T1 and T2
Uiterwijk et al 2016 ⁹⁸	130	58.7	The hypertension and brain damage study (HYBRiD) and cognitive function in small vessel stroke study	Overall cognition	R ² : 2.5% (p=0.077)	BG	Netherlands	Mild, moderate or extensive	1.5T and 3T, T2 and FLAIR

Valtonen et al 1999 ⁹⁹	60	32	gyrate atrophy		Mean GA vs control: 48±39 vs 13 ±11	NA	Finland	NA	1.5T, T2
van der Land et al 2015 ¹⁰⁰	10	23	Sickle cell anaemia		7/10	NA	Netherlands	4 points	3T and 7T, T1
van Rooden et al 2016 ¹⁰¹	27	45.9	CAA		Higher PVS in symptomatic patients	CS	Netherlands	NA	3T and 7T, T1, T2 and FLAIR
van Sloten et al 2015 ¹⁰²	1949	74.6	AGES-Reykjavik Study	depression	OR=1.08(95%CI, 0.70-1.66)	NA	Iceland	NA	1.5T, T1 and T2
van Sloten et al 2016 ¹⁰³	2058	79.6	AGES-Reykjavik Study	carotid-femoral pulse wave velocity and depression score	$\beta=0.001$ (95%CI= -0.003 to -0.007)	NA	Iceland	NA	1.5T, T2 and FLAIR
Vanderver et al 2014 ¹⁰⁴	23		PTEN Mutations		20/23	BG	Brazil, Italy and Netherlands	NA	NA
Vilar-Bergua et al 2016 ¹⁰⁵	975	64	Investigating Silent Strokes in hypertensives: a magnetic resonance imaging study cohort	microalbuminuria	77.1% of patients have PVS	BG	Spain	4 points	1.5T T2
Vilar-Bergua et al 2016 ¹⁰⁶	278	63	Investigating Silent Strokes in Hypertensives: A Magnetic Resonance Imaging Study	N-terminal pro-brain natriuretic peptide levels	OR 1.55, 95% CI 1.12–2.15	BG	Spain	4 points	1.5T
Wang et al 2016 ¹⁰⁷	100	69	Stroke		Adjusted multivariable linear regression,	BG	UK	NA	1.5T T2

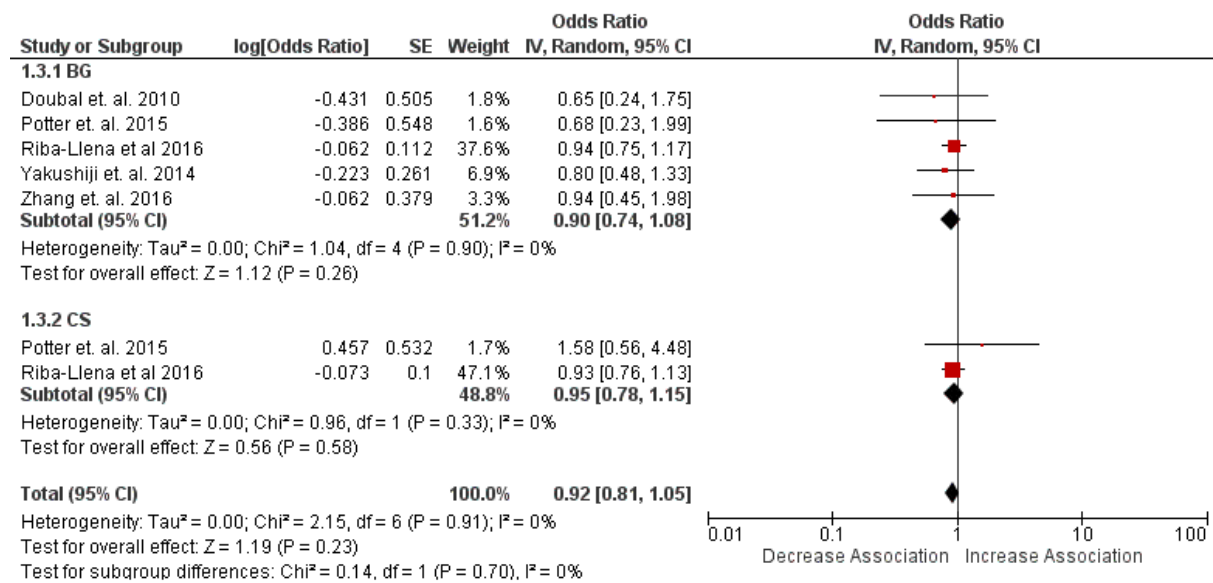
				Hypertension Ageing	$r = 2.225$ ($p = .013$) $r = .117$ ($p = .003$)				
Wardlaw et al 2009 ¹⁰⁸	97		Lacunar stroke	Blood barrier dysfunction	F: 0.9 to 3.96; p ranged from 0.46 to 0.003	CS	UK	Doubal et. al. 2010 ³⁸	1.5T
Wardlaw et al 2013 ¹⁰⁹	634	72.5	Lothian Birth Cohort 1936	g-Inflammation	Adjusted for age, sex, stroke and vascular factors: β = 0.12 ($p=0.047$)	basal ganglia, hippocampus and centrum semiovale	UK	NA	NA
Wiseman et al 2016 ¹¹⁰	51	NA	Systemic Lupus Erythematosus(SL E)	SLE HDL cholesterol	100% have PVS OR= 14.88; (95%CI, 2.76– 80.09)	All CS	UK	4 points	1.5T T2
Wuerfel et al 2008 ¹¹¹	45	39.8	Multiple sclerosis	Volume of PVS Age	Mean compared to control: 280.8 \pm 165.1 ($p=0.004$) $r = 0.485$ ($p =$ 0.007)	Basal Ganglia	Germany	NA	1.5T, T1, T2 & FLAIR
Xiao et al 2015 ¹¹²	413	64.41	Chronic kidney disease	eGFR	OR= 2.37 (95% CI, 1.19–4.73)	CS	China	3 points	3T T2

				proteinuria	OR=2.59 (95% CI 1.19–5.64)	CS			
				eGFR	OR=4.17, (95% CI, 2.08-8.37)	BG			
				proteinuria	OR=5.12 95% CI 2.70 to 12.10	BG			
Yun 2013 ¹¹³	17	57.8	MCI	MCI	Mean number of PVS found: 8.1+/- 4.8	NA	South Korea	NA	NA, T1 and T2
Zeegers et al 2006 ¹¹⁴	45	43 months	Autism	3 patients had abnormal PVS	Only 3 children (6.7%) have enlarged PVS	BG, the corpus callosum, the ventricles, the brain stem, and the cerebellum	Netherlands	NA	1.5T, T1 and T2
Zhang et al 2017 ¹¹⁵	374	61.7	Acute Stroke	Post Stroke Depression	OR: 1.557 (95% CI, 0.958–2.530)	BG	China	3 points	1.5T, T2 and FLAIR
Zhu et al 2010 ²³	1778	NA	Elderly	Dementia	HR = 5.8, 95% CI 1.2–28.4 HR = 9.8 (95% CI 1.7–55.3)	BG White matter	France	2 points	1.5T, T1, and T2
Zhu et al 2010 ²³	1818	72.5	3 Dijon cohort	White matter	X ² = 100 (9df, p= 0.0001	BG	France	4 points	1.5T, T1 and T2

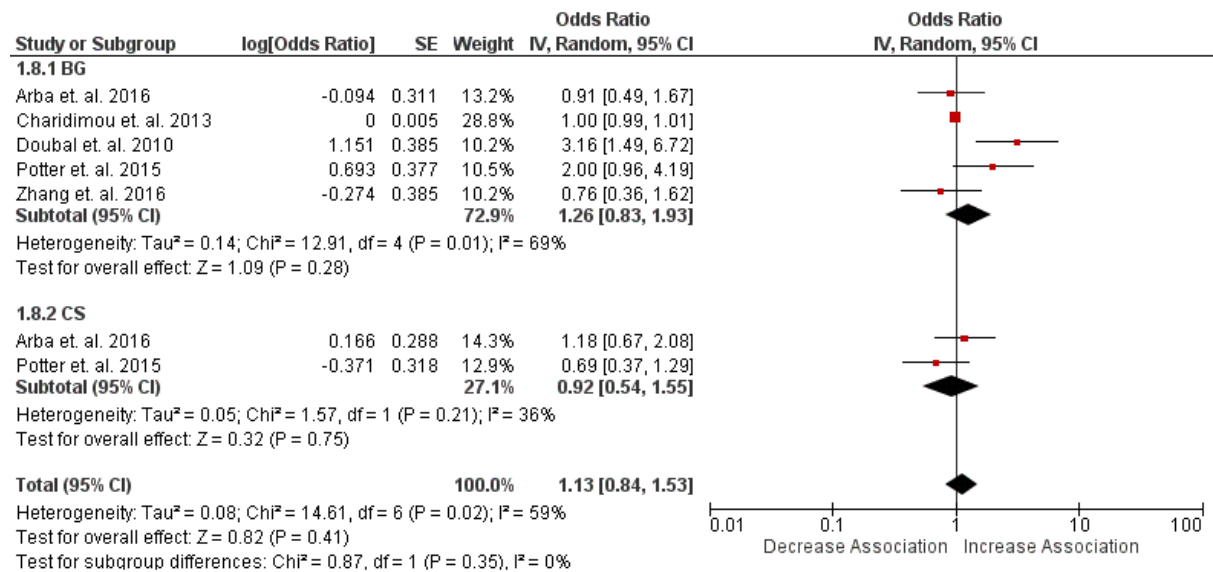
Supplementary Figure 1: Flowchart showing the search and study selection process.



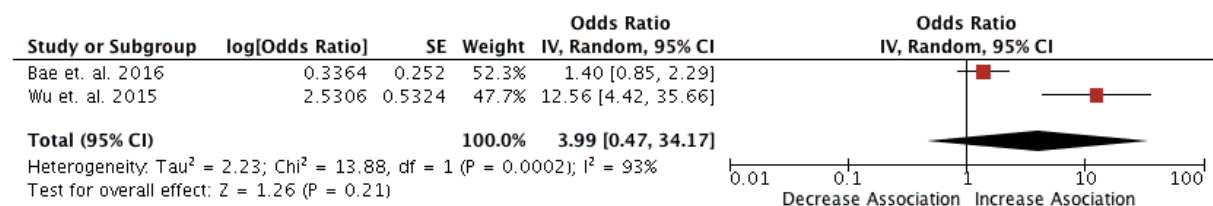
Supplementary Figure 2: Forest plot for association of PVS and diabetes in BG and CS.



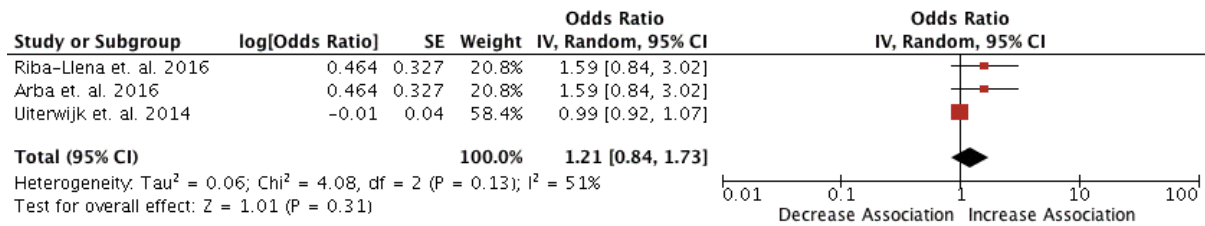
Supplementary Figure 3: Forest plot of association of lacunar or non-lacunar stroke and PVS in BG and CS.



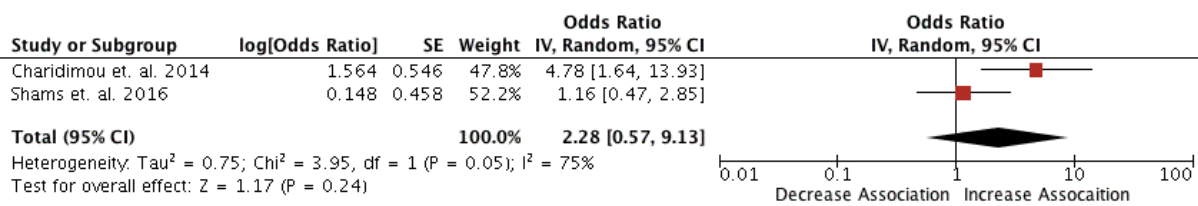
Supplementary Figure 4: Forest plot of PVS in BG for acute stroke.



Supplementary Figure 5: Forest plot of PVS association with cognitive impairment.



Supplementary Figure 6: Forest plot of PVS and cortical superficial siderosis.



Funnel plots

Figure 1: Shows funnel plot for hypertension

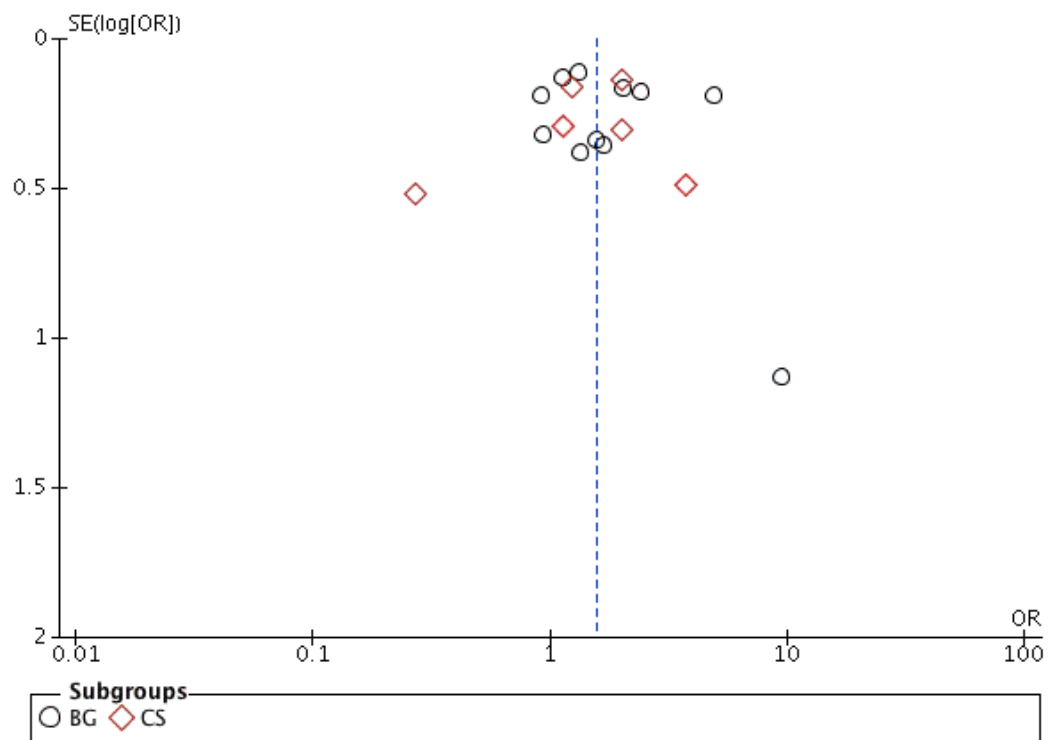


Figure 2: Shows funnel plot for ageing.

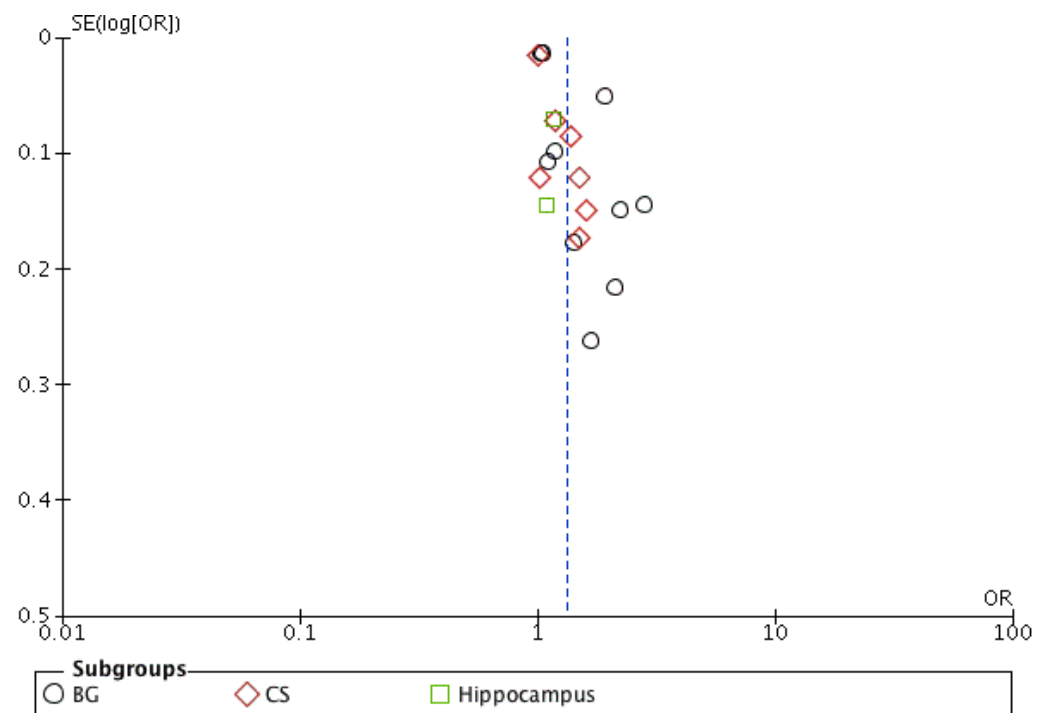


Figure 3: Shows funnel plot for acute stroke.

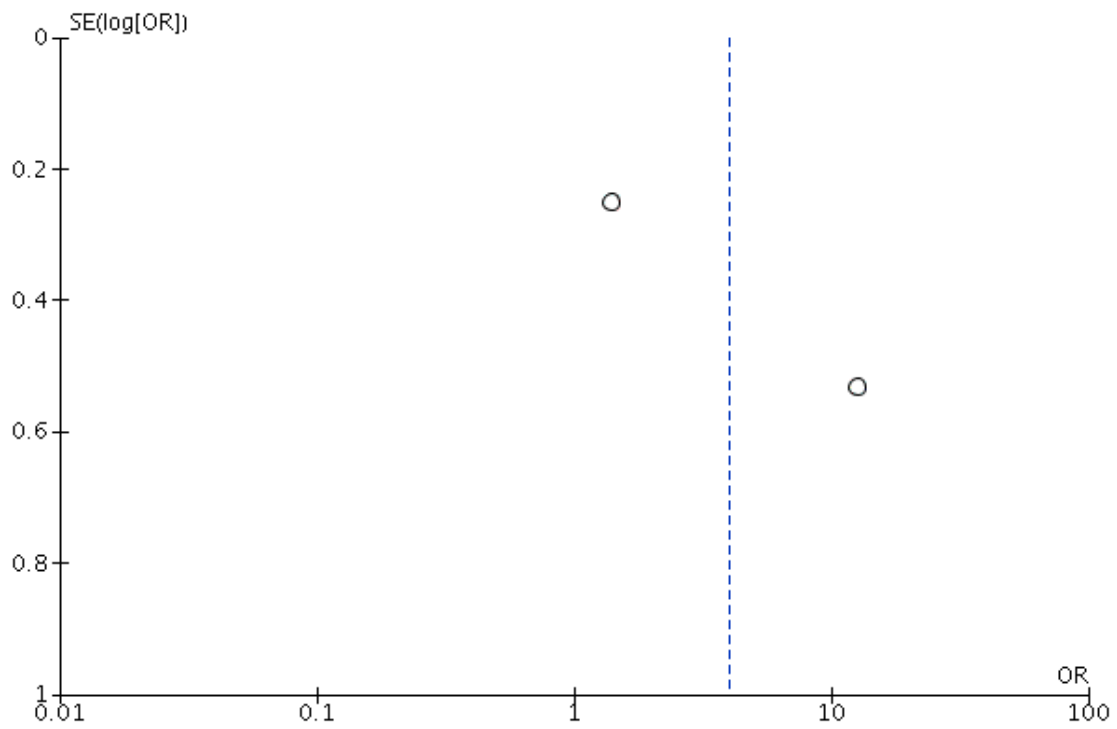


Figure 4: Shows funnel plot for cerebral microbleeds

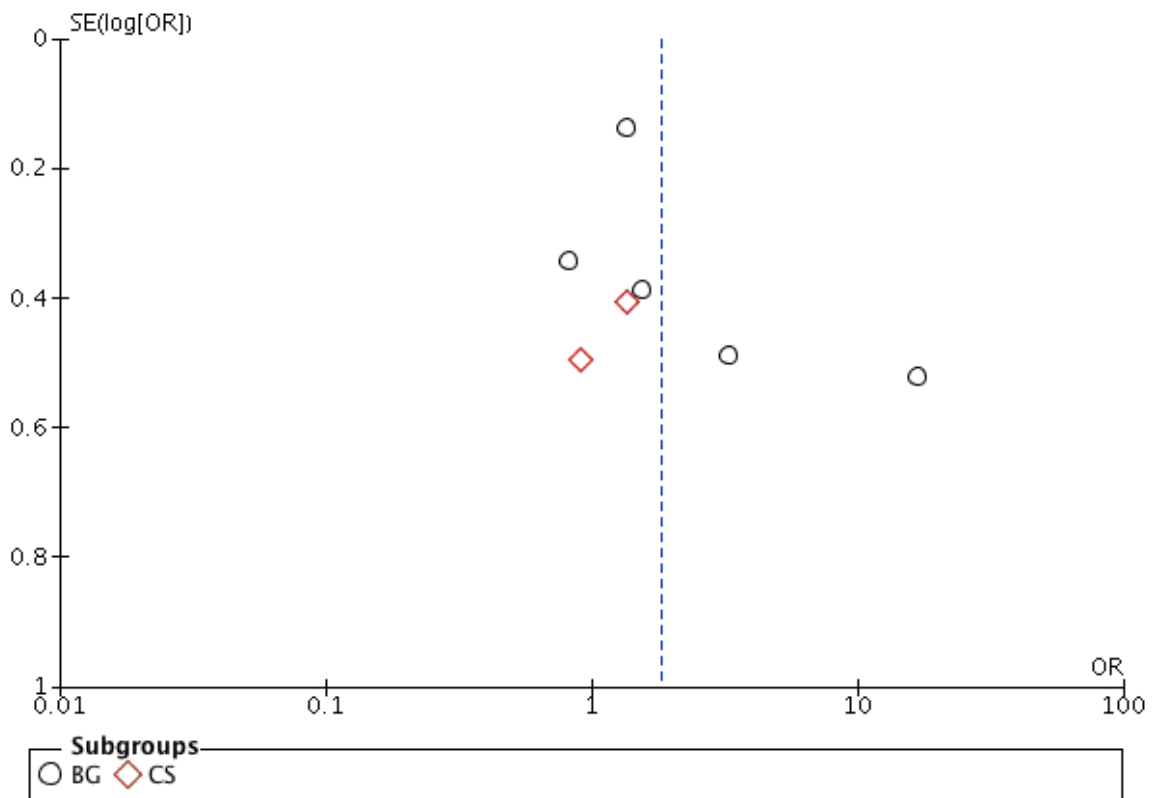


Figure 5: Shows a funnel plot for diabetes.

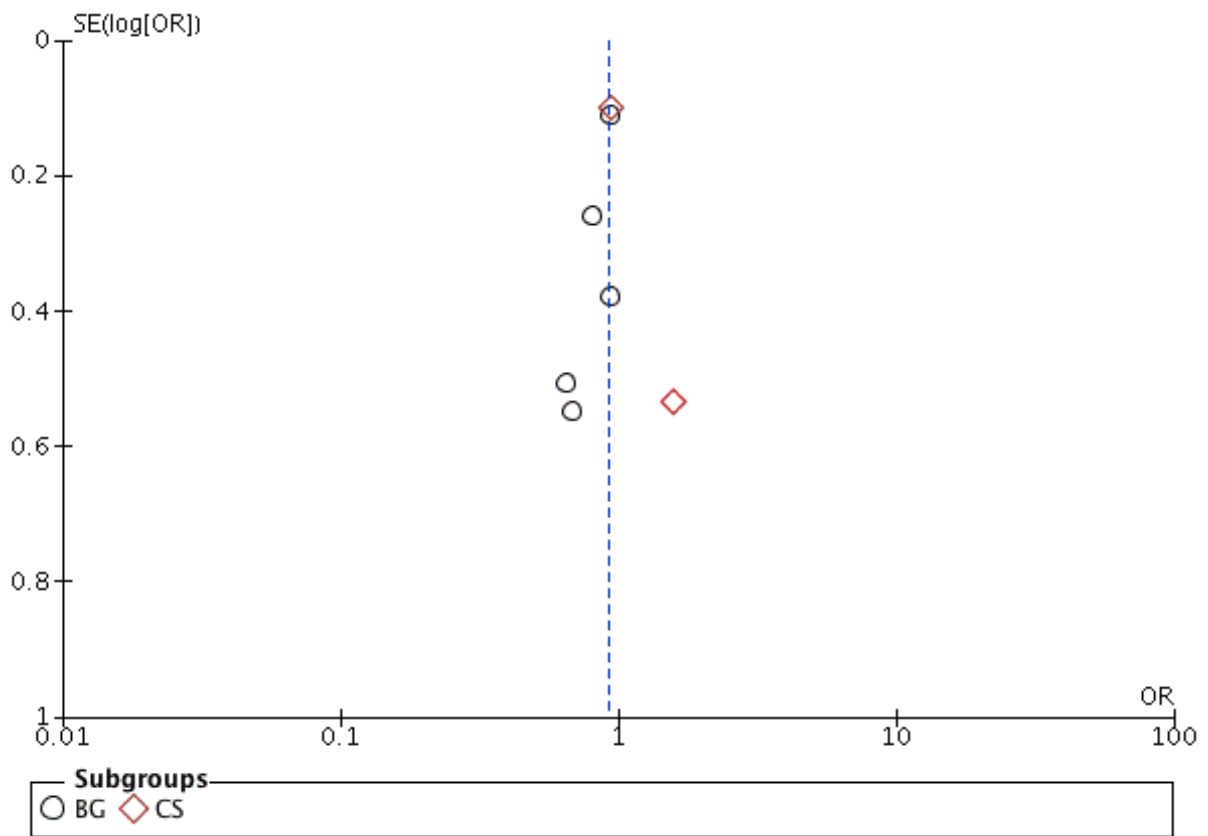


Figure 6: Shows funnel for cognitive impairment.

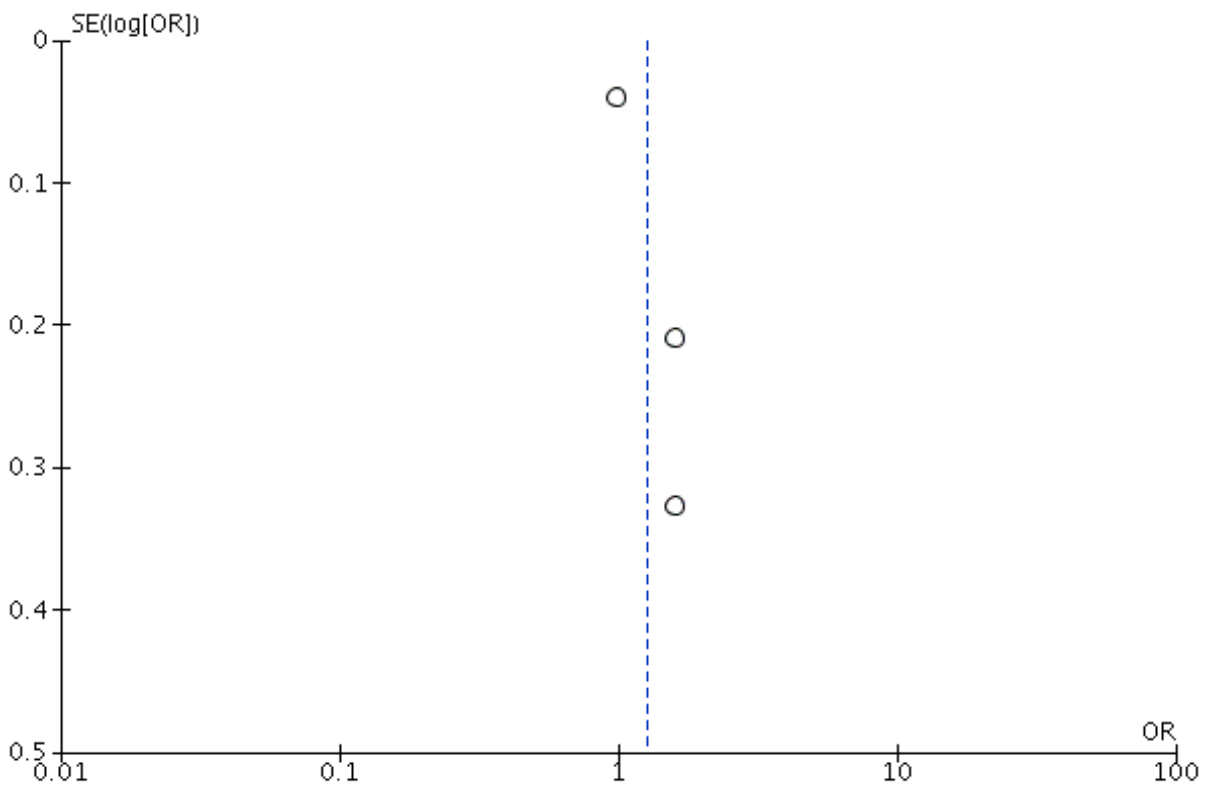


Figure 7: Shows funnel plot for WMH.

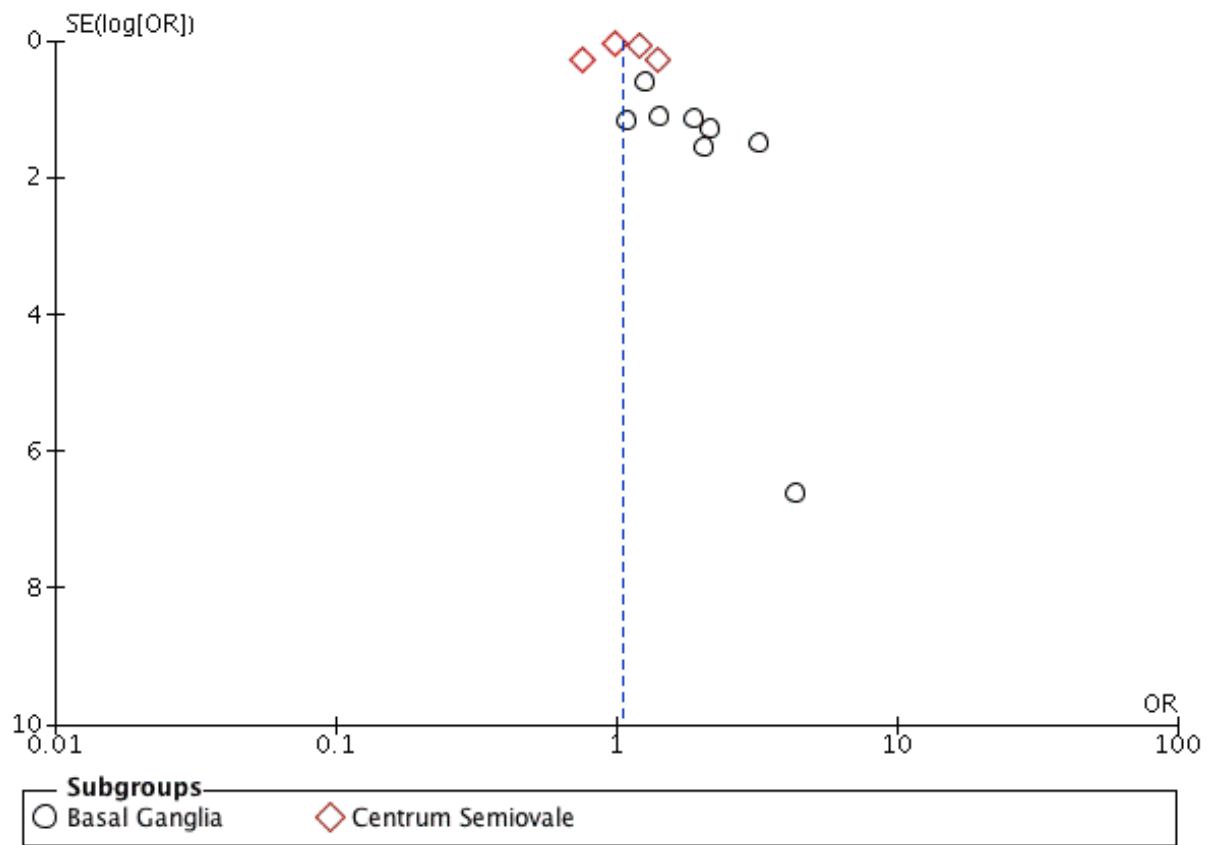


Figure 8: Shows funnel plot for lacunes.

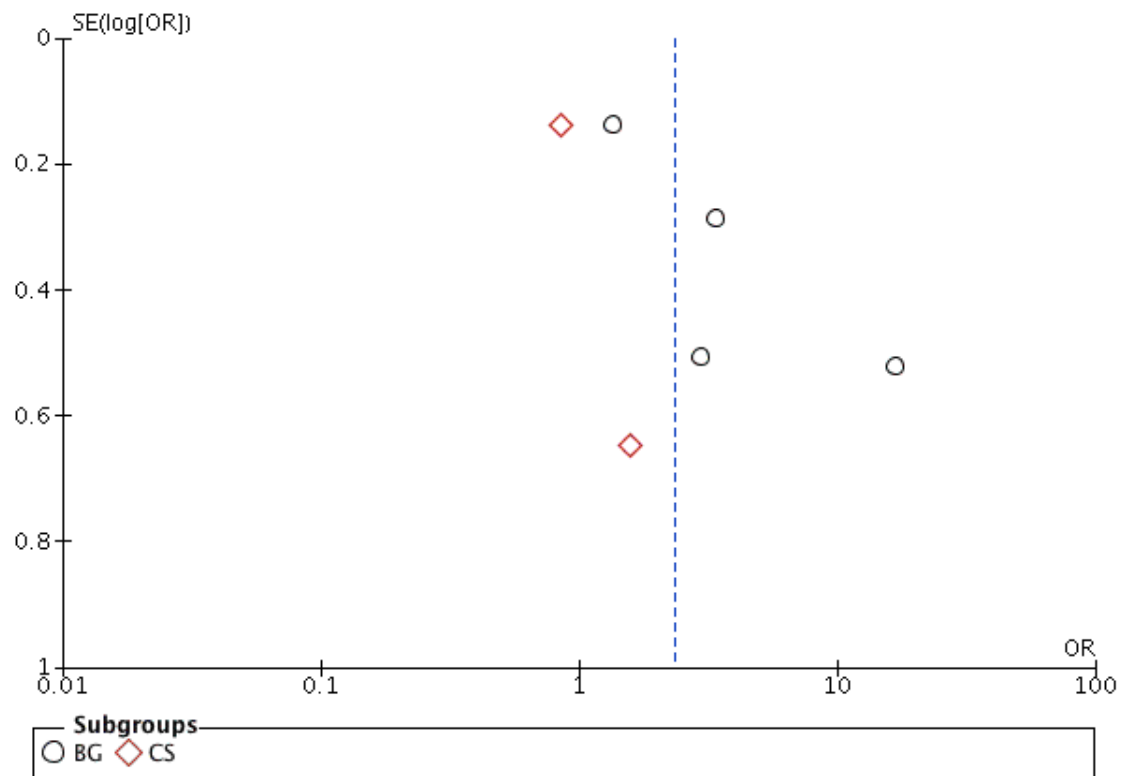


Figure 9: Shows funnel plot for lacunar stroke.

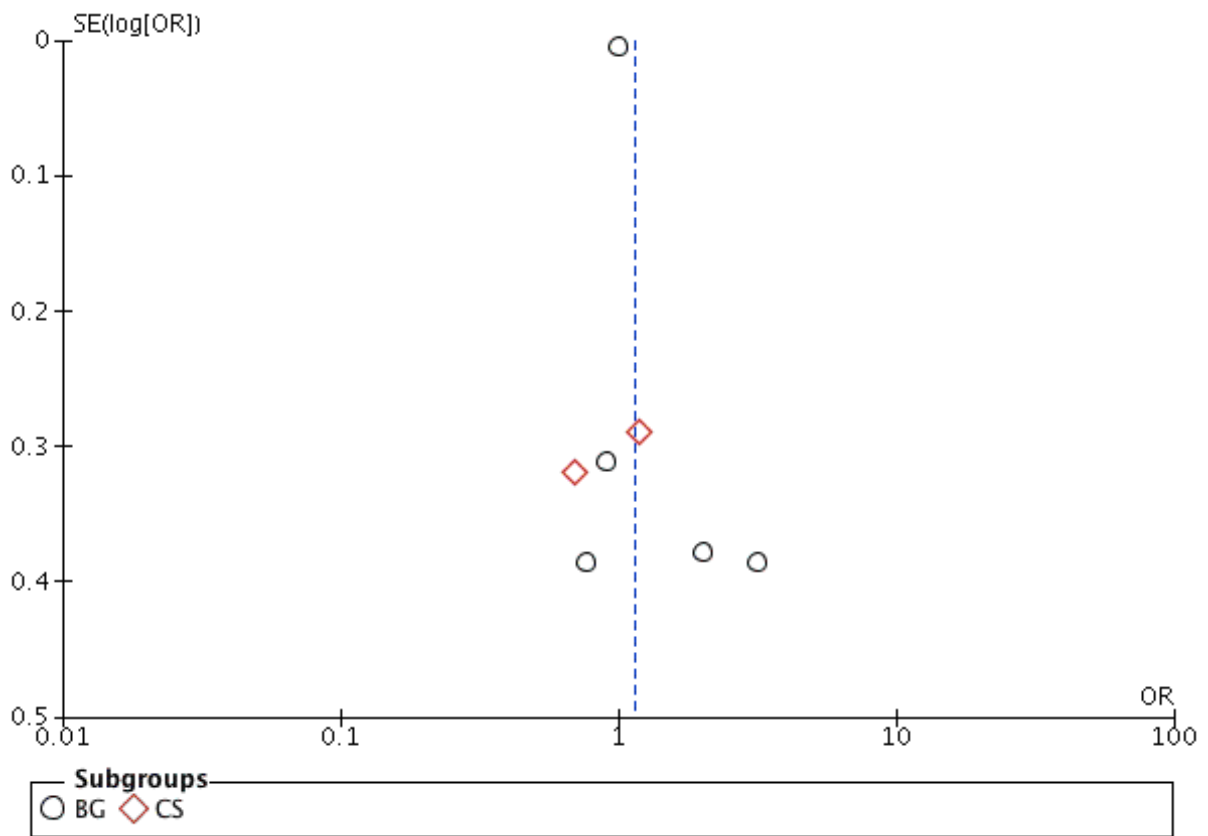
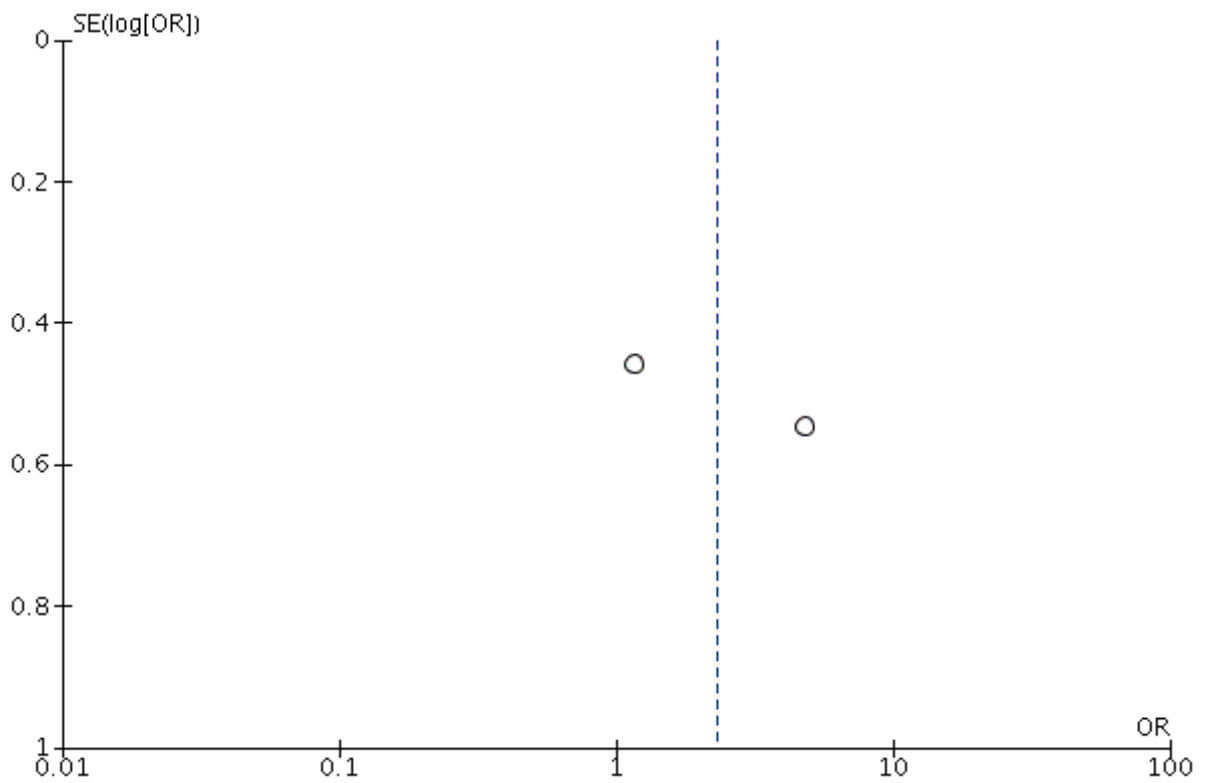


Figure 10: Shows funnel plot for CSS.



References

1. Arba F, Quinn TJ, Hankey GJ, et al. Enlarged perivascular spaces and cognitive impairment after stroke and transient ischemic attack. *International journal of stroke : official journal of the International Stroke Society*. 2016: 1747493016666091-.
2. Bae J-H, Park K-Y, Kim J-M and Park M-S. Abstract WP211: The Association Between Arterial Stiffness and Perivascular Space Topography in Stroke Patients. *Stroke*. 2016; 47: AWP211 LP-AWP.
3. Charidimou A, Meegahage R, Fox Z, et al. Enlarged perivascular spaces as a marker of underlying arteriopathy in intracerebral haemorrhage: a multicentre MRI cohort study. *Journal of neurology, neurosurgery, and psychiatry*. 2013; 84: 624-9.
4. Charidimou A, Jager RH, Peeters A, et al. White matter perivascular spaces are related to cortical superficial siderosis in cerebral amyloid angiopathy. *Stroke*. 2014; 45: 2930-5.
5. Doubal FN, MacLulich AMJ, Ferguson KJ, Dennis MS and Wardlaw JM. Enlarged perivascular spaces on MRI are a feature of cerebral small vessel disease. *Stroke*. 2010; 41: 450-4.
6. Gutierrez J, Elkind MS, Cheung K, Rundek T, Sacco RL and Wright CB. Pulsatile and steady components of blood pressure and subclinical cerebrovascular disease: the Northern Manhattan Study. *J Hypertens*. 2015; 33: 2115-22.
7. Hurford R, Charidimou A, Fox Z, Cipolotti L, Jager R and Werring DJ. MRI-visible perivascular spaces: relationship to cognition and small vessel disease MRI markers in ischaemic stroke and TIA. *J Neurol Neurosurg Psychiatry*. 2014; 85: 522-5.
8. Klarenbeek P, van Oostenbrugge RJ, Rouhl RPW, Knottnerus ILH and Staals J. Ambulatory Blood Pressure in Patients With Lacunar Stroke. *Stroke*. 2013; 44: 2995 LP-9.
9. Loos CMJ, Klarenbeek P, van Oostenbrugge RJ and Staals J. Association between Perivascular Spaces and Progression of White Matter Hyperintensities in Lacunar Stroke Patients. *PLOS ONE*. 2015; 10: e0137323-e.
10. Martinez-Ramirez S, Pontes-Neto OM, Dumas AP, et al. Topography of dilated perivascular spaces in subjects from a memory clinic cohort. *Neurology*. 2013; 80: 1551-6.
11. Ohba H, Pearce L, Potter G and Benavente O. Enlarged perivascular spaces in lacunar stroke patients. THE secondary prevention of small subcortical stroked (SPS3) trial. *Stroke Conference*. 2012; 43.
12. Potter GM, Doubal FN, Jackson CA, et al. Enlarged perivascular spaces and cerebral small vessel disease. *International Journal of Stroke*. 2015; 10: 376-81.
13. Riba-Llena I, Nafria C, Mundet X, et al. Assessment of enlarged perivascular spaces and their relation to target organ damage and mild cognitive impairment in patients with hypertension. *European journal of neurology*. 2016; 23: 1044-50.
14. Rouhl RPW, van Oostenbrugge RJ, Knottnerus ILH, Staals JEA and Lodder J. Virchow-Robin spaces relate to cerebral small vessel disease severity. *Journal of neurology*. 2008; 255: 692-6.
15. Shams S, Martola J, Charidimou A, et al. Cortical superficial siderosis: Prevalence and biomarker profile in a memory clinic population. *Neurology*. 2016: 1-8.
16. Uiterwijk R, Huijts M, Staals J, et al. Subjective cognitive failures in patients with hypertension are related to cognitive performance and cerebral microbleeds. *Hypertension*. 2014; 64: 653-7.
17. Wu B, Yao X, Lei C, Liu M and Selim MH. Enlarged perivascular spaces and small diffusion-weighted lesions in intracerebral hemorrhage. *Neurology*. 2015; 85: 2045-52.

18. Yakushiji Y, Charidimou A, Hara M, et al. Topography and associations of perivascular spaces in healthy adults; The kashima scan study. *Neurology*. 2014; 83: 2116-23.
19. Yang H, Shen R, Jin Z, et al. Dilated Virchow–Robin Spaces in First-Ever Lacunar Stroke Patients: Topography and Clinical Correlations. *Journal of Stroke and Cerebrovascular Diseases*. 2016; 25: 306-11.
20. Yao M, Hervé D, Jouvent E, et al. Dilated perivascular spaces in small-vessel disease: A study in CADASIL. *Cerebrovascular Diseases*. 2014; 37: 155-63.
21. Zhang C, Chen Q, Wang Y, et al. Risk factors of dilated Virchow-Robin Spaces are different in various brain regions. *PLoS ONE*. 2014; 9.
22. Zhang X, Ding L, Yang L, et al. Brain atrophy correlates with severe enlarged perivascular spaces in basal ganglia among lacunar stroke patients. *PLoS ONE*. 2016; 11.
23. Zhu YC, Tzourio C, Soumaré A, Mazoyer B, Dufouil C and Chabriat H. Severity of dilated virchow-robin spaces is associated with age, blood pressure, and MRI markers of small vessel disease: A population-based study. *Stroke*. 2010; 41: 2483-90.
24. Achiron A and Faibel M. Sandlike Appearance of Virchow-Robin Spaces in Early Multiple Sclerosis: A Novel Neuroradiologic Marker. *American Journal of Neuroradiology*. 2002; 23: 376-80.
25. Heier LA, Bauer CJ, Schwartz L, Zimmerman RD, Morgello S and Deck MDF. Large Virchow-Robin spaces: MR-clinical correlation. *American Journal of Neuroradiology*. 1989; 10: 929-36.
26. Adachi T, Kobayashi S, Yamaguchi S and Okada K. MRI findings of small subcortical "lacunar-like" infarction resulting from large vessel disease. *J Neurol*. 2000; 247: 280-5.
27. Adachi T, Kobayashi S and Yamaguchi S. Frequency and pathogenesis of silent subcortical brain infarction in acute first-ever ischemic stroke. *Internal medicine (Tokyo, Japan)*. 2002; 41: 103-8.
28. Aigner M, Zitterl W, Prayer D, et al. Magnetic resonance imaging in patients with obsessive-compulsive disorder with good versus poor insight. *Psychiatry research*. 2005; 140: 173-9.
29. Akiguchi I, Shirakashi Y, Budka H, et al. Disproportionate subarachnoid space hydrocephalus-outcome and perivascular space. *Annals of clinical and translational neurology*. 2014; 1: 562-9.
30. Al-Saeed O, Athyal R, Ismail M and Sheikh M. Significance of Virchow-Robin spaces in patients newly diagnosed with multiple sclerosis: a case-control study in an Arab population. *Medical principles and practice : international journal of the Kuwait University, Health Science Centre*. 2012; 21: 447-51.
31. Alqahtani E, Huisman TA, Boltshauser E, et al. Mucopolysaccharidoses type I and II: new neuroimaging findings in the cerebellum. *European journal of paediatric neurology : EJPN : official journal of the European Paediatric Neurology Society*. 2014; 18: 211-7.
32. Anlar B, Gocmen R, Serdaroglu E, Konuskan B and Yalnizoglu D. P134 – 2952: Magnetic resonance imaging findings in pediatric tuberous sclerosis patients. *European Journal of Paediatric Neurology*. 2015; 19: S131.
33. Aribisala BS, Wiseman S, Morris Z, et al. Circulating Inflammatory Markers Are Associated With Magnetic Resonance Imaging-Visible Perivascular Spaces But Not Directly With White Matter Hyperintensities. *Stroke*. 2014; 45: 605-7.
34. Azevedo AC, Artigas O, Vedolin L, et al. Brain magnetic resonance imaging findings in patients with mucopolysaccharidosis VI. *Journal of inherited metabolic disease*. 2013; 36: 357-62.

35. Beak HW, Choi HJ, Byun MS, et al. Prevalence of enlarged perivascular spaces in a memory clinic population. *Alzheimer's & Dementia: The Journal of the Alzheimer's Association*. 2015; 11: P146.
36. Berezuk C, Ramirez J, Gao F, Scott CJM and Huroy M. Virchow-Robin Spaces : Correlations with Polysomnography-Derived Sleep Parameters. *Sleep*. 2015; 38: 853-8.
37. Patankar TF, Mitra D, Varma A, Snowden J, Neary D and Jackson A. Dilatation of the Virchow-Robin space is a sensitive indicator of cerebral microvascular disease: study in elderly patients with dementia. *AJNR Am J Neuroradiol*. 2005; 26: 1512-20.
38. Doubal FN, MacLulich AMJ, Ferguson KJ, Dennis MS and Wardlaw JM. Enlarged Perivascular Spaces on MRI Are a Feature of Cerebral Small Vessel Disease. *Stroke*. 2010; 41.
39. Biedroń A, Steczkowska M, Kubik A and Kaciński M. Dilatation of Virchow–Robin spaces in children hospitalized at pediatric neurology department. *Neurologia i Neurochirurgia Polska*. 2014; 48: 39-44.
40. Boddaert N, Zilbovicius M, Philippe A, et al. MRI Findings in 77 Children with Non-Syndromic Autistic Disorder. *PLOS ONE*. 2009; 4: e4415.
41. Bouvy WH, Zwanenburg JJM, Reinink R, et al. Perivascular spaces on 7 Tesla brain MRI are related to markers of small vessel disease but not to age or cardiovascular risk factors. *Journal of Cerebral Blood Flow & Metabolism*. 2016; 36: 1708-17.
42. Adams HHH, Cavalieri M, Verhaaren BFJ, et al. Rating method for dilated Virchow-Robin spaces on magnetic resonance imaging. *Stroke*. 2013; 44: 1732-5.
43. Boxerman JL, Hawash K, Bali B, Clarke T, Rogg J and Pal DK. Is Rolandic epilepsy associated with abnormal findings on cranial MRI? *Epilepsy research*. 2007; 75: 180-5.
44. Calleja Gero ML, Gonzalez Gutierrez-Solana L, Lopez Marin L, Lopez Pino MA, Fournier Del Castillo C and Duat Rodriguez A. Neuroimaging findings in patient series with mucopolysaccharidosis. *Neurologia (Barcelona, Spain)*. 2012; 27: 407-13.
45. Charidimou A, Hong YT, Jager HR, et al. White matter perivascular spaces on magnetic resonance imaging: marker of cerebrovascular amyloid burden? *Stroke*. 2015; 46: 1707-9.
46. Charidimou A, Martinez-Ramirez S, Reijmer YD, et al. Total Magnetic Resonance Imaging Burden of Small Vessel Disease in Cerebral Amyloid Angiopathy: An Imaging-Pathologic Study of Concept Validation. *JAMA neurology*. 2016; 73: 994-1001.
47. Chen W, Song X and Zhang Y. Assessment of the Virchow-Robin Spaces in Alzheimer disease, mild cognitive impairment, and normal aging, using high-field MR imaging. *AJNR Am J Neuroradiol*. 2011; 32: 1490-5.
48. Cheng YC, Ling JF, Chang FC, et al. Radiological manifestations of cryptococcal infection in central nervous system. *Journal of the Chinese Medical Association : JCMSA*. 2003; 66: 19-26.
49. Conforti R, Cirillo M, Saturnino PP, et al. Dilated Virchow-Robin spaces and multiple sclerosis: 3 T magnetic resonance study. *La Radiologia medica*. 2014; 119: 408-14.
50. Conforti R, Cirillo M, Sardaro A, et al. Dilated perivascular spaces and fatigue: is there a link? Magnetic resonance retrospective 3Tesla study. *Neuroradiology*. 2016; 58: 859-66.
51. Cumurciuc R, Guichard JP, Reizine D, Gray F, Bousser MG and Chabriat H. Dilatation of Virchow-Robin spaces in CADASIL. *Eur J Neurol*. 2006; 13: 187-90.
52. Davila G, Berthier ML, Kulisevsky J, et al. Structural abnormalities in the substantia nigra and neighbouring nuclei in Tourette's syndrome. *Journal of neural transmission (Vienna, Austria : 1996)*. 2010; 117: 481-8.

53. Di Costanzo A, Di Salle F, Santoro L, Bonavita V and Tedeschi G. Dilated Virchow-Robin spaces in myotonic dystrophy: frequency, extent and significance. *European neurology*. 2001; 46: 131-9.
54. Di Costanzo A, Di Salle F, Santoro L, Tessitore A, Bonavita V and Tedeschi G. Pattern and significance of white matter abnormalities in myotonic dystrophy type 1: an MRI study. *J Neurol*. 2002; 249: 1175-82.
55. Field TS, Pearce L, Doubal F, et al. Abstract WP166: Prediction of Recurrent Stroke in Lacunar Stroke Patients: Performance of the Small Vessel Disease (SVD) Score in the SPS3 Trial. *Stroke*. 2016; 47: AWP166-AWP.
56. Foo H, Mak E, Yong TT, et al. Progression of small vessel disease correlates with cortical thinning in Parkinson's disease. *Parkinsonism & related disorders*. 2016; 31: 34-40.
57. Groeschel S, Brockmann K and Hanefeld F. Virchow-Robin spaces on magnetic resonance images of children with adrenoleukodystrophy. *European journal of paediatric neurology : EJPN : official journal of the European Paediatric Neurology Society*. 2007; 11: 142-5.
58. Guo L-y, Liu L-l, Liu Y, et al. Characteristics and outcomes of cryptococcal meningitis in HIV seronegative children in Beijing, China, 2002–2013. *BMC Infectious Diseases*. 2016; 16: 635-.
59. Gutierrez J, Rundek T, Ekind MSV, Sacco RL and Wright CB. Perivascular Spaces Are Associated with Atherosclerosis: An Insight from the Northern Manhattan Study. *American Journal of Neuroradiology*. 2013; 34: 1711-6.
60. Gutierrez J, Ekind MSV, Dong C, et al. Brain Perivascular Spaces as Biomarkers of Vascular Risk: Results from the Northern Manhattan Study. *AJNR Am J Neuroradiol*. 2017; 38: 862-7.
61. Hansen TP, Cain J, Thomas O and Jackson A. Dilated perivascular spaces in the Basal Ganglia are a biomarker of small-vessel disease in a very elderly population with dementia. *AJNR Am J Neuroradiol*. 2015; 36: 893-8.
62. Hasiloglu ZI, Albayram S, Selcuk H, et al. Cerebral microhemorrhages detected by susceptibility-weighted imaging in amateur boxers. *AJNR Am J Neuroradiol*. 2011; 32: 99-102.
63. Hayashi N, Tsutsumi Y and Barkovich AJ. Polymicrogyria without porencephaly/schizencephaly. MRI analysis of the spectrum and the prevalence of macroscopic findings in the clinical population. *Neuroradiology*. 2002; 44: 647-55.
64. Huijts M, Duits A, van Oostenbrugge RJ, Kroon AA, de Leeuw PW and Staals J. Accumulation of MRI Markers of Cerebral Small Vessel Disease is Associated with Decreased Cognitive Function. A Study in First-Ever Lacunar Stroke and Hypertensive Patients. *Front Aging Neurosci*. 2013; 5: 72.
65. Husoy AK, Indergaard MK, Honningsvag L-M, et al. Perivascular spaces and headache: A population-based imaging study (HUNT-MRI). *Cephalalgia : an international journal of headache*. 2016; 36: 232-9.
66. Inglese M, Grossman RI, Diller L, et al. Clinical significance of dilated Virchow-Robin spaces in mild traumatic brain injury. *Brain Injury*. 2006; 20: 15-21.
67. Kilsdonk ID, Steenwijk MD, Pouwels PJ, et al. Perivascular spaces in MS patients at 7 Tesla MRI: a marker of neurodegeneration? *Multiple sclerosis (Houndmills, Basingstoke, England)*. 2015; 21: 155-62.

68. Koo HW, Jo KI, Yeon JY, Kim JS and Hong SC. Clinical features of high-degree centrum semiovale-perivascular spaces in cerebral amyloid angiopathy. *J Neurol Sci.* 2016; 367: 89-94.
69. Lauer A, van Veluw SJ, William CM, et al. Microbleeds on MRI are associated with microinfarcts on autopsy in cerebral amyloid angiopathy. *Neurology.* 2016; 87: 1488-92.
70. Lee D, Hong IK and Ahn TB. Dilated Virchow-Robin Space and Dopamine Transporter Imaging in the Striatum of Patients with Parkinsonism. *The Canadian journal of neurological sciences Le journal canadien des sciences neurologiques.* 2015; 42: 248-54.
71. Loyse A, Moodley A, Rich P, et al. Neurological, visual, and MRI brain scan findings in 87 South African patients with HIV-associated cryptococcal meningoencephalitis. *The Journal of infection.* 2015; 70: 668-75.
72. MacLulich AMJ, Wardlaw JM, Ferguson KJ, Starr JM, Seckl JR and Deary IJ. Enlarged perivascular spaces are associated with cognitive function in healthy elderly men. *J Neurol Neurosurg Psychiatry.* 2004; 75: 1519-23.
73. Manara R, Priante E, Grimaldi M, et al. Closed Meningo(encephalo)cele: a new feature in Hunter syndrome. *AJNR Am J Neuroradiol.* 2012; 33: 873-7.
74. Matheus MG, Castillo M, Smith JK, Armao D, Towle D and Muenzer J. Brain MRI findings in patients with mucopolysaccharidosis types I and II and mild clinical presentation. *Neuroradiology.* 2004; 46: 666-72.
75. Mendes CS, Rand MH, Curiati MA, Feliciano P, Aranda CS and Martins AM. SSIEM 2015 Annual Symposium : Neuroimaging findings and cerebrospinal fluid flow study using MR imaging in patients with Mucopolysaccharidosis (MPS). *Journal of inherited metabolic disease.* 2015; 38 Suppl 1: S261.
76. Mercieca K, Cain J, Hansen T, et al. Primary Open Angle Glaucoma is Associated with MR Biomarkers of Cerebral Small Vessel Disease. *Sci Rep.* 2016; 6: 22160.
77. Miskiel KA, Hall-Craggs MA, Miller RF, et al. The spectrum of MRI findings in CNS cryptococcosis in AIDS. *Clinical radiology.* 1996; 51: 842-50.
78. Muir R, Edwards JD, Berezuk C, et al. Regional relationships between enlarged perivascular spaces, white matter hyperintensities and cognitive impairment. *Alzheimer's & Dementia: The Journal of the Alzheimer's Association.* 2016; 12: P225-P6.
79. Mutlu U, Adams HH, Hofman A, et al. Retinal Microvascular Calibers Are Associated With Enlarged Perivascular Spaces in the Brain. *Stroke.* 2016; 47: 1374-6.
80. Park AY, Chung TS, Suh SH, Choi HS and Lee YH. Asymmetric dilatation of virchow-robin space in unilateral internal carotid artery steno-occlusive disease. *Journal of computer assisted tomography.* 2011; 35: 298-302.
81. Parker J, Wolansky LJ, Khatry D, Geba GP and Molfino NA. Brain magnetic resonance imaging in adults with asthma. *Contemporary clinical trials.* 2011; 32: 86-9.
82. Prayer D, Grois N, Prosch H, Gadner H and Barkovich AJ. MR imaging presentation of intracranial disease associated with Langerhans cell histiocytosis. *AJNR Am J Neuroradiol.* 2004; 25: 880-91.
83. Ramirez J, Berezuk C, McNeely AA, Scott CJ, Gao F and Black SE. Visible Virchow-Robin spaces on magnetic resonance imaging of Alzheimer's disease patients and normal elderly from the Sunnysbrook Dementia Study. *J Alzheimers Dis.* 2015; 43: 415-24.
84. Sahin N, Solak A, Genc B and Akpınar MB. Dilatation of the Virchow-Robin spaces as an indicator of unilateral carotid artery stenosis: correlation with white matter lesions. *Acta radiologica (Stockholm, Sweden : 1987).* 2015; 56: 852-9.

85. Schick S, Gahleitner A, Wober-Bingol C, et al. Virchow-Robin spaces in childhood migraine. *Neuroradiology*. 1999; 41: 283-7.
86. Schwedt TJ, Guo Y and Rothner AD. "Benign" imaging abnormalities in children and adolescents with headache. *Headache*. 2006; 46: 387-98.
87. Selvarajah J, Scott M, Stivaros S, et al. Potential surrogate markers of cerebral microvascular angiopathy in asymptomatic subjects at risk of stroke. *Eur Radiol*. 2009; 19: 1011-8.
88. Song T-J, Chang Y, Shin M-J, Heo JH and Kim Y-J. Low levels of plasma omega 3-polyunsaturated fatty acids are associated with cerebral small vessel diseases in acute ischemic stroke patients. *Nutrition research (New York, NY)*. 2015; 35: 368-74.
89. Song TJ, Park JH, Choi KH, et al. Moderate-to-severe obstructive sleep apnea is associated with cerebral small vessel disease. *Sleep Med*. 2017; 30: 36-42.
90. Song TJ, Kim YD, Yoo J, et al. Association between Aortic Atheroma and Cerebral Small Vessel Disease in Patients with Ischemic Stroke. *Journal of stroke*. 2016; 18: 312-20.
91. Sun W, Huang ZX, Duan ZW, Xiao LL and Liu XF. Relations of serum soluble E-selectin and adiponectin with enlarged perivascular spaces in patients with recent lacunar infarction. *CNS neuroscience & therapeutics*. 2014; 20: 382-4.
92. Taber KH, Shaw JB, Loveland KA, Pearson DA, Lane DM and Hayman LA. Accentuated Virchow-Robin spaces in the centrum semiovale in children with autistic disorder. *Journal of computer assisted tomography*. 2004; 28: 263-8.
93. Tarnaris A, Toma AK, Pullen E, et al. Cognitive, biochemical, and imaging profile of patients suffering from idiopathic normal pressure hydrocephalus. *Alzheimer's & dementia : the journal of the Alzheimer's Association*. 2011; 7: 501-8.
94. Tan Z-R, Long X-Y, Li G-L, Zhou J-X and Long L. Spectrum of neuroimaging findings in cryptococcal meningitis in immunocompetent patients in China — A series of 18 cases. *Journal of the Neurological Sciences*. 2016; 368: 132-7.
95. Thanprasertsuk S, Martinez-Ramirez S, Pontes-Neto OM, et al. Posterior white matter disease distribution as a predictor of amyloid angiopathy. *Neurology*. 2014; 83: 794-800.
96. Tien RD, Chu PK, Hesselink JR, Duberg A and Wiley C. Intracranial cryptococcosis in immunocompromised patients: CT and MR findings in 29 cases. *AJNR Am J Neuroradiol*. 1991; 12: 283-9.
97. Tokola AM, Aberg LE and Autti TH. Brain MRI findings in aspartylglucosaminuria. *Journal of neuroradiology Journal de neuroradiologie*. 2015; 42: 345-57.
98. Uiterwijk R, van Oostenbrugge RJ, Huijts M, De Leeuw PW, Kroon AA and Staals J. Total Cerebral Small Vessel Disease MRI Score Is Associated with Cognitive Decline in Executive Function in Patients with Hypertension. *Frontiers in aging neuroscience*. 2016; 8: 301-.
99. Valtonen M, Nanto-Salonen K, Jaaskelainen S, et al. Central nervous system involvement in gyrate atrophy of the choroid and retina with hyperornithinaemia. *Journal of inherited metabolic disease*. 1999; 22: 855-66.
100. van der Land V, Zwanenburg JJ, Fijnvandraat K, et al. Cerebral lesions on 7 tesla MRI in patients with sickle cell anemia. *Cerebrovasc Dis*. 2015; 39: 181-9.
101. van Rooden S, van Opstal AM, Labadie G, et al. Early Magnetic Resonance Imaging and Cognitive Markers of Hereditary Cerebral Amyloid Angiopathy. *Stroke*. 2016; 47: 3041-4.

102. van Sloten TT, Sigurdsson S, van Buchem MA, et al. Cerebral Small Vessel Disease and Association With Higher Incidence of Depressive Symptoms in a General Elderly Population: The AGES-Reykjavik Study. *The American journal of psychiatry*. 2015; 172: 570-8.
103. van Sloten TT, Mitchell GF, Sigurdsson S, et al. Associations between arterial stiffness, depressive symptoms and cerebral small vessel disease: cross-sectional findings from the AGES-Reykjavik Study. *Journal of Psychiatry & Neuroscience : JPN*. 2016; 41: 162-8.
104. Vanderver A, Tonduti D, Kahn I, et al. Characteristic brain magnetic resonance imaging pattern in patients with macrocephaly and PTEN mutations. *American journal of medical genetics Part A*. 2014; 164a: 627-33.
105. Vilar-Bergua A, Riba-Llena I, Ramos N, et al. Microalbuminuria and the Combination of MRI Markers of Cerebral Small Vessel Disease. *Cerebrovasc Dis*. 2016; 42: 66-72.
106. Vilar-Bergua A, Riba-Llena I, Penalba A, et al. N-terminal pro-brain natriuretic peptide and subclinical brain small vessel disease. *Neurology*. 2016; 87: 2533-9.
107. Wang X, Valdés Hernández MdC, Doubal F, et al. Development and initial evaluation of a semi-automatic approach to assess perivascular spaces on conventional magnetic resonance images. *Journal of Neuroscience Methods*. 2016; 257: 34-44.
108. Wardlaw JM, Doubal F, Armitage P, et al. Lacunar stroke is associated with diffuse blood-brain barrier dysfunction. *Ann Neurol*. 2009; 65: 194-202.
109. Wardlaw JM, Aribisala BS, Morris Z, et al. Relationships between plasma inflammatory markers, perivascular spaces and white matter hyperintensities. *Cerebrovasc Dis*. 2013; 35: 69.
110. Wiseman SJ, Bastin ME, Jardine CL, et al. Cerebral Small Vessel Disease Burden Is Increased in Systemic Lupus Erythematosus. *Stroke*. 2016; 47: 2722-8.
111. Wuerfel J, Haertle M, Waiczies H, et al. Perivascular spaces--MRI marker of inflammatory activity in the brain? *Brain*. 2008; 131: 2332-40.
112. Xiao L, Lan W, Sun W, et al. Chronic Kidney Disease in Patients With Lacunar Stroke. *Stroke*. 2015; 46: 2081-6.
113. Yun YH. The number of dilated perivascular spaces: Hallmarks of mild cognitive impairment? *Alzheimer's & Dementia*. 2013; 9: P407.
114. Zeegers M, Van Der Grond J, Durston S, et al. Radiological findings in autistic and developmentally delayed children. *Brain & development*. 2006; 28: 495-9.
115. Zhang X, Tang Y, Xie Y, et al. Total magnetic resonance imaging burden of cerebral small-vessel disease is associated with post-stroke depression in patients with acute lacunar stroke. *Eur J Neurol*. 2017; 24: 374-80.