

Supplementary Material: Normalization of reduced functional connectivity after revascularization of asymptomatic carotid stenosis

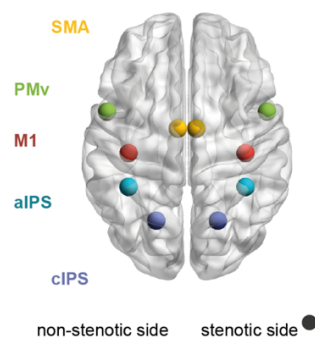
Quandt F.¹, Fischer F.¹, Schröder J.¹, Heinze M.¹, Kessner S. S.¹, Malherbe C.¹, Schulz R.¹, Cheng B.¹, Gerloff C.¹, Fiehler J.², Thomalla G.¹

¹ Department of Neurology, University Medical Center Hamburg–Eppendorf

² Department of Diagnostic and Interventional Neuroradiology, University Medical Center Hamburg–Eppendorf

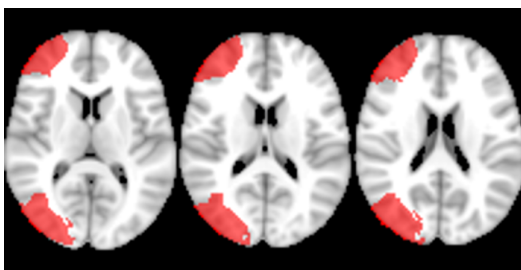
1 Supplementary Material and Methods

Coordinates of Interest of Main Network



Supplementary figure 1. Projections of coordinates of interest on a template MNI brain. In patients with the stenosis on the left side, data were flipped to the right (stenotic side) to allow for a comparison across participants. M1 = primary motor cortex, PMv = ventral premotor cortex, SMA = supplementary motor area, aIPS = anterior part of the intraparietal sulcus, cIPS = caudal part of the intraparietal sulcus

Perfusion Borderzone Maps



Supplementary figure 2. Multi-slice image of middle cerebral artery borderzone used for perfusion analysis in MNI-2 mm space.

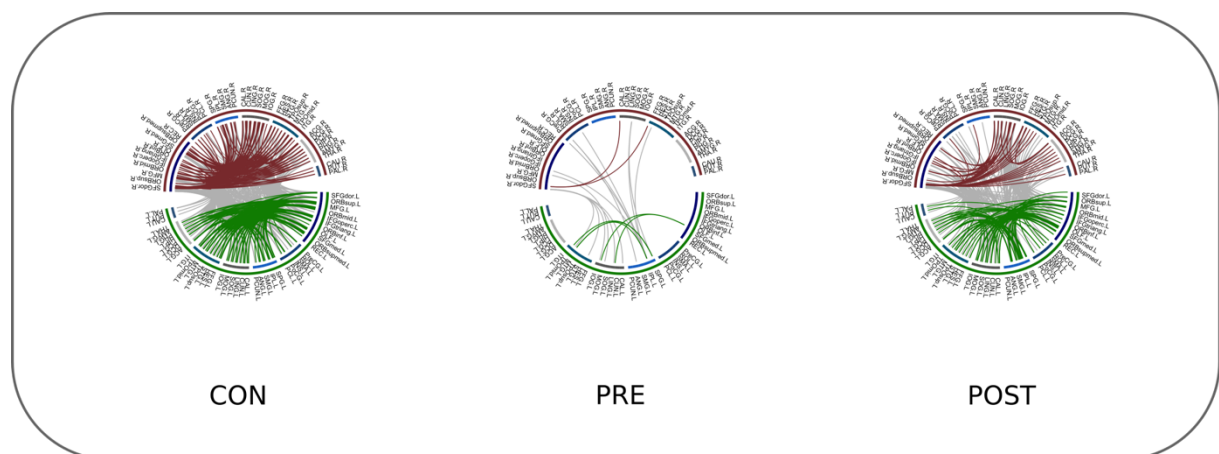
Source Reconstruction of Whole-Brain Connectivity

We computed LCMV beamformer coefficients from time series for each of the voxels on a 6-mm grid covering the brain. These LCMV weights were used for the later projection of complex Fourier spectra into source space. The optimal dipole orientation for each voxel was computed using the SVD approach. We used the AAL atlas to parcellate the template brain into 90 anatomical areas. Subsequently, the imaginary part of the coherence was calculated between all 90 region of interests (ROI) resulting in a 90 x 90 connectivity matrix.

2 Supplementary Results

Whole-Brain Connectivity

We assessed whether a similar pattern of connectivity holds true for a whole-brain connectivity approach. We calculated the imaginary coherence between all 90 AAL regions for controls, patients pre-interventions as well as patients post-intervention. The whole-brain connectivity approach supports our finding that patients with severe stenosis show a global decrease of connectivity compared to controls, whereas connectivity increases again after revascularization resembling the pattern observed in control subjects (supplementary figure 3).



Supplementary figure 3. Global imaginary coherence for controls (CON), patients pre-intervention (PRE) and patients post-intervention (POST). Alpha band imaginary coherence was thresholded at $th = 0.085$. Upper half of circular plot (red rim) depicts regions from right side/stenotic side, lower half (green rim) of left side/non-stenotic side. Inner color rim shows allocation of individual AAL regions to lobes of the brain (frontal, central, parietal, occipital, temporal, insular, subcortical), with blue colors indicating regions that are supplied by the ICA and grey colors indicating regions mostly supplied by the posterior cerebral artery. Red links depict connections on the stenotic side, green links connections on the non-stenotic side, and grey links depict connections interhemispherically.