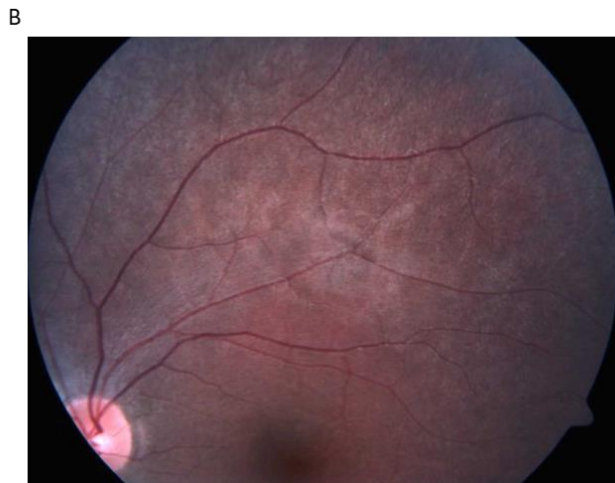
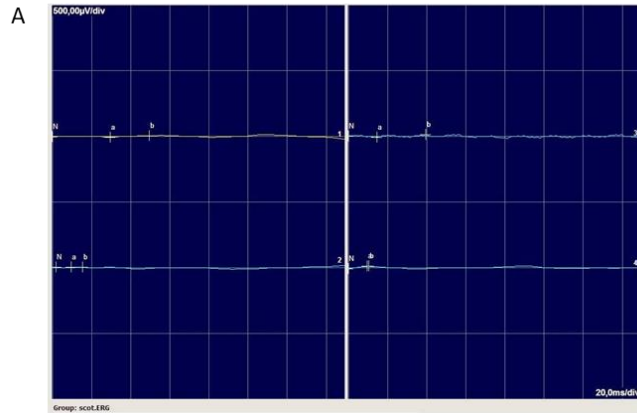


Supplemental material for Glen et al., “A High Prevalence of Biallelic RPE65 Mutations in Costa Rican Children with Leber Congenital Amaurosis and Early Onset Retinal Dystrophy”, *Ophthalmic Genetics*, 2019.

**Supplemental Table 1:** PCR and sequencing Oligos

Oligos	RPE65 Sequence Name	Oligo Sequence
1	RPE65 PCR Exon 3F	cacctgttgatgggcaagc
2	RPE65 PCR Exon 5R	ggctctgtgcaagcgtagt
3	RPE65 Exon 12F	agtttctcaaatcaattaccagaagt
4	RPE65 Exon 13R	tcattcttccaaggcatctg
5	RPE65 Seq Exon 3R	atgttcctcgtatccatgc
6	RPE65 Seq Exon 4F	ccagcttgccacatatgc
7	RPE65 Seq Exon 4R	aacattcagttgggttcagtaacc

Supplemental Figure 1. Representative Clinical Data

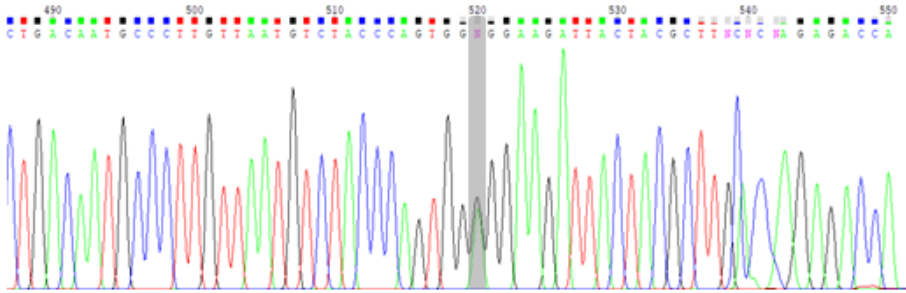


**Supplemental Figure 1:** Representative patient RPCR XVIII-1.

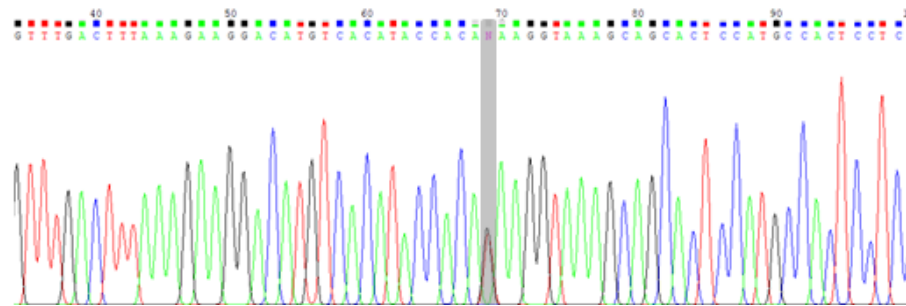
Eight-year-old girl with onset of nystagmus at age 3 months with nyctalopia. A) Electroretinogram (ERG): Extinguished scotopic ERG, right eye. B) Color Fundus Photograph: Mottling of equatorial Retinal Pigment Epithelium (RPE)

## Supplemental Figure 2. Sanger Chromatograms.

A



B



### Supplemental Figure 2: Sanger Chromatograms.

Two novel variants were found in RPE65. These variants were confirmed via sanger sequencing. Provided are representative chromatograms for (A) c.242G>T p.(Arg81Ile) and (B) c.419G>A p.(Gly140Glu).