

# The Characterization of Bovine Pneumonia Using Bacterial Culture, Immunohistochemistry, and PCR

7 MAY 2019  
CORINNE A VAUGHAN

# Table of Contents

1. Introduction.....	2
1.1. Purpose.....	2
1.2. Background.....	2
1.3. Scope.....	3
2. Methods.....	5
2.1. Culture.....	5
2.2. qPCR.....	5
2.3. Immunohistochemistry.....	5
3. Results.....	7
3.1. Culture Results.....	8
3.2. qPCR Results.....	8
3.3. Immunohistochemistry Results.....	9
4. Discussion.....	11
5. References.....	12

# 1 Introduction

This paper is a preliminary investigation of the potential for consistent co-infection of bovine lungs with *Histophilus somni* and *Mycoplasma bovis*. The study used natural cases of pneumonia that had been previously diagnosed at the Wyoming State Veterinary Laboratory in the Department of Veterinary Sciences, University of Wyoming. The investigation used a combination of bacterial culture, immunohistochemistry (IHC), and quantitative polymerase chain reaction (PCR) to establish the presence or absence of these two agent. This project is meant to fulfil the requirements for a Veterinary Science undergraduate research project. It addresses importance of the subject, provides test results, discusses the significance of the laboratory findings, and suggests where research might go from here.

## 1.1 Purpose

This study was designed to better understand one of several complex interactions that occur between two bacterial species that contribute to bovine respiratory disease (BRD) complex. This complex causes heavy annual economic losses in the American cattle industry. The project focused on two recognized BRD bacterial pathogens: *H. somni* and *M. bovis*. The purpose of the study was to establish the frequency with which both agents are found in affected lungs, and, where this occurred, whether they tended to co-localize in lesions.

## 1.2 Background

BRD complex is caused by a limited number of specific bacterial and viral agents, often working in concert. Disease outbreaks are triggered by various factors, such as dust and chronic physiological stress. Various forms of pneumonia exist. In the case of BRD complex, pneumonia is typically an anteroventral exudative bronchopneumonia, either with or without pleuritis.<sup>1</sup> Infection involves pulmonary parenchyma, with progression from the upper to the lower respiratory tract. The most important bacterial agents, ranked in order, are *Mannheimia haemolytica*, *Pasteurella multocida*, *Histophilus somni*, and *Mycoplasma bovis*. The complex BRD complex viral agents are bovine herpesvirus type 1 (BoHV-1), bovine respiratory syncytial virus (BRSV), bovine viral diarrhea virus (BVD), and bovine parainfluenza virus type 3 (PI-3).<sup>1</sup> The typical progression of disease begins with a change in environmental or immune status, often due to transportation or social hierarchy stress. This predisposes the animal to viral infection.

Such infections weaken the natural defenses that protect the lower respiratory tract from bacteria.<sup>2,3</sup> The bacterial agents are generally responsible for severe clinical disease and, in a proportion of cattle, chronic illness or death. The most important agents, and therefore the best understood on the basis of research, are *M. haemolytica* and *P. multocida*.

It is the other two bacterial agents, *H. somni* and *M. bovis*, that form the basis for the current study. Both are less easy to study. *H. somni* is a Gram-negative bacterium of the family *Pasteurellaceae*. It is commonly found in the upper respiratory tract and urogenital mucosa of healthy ruminants. It can be pathogenic in circumstances for which the triggers are only partly understood.<sup>1,2,4</sup> *H. somni* may infect multiple organ systems as a result of septicemia, so clinical signs vary depending on the organ or organs affected. Signs of respiratory infection include fever, depression, tachypnea, cough, and nasal discharge. Lesions resulting from *H. somni* infection include widespread thrombosis (blood clotting) in the wake of bacterial septicemia. This is thought to involve bacterial-induced apoptosis of vascular endothelial cells.<sup>1</sup> These lesions are most evident histologically in lungs, heart and brain. At necropsy, the cranioventral lobes of the lungs are consolidated, with edema and fibrin in interlobular septa.<sup>1,4</sup> *H. somni* is susceptible to multiple antimicrobials. Ideally samples collected for bacterial culture and antibiograms should be from untreated cattle with terminal pneumonia.<sup>1</sup>

*M. bovis* is a small, pleomorphic bacterium surrounded by a single plasma membrane. The absence of a cell wall results in resistance to beta-lactams, an important and widely used class of antimicrobials. Clinical signs of *M. bovis* infection include fever, tachypnea, inappetence, and respiratory distress.<sup>1</sup> The pathogenesis of *M. bovis* infection is only partly understood. It can evade the immune system by interfering with the protective functions of neutrophils, and by producing variable surface proteins.<sup>1,2</sup> As with *H. somni*, lesions caused by *M. bovis* are predominantly found in the cranioventral portions of the lungs. Once lesions are well established, a characteristic gross feature is the presence of 1 – 3 mm white-yellow foci of necrosis.<sup>1</sup> This is considered a hallmark of subacute to chronic pulmonary mycoplasmosis in cattle. Laboratory testing is needed to corroborate that suspicion in outbreaks.

Laboratory recognition of *H. somni* and *M. bovis* is hindered by several factors. *M. bovis* is difficult to grow in culture media that are suitable for *M. haemolytica* and *P. multocida*. Much of the research on *H. somni* has been done in Canada and its application to cattle production systems in the United States is unclear.<sup>4</sup> *H. somni* is a commensal bacterium. That is, it is found on the respiratory and reproductive mucous membranes of healthy cattle. This can complicate the interpretation of laboratory tests, particularly when inadvertent contamination of laboratory samples by a prosector is a consideration.

Outbreaks of BRD complex occur globally.<sup>3</sup> Major economic losses are the result of mortality, lost production, chronic ill thrift among survivors, and treatment costs. BRD is consistently recognized as a leading cause of mortality in cattle under 5 months, and accounts for 16% of all

death loss in adult cattle annually.<sup>5</sup> Few surveys of BRD complex address *H. somni* specifically and, of those that do, few were conducted in the United States.<sup>4</sup>

## 1.2 Scope

This project is composed of 18 cases submitted to the Wyoming State Veterinary Diagnostic Laboratory between 2016 and 2018. All information pertaining to clients and veterinarians was excluded to maintain confidentiality. Cases were chosen after histological examination of lesions in the lungs indicated the presence of *H. somni*.

## 2 Methods

All procedures were conducted at the Wyoming State Veterinary Laboratory in the department of Veterinary Sciences, University of Wyoming. All cases were diagnostic cases submitted to the laboratory between 2016 and 2018. Standard Operating Procedures (SOPs) mandating the handling of samples were followed at all times. Personal protective equipment (PPE) consisting of laboratory coats or scrubs, protective eyewear, and gloves were routinely used.. Samples of lung for investigation were chosen based on laboratory diagnosis of *H. somni* infection.

### 2.1 Culture

Sterile swabs were used on bovine lung samples of interest and plated for isolation on sheep blood agar (BAP) and MacConkey (Mac) agar. One BAP and one Mac plate were incubated at 37°C for 24-48 hours in oxygen. Additionally, one BAP was incubated at 37°C for 24-48 hours in ,10% CO<sub>2</sub> conditions. Isolated colonies of interest were then streaked for isolation on new BAP plates for MALDI-TOF identification and antimicrobial susceptibility testing.

### 2.2 qPCR

Samples for *H. somni* qPCR consisted of formalin fixed paraffin embedded (FFPE) tissues taken from histologically examined sections of lung. Five micron thick curls were collected from the FFPE lung samples and then deparaffinized using xylene and ethanol. DNA was extracted from samples using a commercially available Qiagen kit. Twenty-five uL reactions for qPCR analysis were prepared using Sso Advanced Universal Probes supermix, forward and reverse primers, and nuclease free water. The chromagen probe used in detection was Quasar 705. The qPCR run protocol consisted of a 2 minute incubation at 95°C followed by 40 cycles alternating between 95°C for 15 seconds and 61°C for 30 seconds.

### 2.3 Immunohistochemistry

Preparation for IHC was conducted using reagents and instructions according to Biocare Medical. Briefly, tissues for IHC examination were fixed in a 10% formalin solution for 48 hours. Cross sections of each tissue were then taken and embedded in paraffin wax. Blocks were then cut, and sections of each tissue were placed onto microscope slides. Slides were then deparaffinized in xylene. To declcloak samples, they were placed into 1X retrieval solution and heated to 80°C for 30 minutes. Biocare's background punisher was then applied to act as a

protein block before samples were exposed to the primary antibody and stained with Warp Red chromogen.

### 3 Results

Of the 18 cases selected for this survey, 12 were positive for both *H. somni* and *M. bovis* across all techniques utilized (**Table 1**). IHC was the most sensitive technique for detection of *H. somni*, and was primarily used to recognize *M. bovis* infection.

Case	<i>H. somni</i> culture	<i>H. somni</i> PCR	<i>H. somni</i> IHC	<i>M. bovis</i> PCR	<i>M. bovis</i> IHC
1	NEGATIVE	NEGATIVE	POSITIVE	<b>POSITIVE</b>	<b>POSITIVE</b>
2	NEGATIVE	NEGATIVE	POSITIVE	<b>POSITIVE</b>	<b>POSITIVE</b>
3	POSITIVE	POSITIVE	POSITIVE	NEGATIVE	<b>POSITIVE</b>
4	POSITIVE	POSITIVE	POSITIVE	NEGATIVE	NEGATIVE
5	POSITIVE	POSITIVE	POSITIVE	<b>POSITIVE</b>	<b>POSITIVE</b>
6	POSITIVE	NEGATIVE	POSITIVE	<b>POSITIVE</b>	<b>POSITIVE</b>
7	NEGATIVE	NEGATIVE	POSITIVE	NEGATIVE	<b>POSITIVE</b>
8	POSITIVE	POSITIVE	POSITIVE	NEGATIVE	<b>POSITIVE</b>
9	NEGATIVE	NEGATIVE	POSITIVE	<b>POSITIVE</b>	<b>POSITIVE</b>
10	POSITIVE	NEGATIVE	POSITIVE	NEGATIVE	<b>POSITIVE</b>
11	POSITIVE	POSITIVE	POSITIVE	NEGATIVE	NEGATIVE
12	POSITIVE	POSITIVE	POSITIVE	<b>POSITIVE</b>	NEGATIVE
13	POSITIVE	POSITIVE	POSITIVE	NEGATIVE	<b>POSITIVE</b>
14	POSITIVE	POSITIVE	POSITIVE	NEGATIVE	NEGATIVE
15	POSITIVE	NEGATIVE	POSITIVE	NEGATIVE	NEGATIVE
16	NEGATIVE	NEGATIVE	POSITIVE	NEGATIVE	NEGATIVE
17	POSITIVE	NEGATIVE	POSITIVE	NEGATIVE	<b>POSITIVE</b>
18	POSITIVE	NEGATIVE	POSITIVE	NEGATIVE	NEGATIVE

**Table 1:** Positive and negative results for *H. somni* and *M. bovis*. Cases 7, 15, and 16 did amplify on the qPCR, but the Cq values were above the pre-determined Cq cut off of 35, and were considered negative. As cases were selected for examination after laboratory recognition of *H. somni* infection, only positive *M. bovis* cases are highlighted for comparison. Note that culture is not routinely performed for recognition of *M. bovis*, so no data for this test exists.



### 3.1 Culture Results

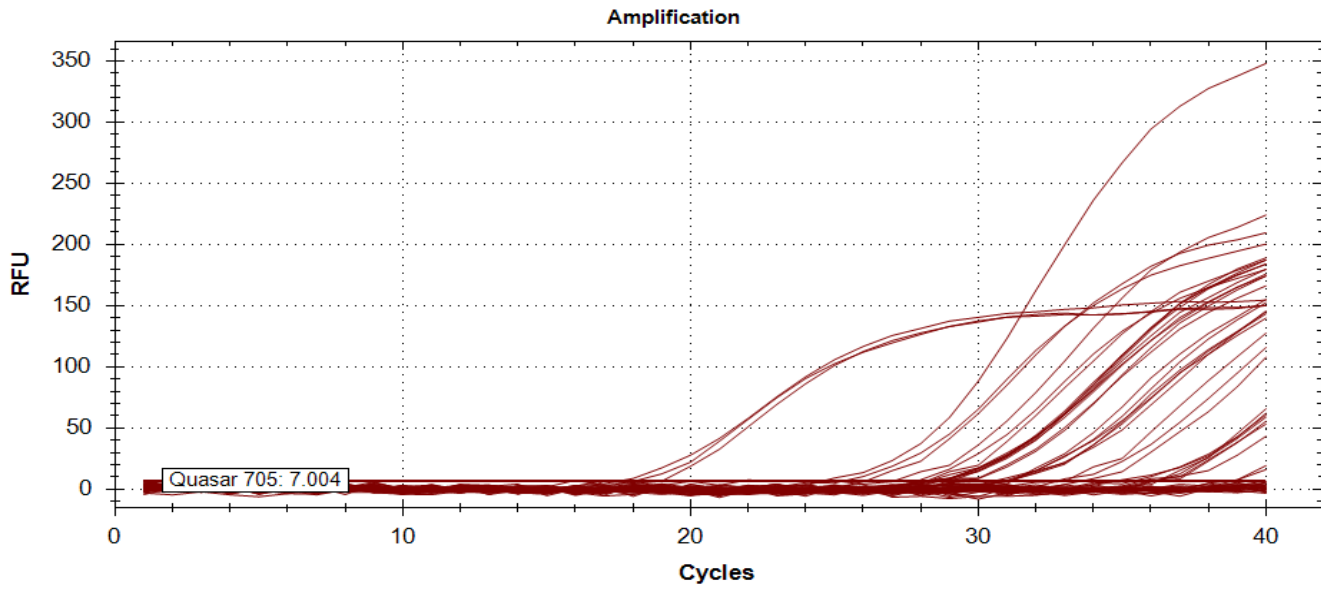
Culture is not routinely practiced for identification of *M. bovis* and no results were recorded for this test, as noted in **Table 1**. Culture results for *H. somni* resulted in 13 total positives out of the 18 chosen cases.

### 3.2 qPCR Results

The *H. somni* qPCR performed on the FFPE tissues resulted in amplification of 8 of the 18 cases (**Table 2**). Results of the *H. somni* qPCR can also be visualized in the curve seen in **Figure 1**. Only 6 of the 18 cases were positive by *M. bovis* qPCR.

Sample	Cq 1	Cq 2	Cq 3	Average Cq
<b>Positive Control</b>	19.02	17.59	18.1	18.40
<b>Negative Control</b>	N/A	N/A	N/A	N/A
<b>1</b>	N/A	N/A	N/A	N/A
<b>2</b>	N/A	N/A	N/A	N/A
<b>3</b>	24.64	25.36	26.11	25.37
<b>4</b>	27.1	27.13	28.23	27.49
<b>5</b>	31.09	31.19	30.91	31.06
<b>6</b>	N/A	N/A	N/A	N/A
<b>7</b>	38.74	38.88	36.12	<b>37.10</b>
<b>8</b>	28.25	28.63	28.32	28.40
<b>9</b>	N/A	N/A	N/A	N/A
<b>10</b>	N/A	N/A	N/A	N/A
<b>11</b>	29.09	28.31	28.53	28.64
<b>12</b>	28.70	28.94	28.32	28.65
<b>13</b>	31.10	31.07	30.58	30.92
<b>14</b>	32.77	33.05	33.63	33.15
<b>15</b>	36.13	35.71	36.17	<b>36.00</b>
<b>16</b>	35.42	34.83	36.26	<b>35.50</b>
<b>17</b>	N/A	N/A	N/A	N/A
<b>18</b>	N/A	N/A	N/A	N/A

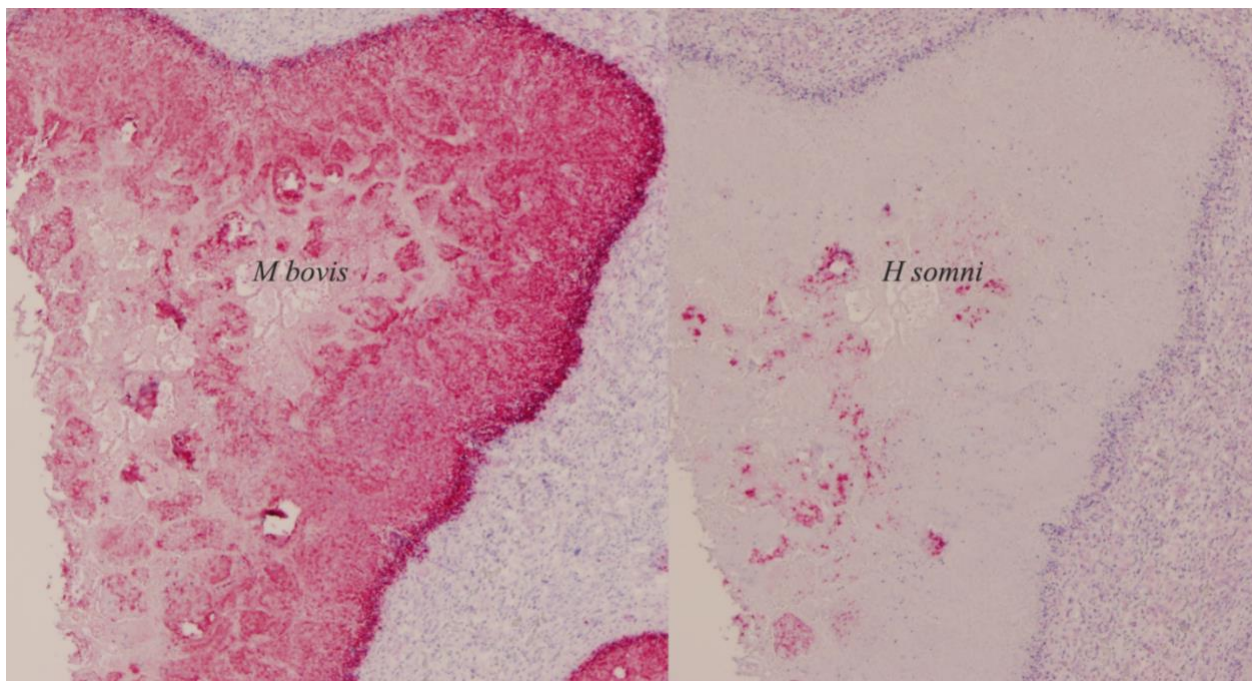
**Table 2:** Table of numerical Cq values for the *H. somni* PCR. Values bolded indicate samples that amplified after the pre-determined limit of 35 cycles for a positive determination. These samples were considered to be negative for the purposes of this investigation.



**Figure 1:** qPCR curve showing amplification of samples containing *H. somni*

### 3.3 Immunohistochemistry Results

The IHC technique, as stated above was the most sensitive in identifying positive cases of both *H. somni* and *M. bovis* infection. The technique was used to identify positive cases of *H. somni* infection for investigation of *M. bovis* detection. As seen in **Table 1**, this yielded 11/18 cases that were positive for both *H. somni* and *M. bovis*. An example of the IHC results can be seen in **Figure 2** below.



**Figure 2:** Comparison of two IHC slides from the same lesion within a bovine lung. **A** *M. bovis*

IHC with proliferative, advancing lesion and necrotic core. **B** *H. somni* IHC with some dispersed colonies at the center of the lesion. The antibody tagged with Warp-red chromagen will bind to either *H. somni* or *M.bovis* and yields a red appearance.

## 4 Discussion

The results indicate that approximately 61% of pneumonias with *H. somni* also contain *M. bovis*. Previous attempts to examine co-infection in cases of BRD found approximately 40% of pneumonias with both *H. somni* and *M. bovis*.<sup>5</sup> The current investigation reports a drastically higher rate of co-infection. This may be due to the use of different identification techniques (PCR versus IHC), or could be a result of the sampling locations (Ireland vs United States). Regardless, the results indicate that there may be a relationship or cooperation between the bacteria in cases of BRD. It also provides evidence of the need for increased screening of *M. bovis* in suspected cases of BRD.

The different techniques used for the identification of the bacteria yielded different levels of detection. Bacterial culture is fundamentally dependent on the existence of living bacteria in the sample tested. Only viable bacteria are capable of growing colonies on media. This makes the technique valuable for detection of current infections and for determination of antimicrobial susceptibility of those species grown. However, previous history of antimicrobial treatment may result in false negative results. Bacterial culture has long been the gold standard for detection of bacterial infections, but PCR is quickly gaining ground. As stated earlier, *M. bovis* is difficult to grow and may be missed using bacterial culture. PCR is both sensitive and specific, and was useful in the detection of *M. bovis* for this investigation. However, PCR testing requires a small sample for testing. In taking a sample for PCR analysis, it is easy to miss sampling areas where bacteria are actively present. This can also result in false negative results, and may have accounted for the error seen in this experiment. IHC techniques also utilize a small sampling area. It is also a specific analysis, and was most successful in the identification of positive cases for this investigation. As seen in **Figure 2**, the technique allows visualization of different bacteria within the same lesion in tissue. This makes it useful for the characterization of lesions infected by multiple bacterial species.

Moving forward, a more thorough investigation of co-infections with *M. bovis* and *H. somni* is warranted. This investigation does not analyze a significant number of cases. However, as a preliminary investigation it does suggest that a majority of *H. somni* infections also contain *M. bovis*. Further development of diagnostic techniques for detection is also necessary to accurately characterize the nature of BRD.

## 5 References

1. Smith, B. P. (Eds.). (2015). Diseases of the Respiratory System. In *Large Animal Internal Medicine* (5<sup>th</sup> ed.) (593-617). St. Louis, MO: Mosby.
2. Panciera, R. J., Confer, A. W. (2010) Pathogenesis and Pathology of Bovine Pneumonia. *Veterinary Clinics of North America: Food Animal Practice*, 26(2), 191-214. (<http://www.sciencedirect.com/science/article/pii/S0749072010000071>)
3. Murray, G. M., More, S. J., Sammin, D., Casey, M. J., McElroy, M. C., O'Neill, R. G., ...Cassidy, J. P. (2017). Pathogens, patterns of pneumonia, and epidemiologic risk factors associated with respiratory disease in recently weaned cattle in Ireland. *Journal of Veterinary Diagnostic Investigation*, 29(1), 20-34.
4. O'Toole, D., Sondgeroth, K. S. (2016). Histophilosis as a natural disease. In *Current Topics in Microbiology and Immunology: Histophilus somni* (Vol. 396). Inzana, T. J. (Eds) (15-48). Switzerland: Springer International Publishing.
5. Bell, C. J., Blackburn, P., Elliott, M., Patterson, T. I. A. P., Ellison, S., Lahuerta-Martin, A., Ball, H. J. (2014). Investigation of polymerase chain reaction assays to improve detection of bacterial involvement in bovine respiratory disease. *Journal of Veterinary Diagnostic Investigation*, 26(5), 631-634.