

Bridging Work - Summer 2021: PHYSICAL EDUCATION (PE)



Exam Board: AQA

Specification: AQA 7582

1. Introduction to the Circulatory System

Using the resource sheets, print out and colour the heart, circulatory and lung diagram using the key provided. The notes will be needed in September for the start of the course.

2. Practical:

Look at the course specification for the practical section. Decide which sport you will compete in for your A-level using this link: <https://www.aqa.org.uk/subjects/physical-education/as-and-a-level/physical-education-7582/scheme-of-assessment>

3. For your chosen sport:

Research an elite performer and complete a skill study which compares your performance in a chosen skill with that of your elite performer. Analyse strengths and weaknesses in the preparation, execution and follow-through stages of the skill. You need only do this for one skill. You should consider using annotated photographs highlighting the differences in performance between you and your elite performer. The completed study should be no more than two sides of A4.

If you have any queries, please contact:

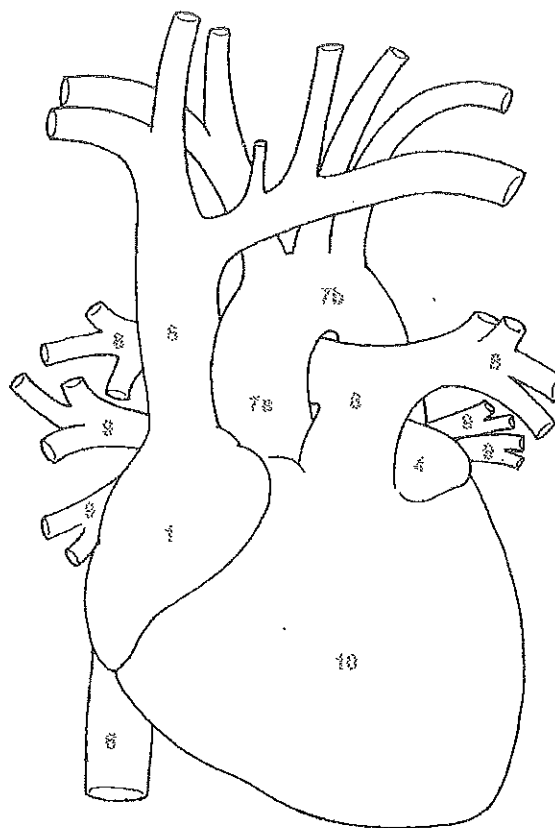
Mrs Jane Lilley Head of PE
jli@herschel.slough.sch.uk

HEART

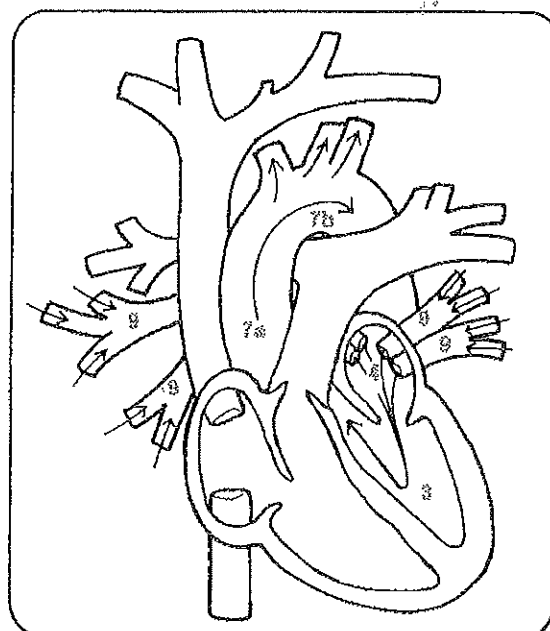
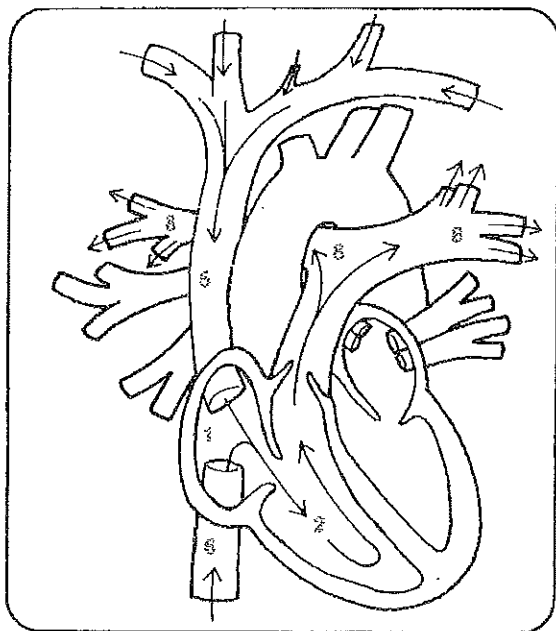
The heart is the key organ of the circulatory system. It is a bit larger than a man's fist — about twelve centimeters long, nine centimeters wide, and six centimeters thick. This hollow muscle is located to the left of the sternum between the second and fifth ribs and is enclosed in the *pericardium*, a membranous sac with a fibrous layer outside and a serous one inside, which protects the heart and anchors it in place. Between the two layers is a watery lubricant that minimizes friction when the heart beats. The heart is surrounded by the lungs, each of which has a notch, the *cardiac impression*, the heart fits into.

Each half of the heart has two chambers, the *atrium* (upper) and the *ventricle* (lower). Blood returning to the heart enters the right atrium from three veins: the *superior vena cava*, which runs from the upper torso and limbs; the *inferior vena cava*, which carries blood from the lower torso and limbs; and the *coronary sinus*, which circulates venous blood from the walls of the heart. The blood is pumped through the *tricuspid valve* (which has three cusps or flaps) into the right ventricle. From there it goes to the *pulmonary artery*, the only artery that carries unoxygenated blood, which carries it to the lungs. In the lungs the blood exchanges carbon dioxide for oxygen. The enriched blood then goes to the left atrium, where it passes through the strong *bicuspid* or *mitral valve* into the left ventricle. Finally the blood leaves the heart through the *aortic semilunar valves* and flows into the *aorta* and through the body.

The heart beats involuntarily, that is, the brain doesn't have to command it to pump blood. Instead various sensors monitor the body's activities and the consequent demands for more or less blood. For example, there are pressure receptors in the aorta that respond to changes in arterial pressure. The *aortic reflex* slows the heart when the pressure gets too high; the *carotid sinus reflex* increases the heart rate when the pressure becomes too low in the arteries that serve the brain. Chemoreceptors increase the heartbeat if they detect a lack of oxygen or an increase of carbon dioxide.



1. RIGHT ATRIUM _____ Light Purple
2. RIGHT VENTRICLE _____ Blue
3. LEFT VENTRICLE _____ Red
4. LEFT ATRIUM _____ Orange
5. SUPERIOR VENA CAVA _____ Light Blue
6. INFERIOR VENA CAVA _____ Dark Blue
7. a. ASCENDING AORTA and b. AORTIC ARCH _____ Pink
8. PULMONARY ARTERY _____ Green
9. PULMONARY VEIN _____ Yellow
10. HEART _____ Purple



PULMONARY CIRCULATION

Pulmonary circulation is the movement of blood from the heart to the air sacs in the lungs and back to the heart. This circulation is necessary for the blood to exchange carbon dioxide for oxygen. The right ventricle of the heart pumps unoxygenated blood into the *pulmonary artery*, which divides in two to form the *right* and *left pulmonary arteries*. The right artery, which supplies the larger lung, the right (which has three lobes), is wider and longer than the left artery (which services the two-lobed left lung). The arteries enter the lungs at the *hilus*, a vertical slit. Then the arteries divide and pass through each lobe. Subdivision follows subdivision until massive capillary beds are formed that surround the *alveoli* or small air sacs. At this point there is only a thin membrane separating each capillary from the air sac. As a blood cell passes down a capillary, carbon dioxide diffuses through the membrane into the alveoli; then oxygen passes from the alveoli to the blood cell. The oxygenated blood moves out of the capillary bed into the increasingly larger pulmonary

veins. These veins unite to form four main trunks (two for each lung) and empty into the left atrium of the heart. The heart then pumps the oxygenated blood on its path through the body.

- | | |
|--|--------------|
| 1. RIGHT ATRIUM | Light Purple |
| 2. RIGHT VENTRICLE | Blue |
| 3. LEFT VENTRICLE | Red |
| 4. LEFT ATRIUM | Orange |
| 5. SUPERIOR VENA CAVA | Light Blue |
| 6. INFERIOR VENA CAVA (opening) | Dark Blue |
| 7. a. ASCENDING AORTA and b. ARCH of AORTA | Pink |
| 8. PULMONARY ARTERY | Green |
| 9. PULMONARY VEIN | Yellow |
| 10. LUNG | Gray |
| 11. HEART | Purple |
| 12. DIAPHRAGM | Brown |
| 13. RIBS | Light Brown |

