

A multidisciplinary digital approach to a complex case

Surgical, aesthetic and occlusal procedure planning for implant-supported full-arch prostheses

Dr Antonio Lipari, Dr Mario Perotti, Marco Marzolla & Dr Valerio Bini, Italy



Fig. 1

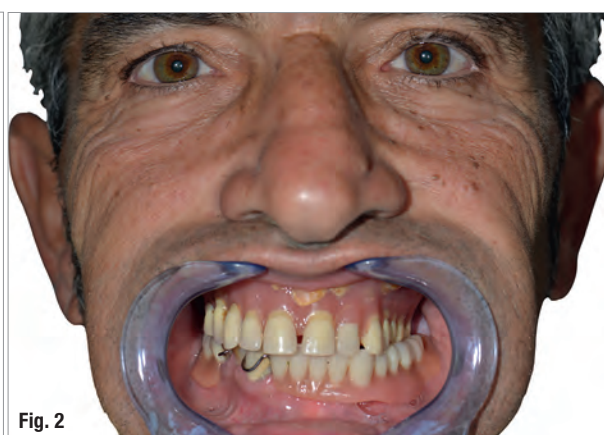

Fig. 2

Introduction

Thanks to digital technology, a growing number of edentulous or partially edentulous patients with residual malocclusion and dysfunction can now be offered a good-quality customised and aesthetically pleasing prosthesis as well as long-term restoration of occlusal function. The surgical planning and execution required to achieve correct occlusion can now be realised with the assistance of a variety of digital tools, with an accuracy that in the past

would have required a great deal of time and resources to achieve. This article reports a digital approach that makes a complex workflow easier to manage and that has the advantage of wider access to high-quality customisation of surgical management and aesthetic and occlusal design.

Case presentation

The case concerns a 58-year-old male patient (Fig. 1) with no relevant medical history. There was clinical evi-

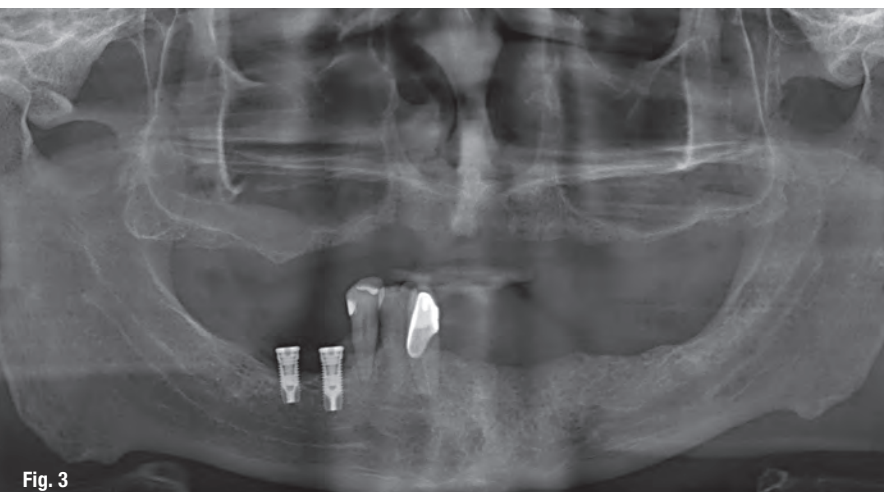


Fig. 3

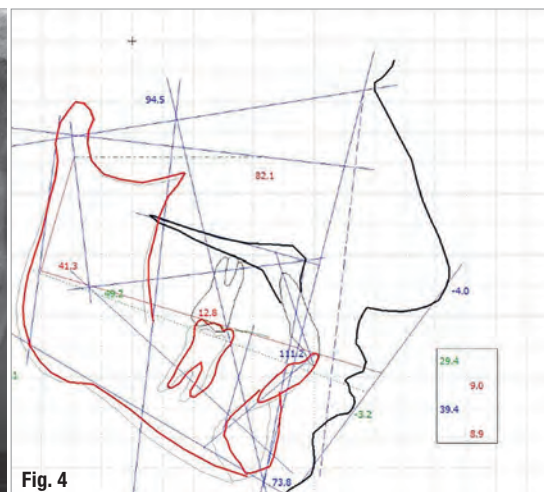
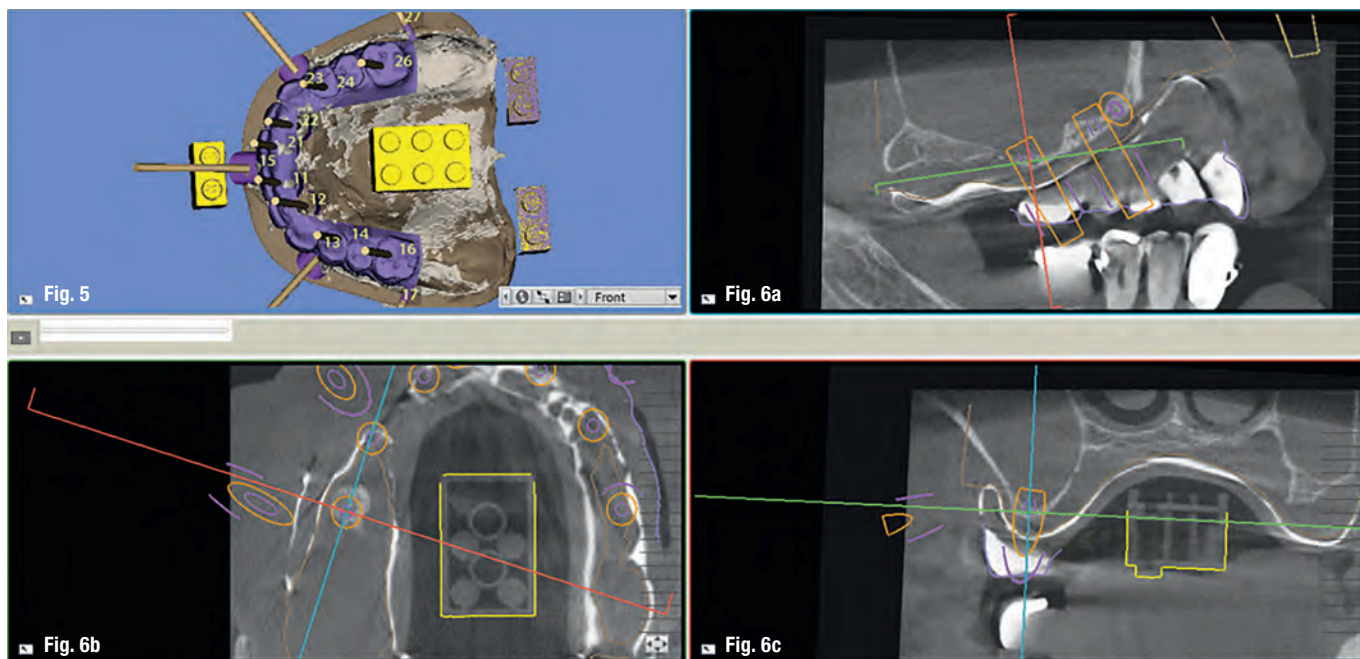


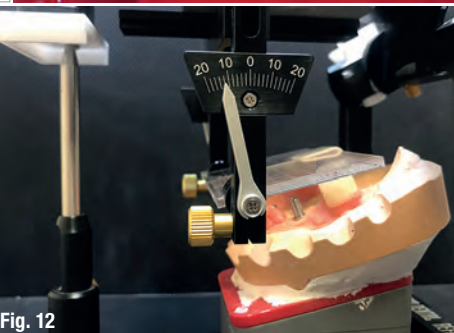
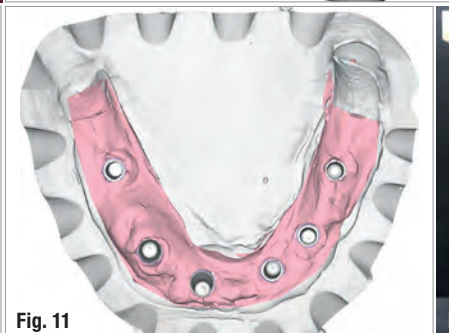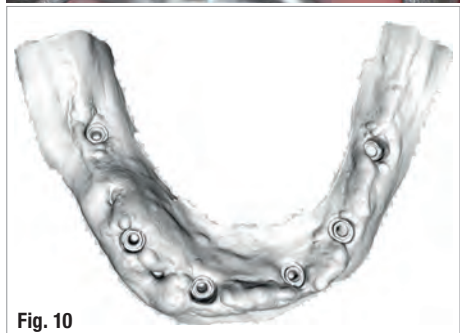
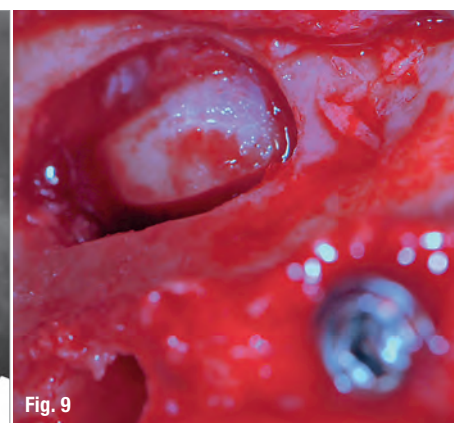
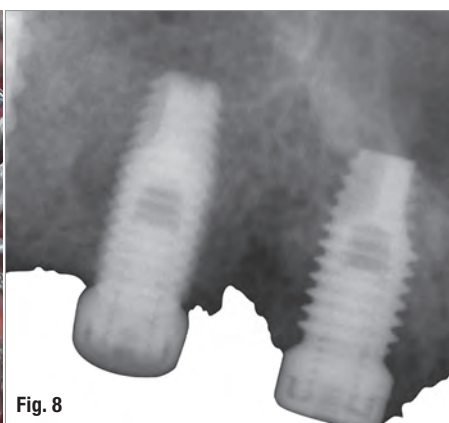
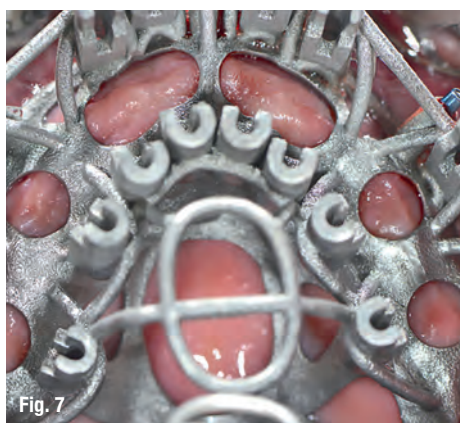
Fig. 4



dence of tooth and bone loss as result of periodontitis and previous poor-quality dental treatment, the use of inappropriate removable dentures with compromised aesthetics, and crossbite malocclusion (Fig. 2) with dysfunctional symptoms. Edentulism and bone loss in the maxillary arch and the presence of three teeth and two implants with a poor periodontal prognosis were evident in the clinical examination and radiographic images (Fig. 3). The patient required fixed maxillary and mandibular implant-supported full-arch prostheses.

After removal of the residual teeth and implants, the patient was fitted with two removable dentures in the reference position, which improved jaw alignment, vertical dimension of occlusion, overbite, overjet, speech and aesthetics.

A cephalometric tracing on a lateral radiograph was done to obtain an initial aesthetic and functional evaluation of the case (Fig. 4), and this was followed by prosthetic and surgical (Fig. 5) planning.



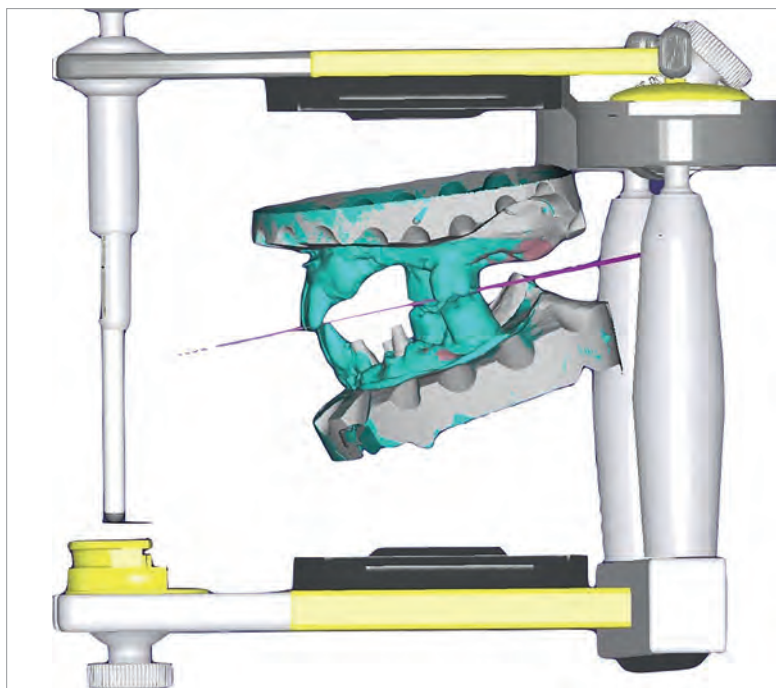


Fig. 13




Fig. 14

The characteristics of the prostheses determined the surgical plan (SMOP, Swissmeda; Figs. 6a–c) and two surgical guides were subsequently laser-sintered (2INGIS), locating both implant positioning and, for the maxillary arch, the bilateral maxillary sinus lift sites. Implants were thus positioned as planned (Figs. 7 & 8), except for those in the posterior maxilla, where maxillary sinus lifts were bilaterally performed (Fig. 9).

After two months, an intra-oral scan (Fig. 10) was taken and the 3D-printed models subsequently obtained were stone-based and re-virtualised (Fig. 11) using a desktop scanner (inEos X5, Dentsply Sirona). Jaw alignment and implant positioning were also accurately recorded by duplicating the interim prostheses and intra-orally fixing the transfer positions on to the copies, whose fit and occlusion had to be

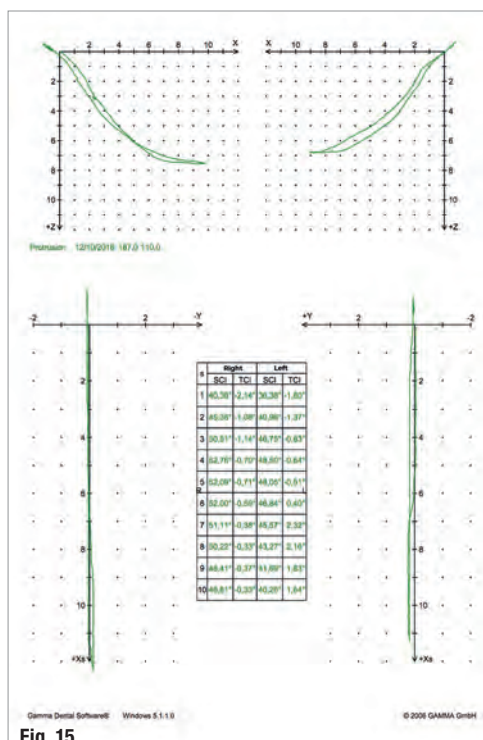


Fig. 15

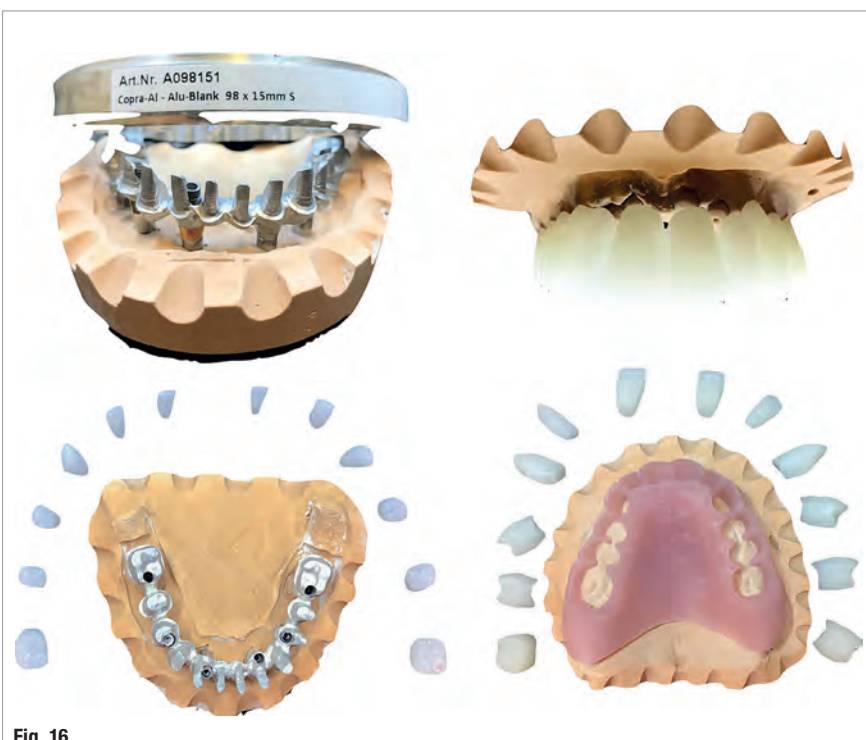
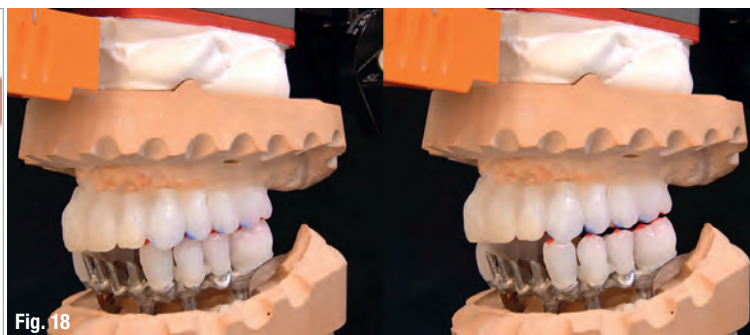
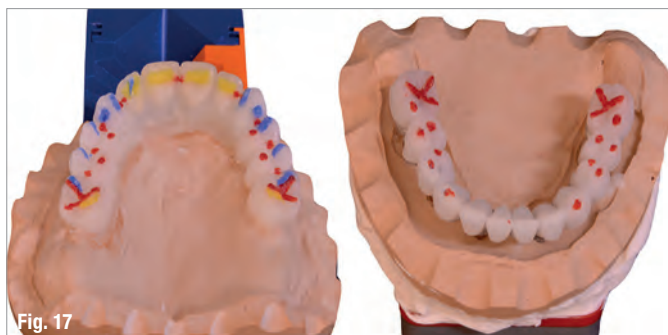
Fig. 16


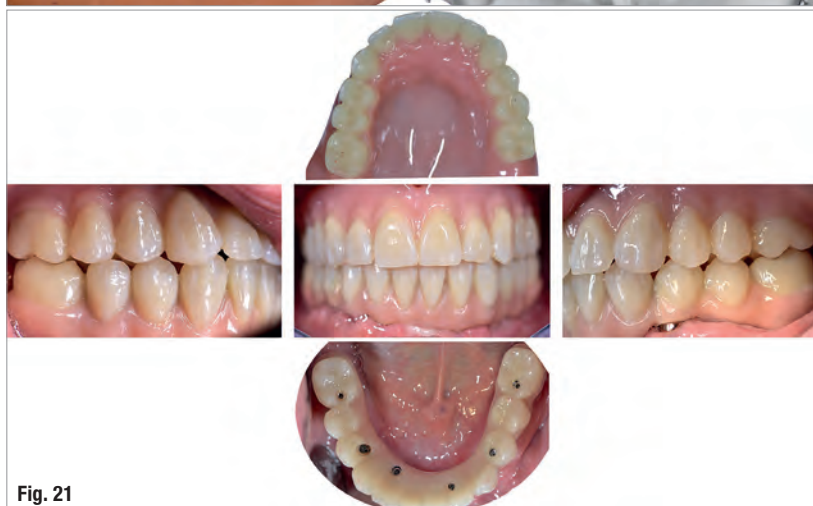
checked for complete accuracy. The jaw relation was used for mounting the casts, which were fixed on mounting blocks with a facebow in a fully adjustable arcon articulator (Reference SL, GAMMA). The central incisors and first molars were assembled bilaterally at an inclination of 12° to the occlusal plane (Fig. 12), which was previously defined using cephalometric tracing.

The teeth were then scanned with a desktop scanner, and using the positions of the central incisor and distal first molar cusps for reference, they were imported in the correct spatial positions into the CAD module (exocadDentalCAD Virtual Articulator, exocad; Fig. 13). Not having a virtual Reference SL articulator

available in the CAD software, a virtual SAM system (SAM Präzisionstechnik) was used, because both the articulators have the same axio-orbital reference plane, and it is possible to superimpose the geometry of the SAM on to the Reference SL. Border movement condylography (CADIAX Compact, GAMMA; Figs. 14 & 15) was also produced for setting the virtual SAM as indicated by the software (CADIAX software, GAMMA), both for the setting of the condylar and incisal guides and for the adjustment of the sagittal condylar inclination and Bennett angles.

The aesthetic digital smile design and the CAD for the patient were therefore done starting with the vir-

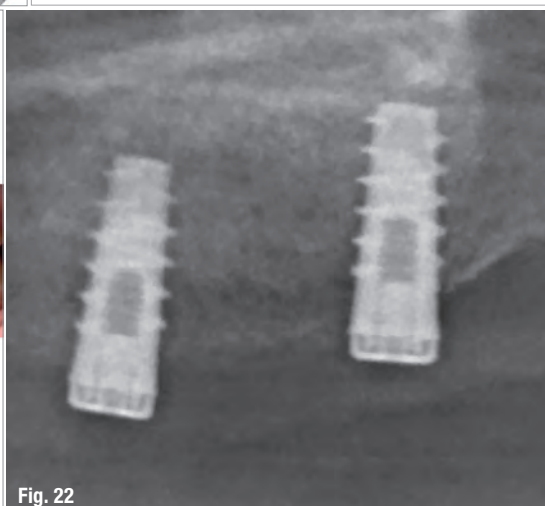
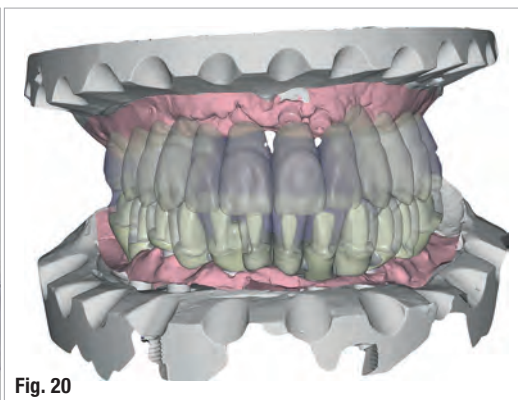
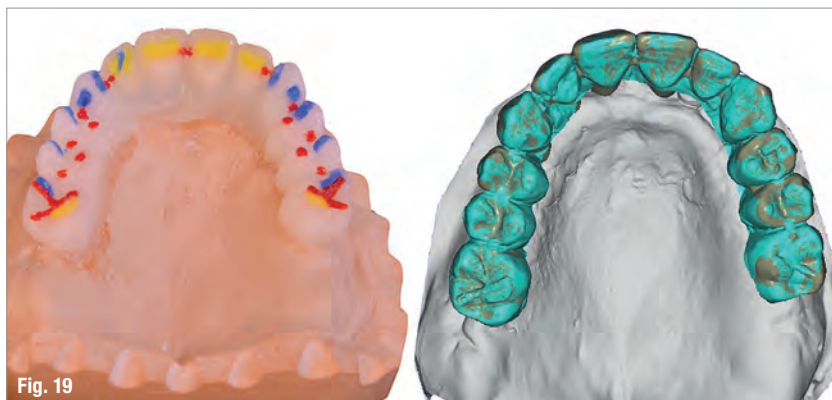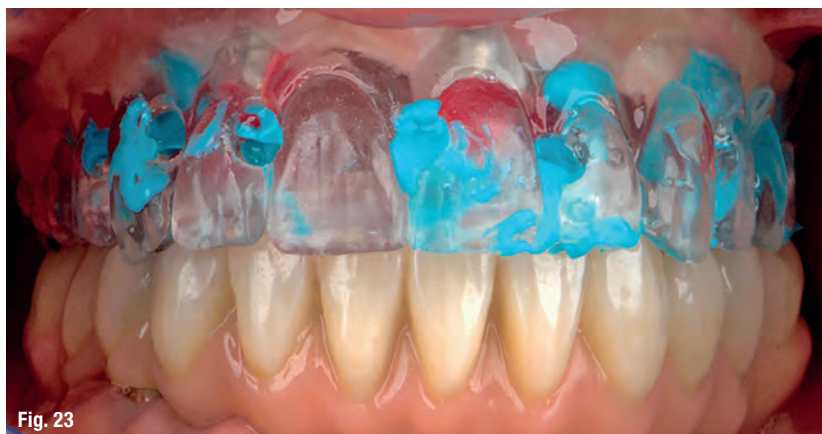




Fig. 23

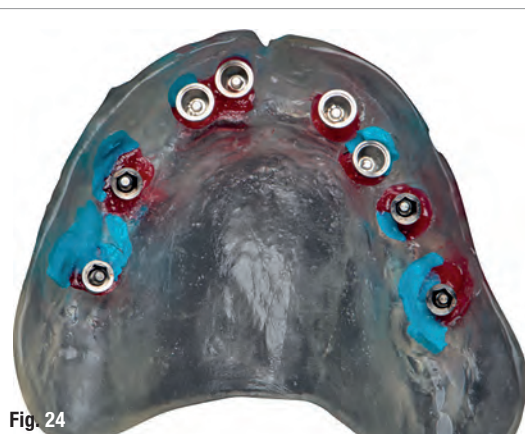

Fig. 24

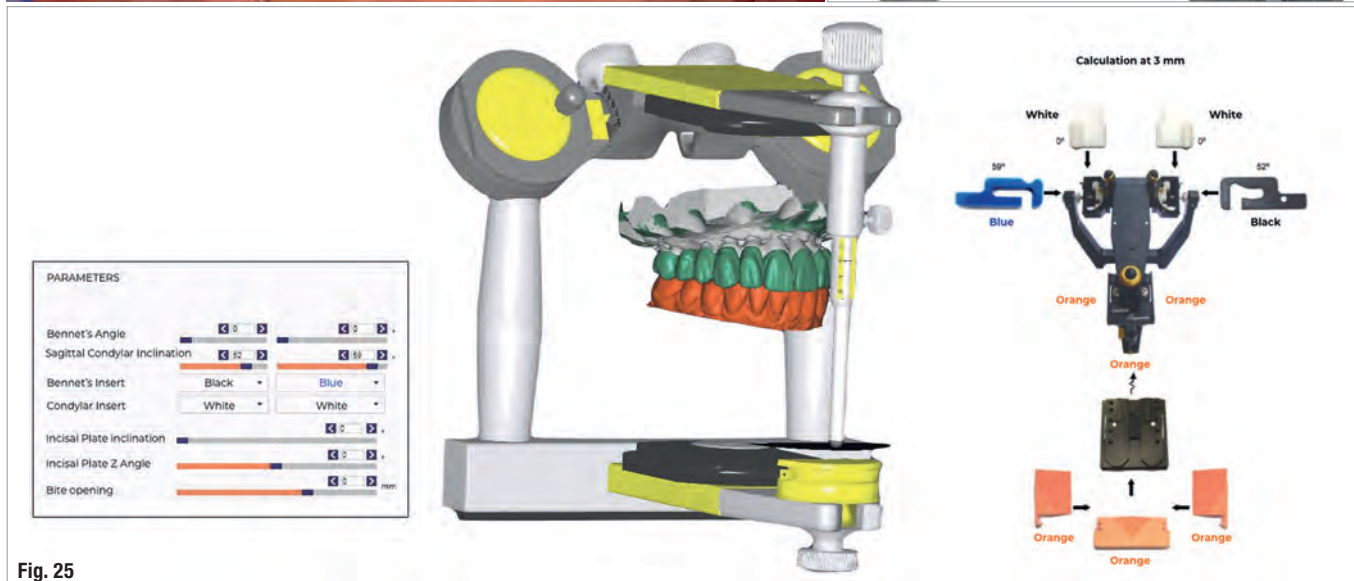


Fig. 25

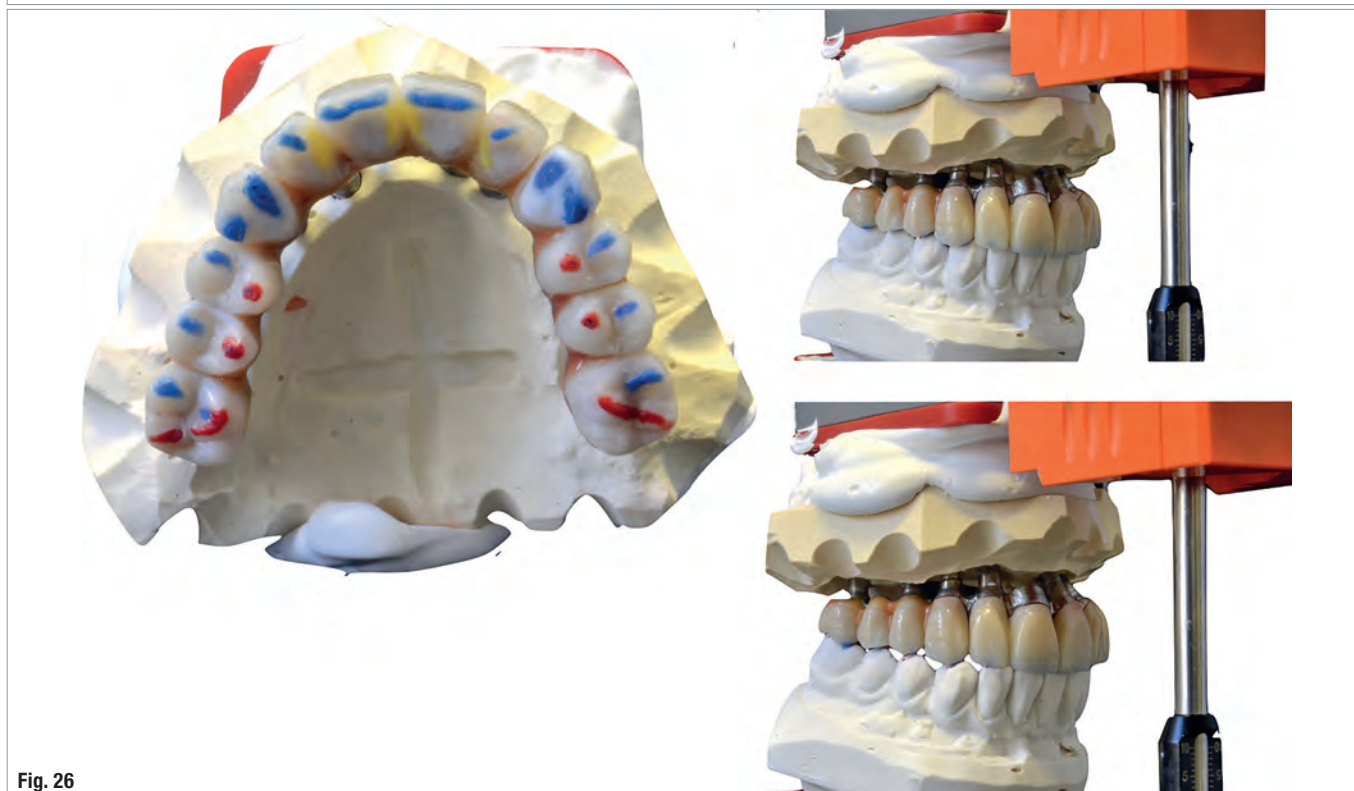


Fig. 26

tual models that defined the new occlusal plane. As the maxillary implants could not be immediately loaded, an aluminium try-in screw-retained meso-structure was CAM-milled for the lower jaw, together with a diagnostic wax-up made with singularly detachable wax teeth (Fig. 16).

The complete wax set-up was then transferred again to the Reference SL articulator. The condylographic output was used for a second programming. The wax set-up was further refined by the dental technician, who accurately shaped the functional surfaces according to the sequential functional occlusal design by Prof. R. Slavicek. Differently coloured waxes highlighted the centric ratios, the mediotrusive and

protrusive tracking functions, and the retrusive protections (Fig. 17). All aspects of occlusion, the functional guides and uniform disclusions were checked (Figs. 18 & 19).

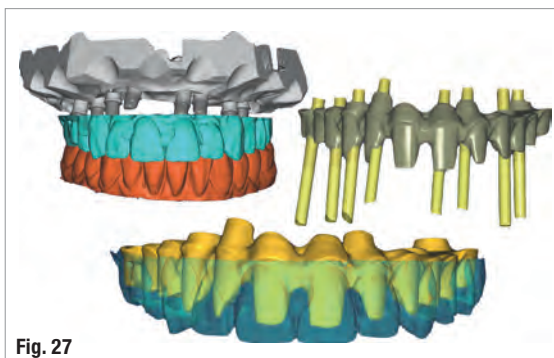


Fig. 27

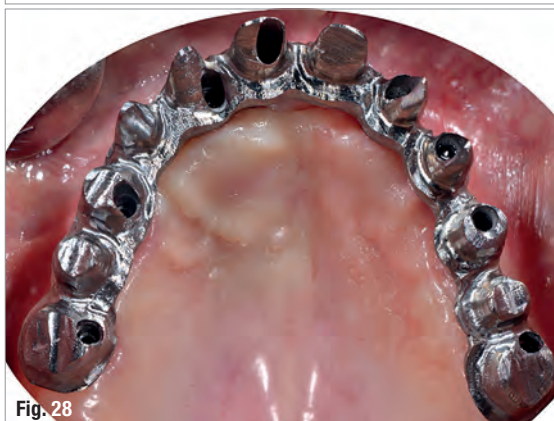


Fig. 28



Fig. 29

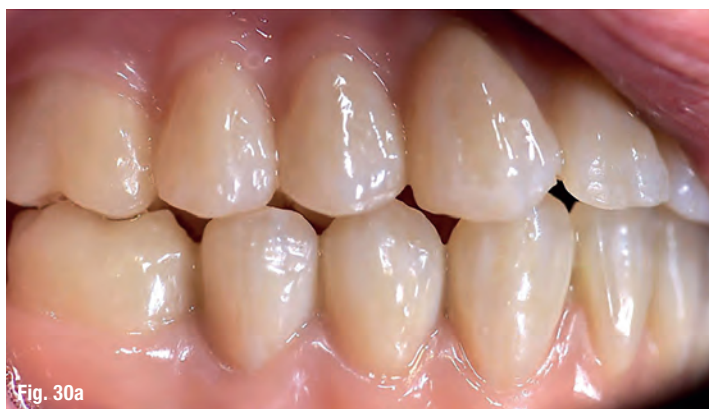

Fig. 30a

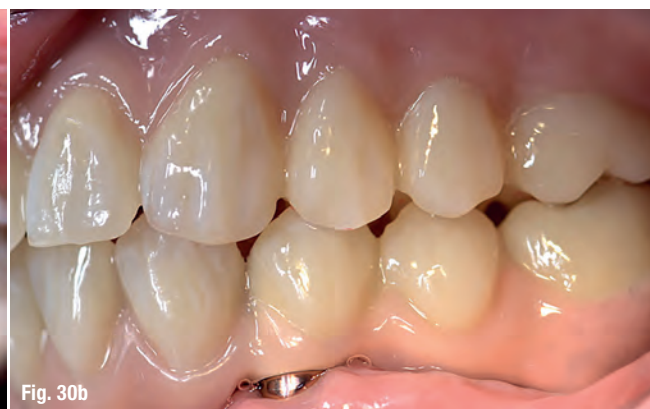

Fig. 30b

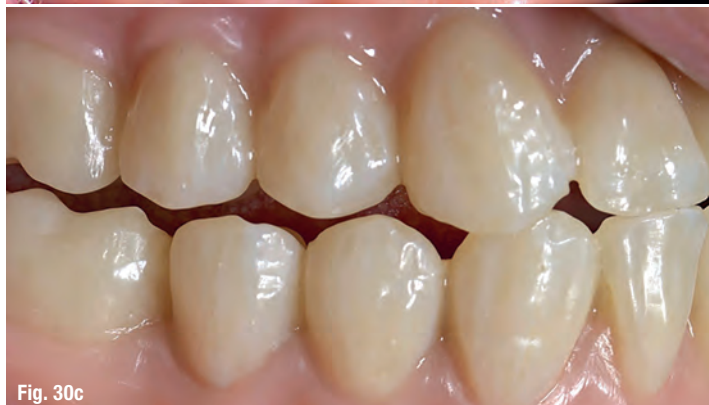

Fig. 30c

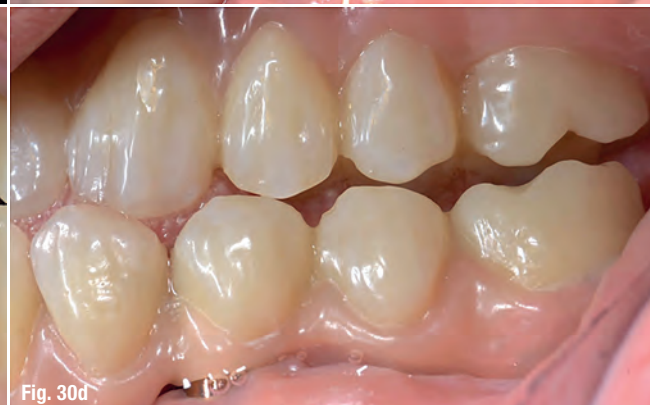

Fig. 30d

Copying back the wax-up by scanning to the CAD software (Fig. 20), the virtual prostheses were checked again regarding thickness, the surface and shape of the connections, and the adjustment of the offsets for the fit on the abutments. The file was then imported into the CAM machine (CAM 5-S1, VHF) in order to mill an interim complete denture for the maxillary arch and to mill a screw-retained full-arch prosthesis with a milled titanium mesostructure for the lower jaw (Fig. 21). Both were milled in PMMA with high-stability ceramic micro-fillers (breCAM.multiCOM, brendent).

After some months, another four implants were placed in the maxilla using the same laser-sintered surgical guide (Fig. 22), and after a further six months, the maxillary arch was ready for loading. All the mandibular procedures were repeated for the maxillary arch (Figs. 23 & 24), refining the aesthetic digital smile design and checking occlusal accuracy. Subsequently, we did another condylographic analysis of the CAD's virtual articulator settings (Fig. 25), as after the many months that had passed, the oral function had changed, and a sequential waxing for the maxillary arch was also made (Fig. 26).

A full-arch screw-retained prosthesis with a titanium mesostructure (Figs. 27 & 28) was placed in the maxillary arch. During the follow-up period, the patient reported great satisfaction with both aesthetics (Fig. 29) and function (Figs. 30a–d).

Discussion and conclusion

The use of digital tools described in this article for surgical planning, aesthetic digital smile design and the planning of a canine-dominant occlusal sequential function proved to be convenient for the clinician and the patient, allowing a reduction in working time and a simplification of the procedures involved, as well as significantly facilitating greater customisation. The CAD prostheses can be milled in different materials, with high precision and repeatability in mock-ups and try-ins at lowered costs.

Furthermore, the opportunity to scan the casts, the wax-ups, the mock-ups and the interim prostheses allows for the acquisition of a large amount of valuable information regarding the patient's anatomy, aesthetic considerations and tooth function data.

Editorial note: A list of references is available from the publisher.

about



Dr Antonio Lipari obtained his DDS from the University of Bologna and MSc in Digital Dentistry from the University of Insubria in Varese in Italy. He is in private practice in Bologna in Italy and lectures internationally on digital dentistry.



Dr Mario Perotti obtained his MD and DDS from the University of Turin in Italy and MSc in Digital Dentistry from the University of Insubria. He is in private practice in Turin in Italy and is a member of the research centre for innovative technology and engineered biomaterials at the University of Insubria. He lectures internationally on digital dentistry and is an active member of the Digital Dentistry Society.



Marco Marzolla is a master dental technician who specialises in CAD/CAM. He lectures digital dentistry at the University of Insubria.



Dr Valerio Bini obtained his DDS from the University of Genova and is also qualified as a master dental technician. He is in private practice in Cavaglià and Biella, where he offers aesthetic digital smile design. He also is a member of the research centre for innovative technology and engineered biomaterials at the University of Insubria. Bini is an active member of the Digital Dentistry Society and of the Italian Academy of Esthetic Dentistry. He lectures internationally on digital dentistry and aesthetic dentistry and has authored a number of research articles on these topics in international journals.

contact

Dr Mario Perotti
drperotti@drperotti.it